

# SPURGEON'S COLOR ATLAS OF


## Large Animal Anatomy

### *The Essentials*

Thomas O. McCracken

Robert A. Kainer

Thomas L. Spurgeon



Blackwell  
Publishing





Spurgeon's Color Atlas of  
Large Animal Anatomy:  
*The Essentials*





# Spurgeon's Color Atlas of Large Animal Anatomy: *The Essentials*

**Thomas O. McCracken, MS**

*Former Associate Professor of Anatomy  
College of Veterinary Medicine and Biomedical Sciences  
Colorado State University  
Vice President for Product and Development  
Visible Productions LLC  
Fort Collins, Colorado*

**Robert A. Kainer, DVM, MS**

*Professor Emeritus of Anatomy  
College of Veterinary Medicine and Biomedical Sciences  
Colorado State University  
Fort Collins, Colorado*

**Thomas L. Spurgeon, PhD**

*Late Associate Professor of Anatomy  
College of Veterinary Medicine and Biomedical Sciences  
Colorado State University  
Fort Collins, Colorado*

 **Blackwell**  
Publishing

© 1999 Lippincott Williams & Wilkins  
© 2006 Blackwell Publishing  
All rights reserved

Blackwell Publishing Professional  
2121 State Avenue, Ames, Iowa 50014, USA

Orders: 1-800-862-6657  
Office: 1-515-292-0140  
Fax: 1-515-292-3348  
Web site: [www.blackwellprofessional.com](http://www.blackwellprofessional.com)

Blackwell Publishing Ltd  
9600 Garsington Road, Oxford OX4 2DQ, UK  
Tel.: +44 (0)1865 776868

Blackwell Publishing Asia  
550 Swanston Street, Carlton, Victoria 3053, Australia  
Tel.: +61 (0)3 8359 1011

Authorization to photocopy items for internal or personal use, or the internal or personal use of specific clients, is granted by Blackwell Publishing, provided that the base fee is paid directly to the Copyright Clearance Center, 222 Rosewood Drive, Danvers, MA 01923. For those organizations that have been granted a photocopy license by CCC, a separate system of payments has been arranged. The fee codes for users of the Transactional Reporting Service are ISBN-13: 978-0-6833-0673-6/2006.

First edition

Library of Congress Cataloging-in-Publication Data  
McCracken, Thomas O.

Spurgeon's color atlas of large animal anatomy : the essentials /

Thomas O. McCracken, Robert A. Kainer, Thomas L. Spurgeon

p. cm.

ISBN 978-0-6833-0673-6

I. Veterinary anatomy Atlases. I. Kainer, Robert A. II. Title.

SF7613M35 1999

636.089'1—dc21

99-20525

CIP

Printed and bound in Malaysia by Vivar Printing Sdn Bhd

8 2011





*Thomas Spurgeon*

#### TO OUR COLLEAGUE AND FRIEND

*Dr. Thomas L. Spurgeon, exceptionally well-trained anatomist, superb teacher, and educational innovator, devoted his professional life to the advancement of anatomic education through scientific investigation and the dissemination of anatomic knowledge.*

*Following service to his country in the United States Air Force, Thomas L. Spurgeon entered college. Upon completion of his doctorate in anatomy in the School of Veterinary Medicine at the University of California-Davis, Dr. Spurgeon accepted a faculty position in the College of Veterinary Medicine at Washington State University. His record as an excellent anatomist at that institution led to a position in the College of Veterinary Medicine and Biomedical Sciences at Colorado State University.*

*His broad knowledge of both human and veterinary anatomy was utilized fully at Colorado State. Students requiring courses in basic human anatomy as well as those majoring in veterinary medicine and various animal sciences profited from the instruction provided by this well-rounded anatomist who possessed outstanding pedagogic skill. His expertise was equally appreciated by the graduate students he mentored, particularly those in the biomedical illustration program.*

*Dr. Spurgeon, a pioneer in the computer-assisted instruction of anatomy, was continually seeking new methods of presentation. He and his colleague and close friend, Thomas O. McCracken, conceived the unique anatomic presentation used in this atlas.*

*Tragically, Dr. Spurgeon's untimely death in an automobile accident in 1997 brought a halt to his brilliant career. Dr. Spurgeon's devoted sons, Aaron and Kyle, are indeed proud of their father's accomplishments. Countless students mourn the passing of a man who, as teacher and friend, contributed so much to their lives.*

# ACKNOWLEDGMENTS

**M**any talented individuals contributed to the production of *Spurgeon's Color Atlas of Large Animal Anatomy: The Essentials*. Foremost among them were the artists, Conery Calhoon, Molly Babich, Gale Mueller, and Sandra Mullins, who colored Thomas McCracken's original drawings of anatomic specimens. They employed manual and digital techniques to reproduce the subtle colors of tissues and organs.

Consultants, who authored plates drawn by Thomas McCracken, selected clinical conditions and husbandry applications based on their anatomic significance. The consultants were Dr. Gayle Trotter for the horse; Dr. Frank Garry for the ox; Dr. Joan Bowen for the sheep and goat; Dr. LaRue Johnson for the llama and alpaca and the swine; and Dr. John Avens for the chicken. These specialists reviewed the plates on the various species, enhancing the accuracy of the presentations. Their contributions are gratefully acknowledged.

Carroll Cann, Executive Editor of Teton-New Media, was an enthusiastic supporter of the concept of the atlas. We thank him for his suggestions and encouragement.

Special thanks are due the late Dr. Patricia Brooks who supported her husband, Dr. Spurgeon, and frequently assisted him in his work. She, too, was a contributor to this atlas.

We greatly appreciated the reliable assistance of Dennis Madden, pathology technician in the College of Veterinary Medicine and Biomedical Sciences at Colorado State University. His procurement of specimens and his dissection skills were essential to the production of this atlas.

We thank Mark Goldstein for a student's viewpoint. His assistance with compilation of the index and his review and comments on the plates were most helpful.

We are grateful to Dr. Michael Smith from the School of Veterinary Medicine at Ross University for his careful review of the final proofs. His knowledge of anatomy, his fine teaching skills, and his critical eye well qualified him for this arduous task.

Acknowledgment is due the Department of Anatomy and Neurobiology and the Department of Clinical Sciences at Colorado State University for the use of their facilities and for providing living animals, skeletons, embalmed specimens, and necropsy specimens. Dr. Robert Lee prepared and was most helpful in providing anatomic specimens. We acknowledge the kindness of exhibitors at the National Western Stock Show and Midnight Valley Friesens for permission to photograph their animals.

We thank Alpine Publications, Inc. of Loveland, Colorado, for permission to use drawings from our book, *Horse Anatomy, A Coloring Atlas*. Permission from Pfizer Animal Health Group to use drawings of the chicken's anatomy from *Anatomical Atlas* is also appreciated.



# CONTENTS

Introduction .....	xii
Nomenclature and Anatomic Orientation .....	xiii
Animal Classification .....	xiii
General Terminology, Positional and Directional Terms .....	xiv
Body Planes .....	xvi
Body Cavities and Membranes .....	xviii

## **SECTION 1**    **THE HORSE** (*Equus caballus*)

Plate 1.1	Right lateral view of a stallion. ....	2
Plate 1.2	Left lateral view of a mare. ....	3
Plate 1.3	Body regions of the horse. ....	4
Plate 1.4	Skeleton of the horse. ....	5
Plate 1.5	Cutaneous muscles and major fasciae of the stallion. ....	6
Plate 1.6	Superficial muscles and veins of the mare. ....	7
Plate 1.7	A. Parasagittal section of the equine digit. ....	8
	B. Palmar (plantar) view of major structures of the equine digit. ....	8
Plate 1.8	Relations of the hoof. ....	9
Plate 1.9	Stay apparatus of the equine forelimb. ....	10
Plate 1.10	Stay apparatus and reciprocal apparatus of the hindlimb. ....	11
Plate 1.11	Deep muscles and <i>in situ</i> viscera of the stallion. ....	12
Plate 1.12	Deep cervical muscles, major joints, and <i>in situ</i> viscera of the mare. ....	13
Plate 1.13	Median section of the horse's head. ....	14
Plate 1.14	A. Occlusal (grinding) surfaces of an equine lower first incisor tooth related to continuous eruption and wear. ....	15
	B. Complete dentition of the male horse circa 5 years of age. ....	15
Plate 1.15	Isolated stomach and intestines of the horse. ....	16
Plate 1.16	Equine cecum, large (ascending) colon, and transverse colon <i>in situ</i> . ....	17
Plate 1.17	Clinical condition: Right dorsal displacement of the large colon. ....	18
Plate 1.18	Clinical condition: Left dorsal displacement of the large colon. ....	19



Plate 1.19	Reproductive organs, urinary organs, liver, heart, and adjacent major vessels related to the skeleton of the stallion. . . . .	20
Plate 1.20	Heart and some adjacent major vessels, abdominal and pelvic viscera, and udder (mammary glands) of the mare. . . . .	21
Plate 1.21	Relations of the reproductive organs of the stallion. . . . .	22
Plate 1.22	Relations of the reproductive organs of the mare. . . . .	23
Plate 1.23	Neonatal organs of the foal. . . . .	24
Plate 1.24	Major arteries of the mare. . . . .	25
Plate 1.25	Major veins of the stallion. Portal system excluded. . . . .	26
Plate 1.26	Lymph nodes and vessels of the horse. . . . .	27
Plate 1.27	Central and somatic nervous system of the stallion. . . . .	28
Plate 1.28	Autonomic nervous system of the mare. . . . .	29

## **SECTION 2** THE OX (*Bos taurus*, also *Bos indicus*)

Plate 2.1	Right lateral view of a beef bull. . . . .	32
Plate 2.2	Left lateral view of a dairy cow. . . . .	33
Plate 2.3	Body regions of the ox. . . . .	34
Plate 2.4	Skeleton of the ox. . . . .	35
Plate 2.5	Cutaneous muscles and major fasciae of the bull. . . . .	36
Plate 2.6	Superficial muscles and veins of the cow. . . . .	37
Plate 2.7	Deep cervical muscles and <i>in situ</i> viscera of the bull. . . . .	38
Plate 2.8	Deep cervical muscles, major joints, <i>in situ</i> viscera, and udder of the cow. . . . .	39
Plate 2.9	Median section of the head and left lateral view of the respiratory system of the ox. . . . .	40
Plate 2.10	Interior of the rumen and reticulum of the cow. . . . .	41
Plate 2.11	Clinical condition: Right volvulus of the abomasum in a bull. . . . .	42
Plate 2.12	Clinical condition: Left displacement of the abomasum in a cow. . . . .	43
Plate 2.13	Reproductive organs, urinary organs, liver, heart, and adjacent major vessels related to the skeleton of the bull. . . . .	44
Plate 2.14	Heart and adjacent major vessels, abdominal and pelvic viscera, and udder (mammary glands) of the cow. . . . .	45
Plate 2.15	Relations of the reproductive organs of the bull. . . . .	46
Plate 2.16	Relations of the reproductive organs of the cow. . . . .	47
Plate 2.17	Major veins of the bull. . . . .	48
Plate 2.18	Major arteries of the cow. . . . .	49

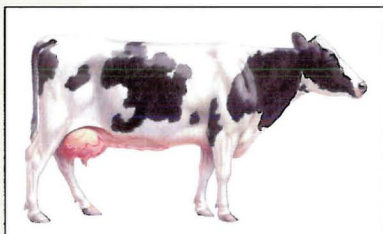




Plate 2.19	Central nervous system and principal nerves of the peripheral nervous system of the bull. . . . .	50
Plate 2.20	Significant lymphatic organs of the cow. . . . .	51

### SECTION 3 THE SHEEP (*Ovis aries*)




Plate 3.1	Right lateral view of a ram. . . . .	54
Plate 3.2	Left lateral view of an ewe. . . . .	55
Plate 3.3	Carcass cuts of the lamb. . . . .	56
Plate 3.4	Skeleton of the sheep. . . . .	57
Plate 3.5	Cutaneous muscles and major fasciae of the ram. . . . .	58
Plate 3.6	Superficial muscles and veins of the ewe. . . . .	59
Plate 3.7	Deep cervical muscles and <i>in situ</i> viscera of the ram. . . . .	60
Plate 3.8	Deep cervical muscles, <i>in situ</i> viscera, skeleton, and major joints of the ewe. . .	61
Plate 3.9	Dissection of the parotid region and cross-section of the neck of the sheep. . .	62
Plate 3.10	A. Location of the left flank incision . . . . .	63
	B. Cross-section through the left abdominal wall and subjacent ruminal wall. .	63
Plate 3.11	Reproductive organs, urinary organs, esophagus and stomach, heart, and adjacent major vessels related to the skeleton of the ram. . . . .	64
Plate 3.12	Reproductive organs, urinary organs, heart, and adjacent major vessels, esophagus and stomach of the ewe. . . . .	65
Plate 3.13	Relations of the reproductive organs of the ram. . . . .	66
Plate 3.14	Relations of the reproductive organs of the ewe. . . . .	67
Plate 3.15	Penis of the ram. . . . .	68
Plate 3.16	Isolated reproductive organs of the ewe. . . . .	69

### SECTION 4 THE GOAT (*Capra hircus*)




Plate 4.1	Right lateral view of an Angora buck (billy). . . . .	72
Plate 4.2	Left lateral view of a Toggenberg doe (nanny). . . . .	73
Plate 4.3	Body regions of the goat. . . . .	74
Plate 4.4	Skeleton of the goat. . . . .	75
Plate 4.5	Cutaneous muscles and major fasciae of the buck. . . . .	76
Plate 4.6	Superficial muscles and veins of the doe. . . . .	77
Plate 4.7	Major structures of the caprine left distal metacarpus and digits. . . . .	78
Plate 4.8	A. Untrimmed hoofs of the goat. . . . .	79
	B. Trimmed hoofs of the goat. . . . .	79
	C. Parasagittal section through the fetlock and digit. . . . .	79

Plate 4.9	Deep muscles and <i>in situ</i> viscera of the buck. . . . .	80
Plate 4.10	Deep cervical muscles, <i>in situ</i> viscera, skeleton, and major joints of the doe. . .	81
Plate 4.11	Superficial structures of the goat's head. . . . .	82
Plate 4.12	Median section of the caprine head. . . . .	83
Plate 4.13	Reproductive organs, abdominal viscera, heart, and adjacent major vessels related to the skeleton of the buck. . . . .	84
Plate 4.14	Reproductive organs, abdominal viscera, heart, and adjacent major vessels of the doe. . . . .	85
Plate 4.15	Relations of the reproductive organs of the buck. . . . .	86
Plate 4.16	Relations of the reproductive organs of the doe. . . . .	87

## **SECTION 5 THE LLAMA AND ALPACA (*Lama glama* and *Lama pacos*)**




Plate 5.1	Right lateral view of a male llama. . . . .	90
Plate 5.2	Left lateral view of a female huacaya alpaca. . . . .	91
Plate 5.3	Body regions of the llama. . . . .	92
Plate 5.4	Skeleton of the llama. . . . .	93
Plate 5.5	Cutaneous muscles and major fasciae of the male llama. . . . .	94
Plate 5.6	Superficial muscles of the female alpaca. . . . .	95
Plate 5.7	Deep muscles and <i>in situ</i> viscera of the male llama. . . . .	96
Plate 5.8	Deep cervical muscles, <i>in situ</i> viscera, and major joints of the female alpaca. . .	97
Plate 5.9	Major structures of the lamoid left distal metacarpus and digits. . . . .	98
Plate 5.10	Median section of the llama's head. . . . .	99
Plate 5.11	Proper and improper placement of a halter on a llama's head. . . . .	100
Plate 5.12	Relations of the llama's common carotid artery and jugular vein. . . . .	101
Plate 5.13	Dentition of the male llama. . . . .	102
Plate 5.14	Isolated stomach and intestines of the male llama. . . . .	103
Plate 5.15	Reproductive and urinary organs, stomach, liver, heart, and adjacent major vessels related to the skeleton of the male llama. . . . .	104
Plate 5.16	Reproductive and urinary organs, stomach, heart, and adjacent major vessels of the female alpaca. . . . .	105
Plate 5.17	Relations of the reproductive organs of the male llama. . . . .	106
Plate 5.18	Relations of the reproductive organs of the female alpaca. . . . .	107

## **SECTION 6 THE SWINE (*Sus scrofa domesticus*)**

Plate 6.1	Right lateral view of a boar. . . . .	110
Plate 6.2	Left lateral view of a sow. . . . .	111






Plate 6.3	Carcass cuts of the hog. . . . .	112
Plate 6.4	Skeleton of the swine. . . . .	113
Plate 6.5	Cutaneous and superficial muscles of the boar. . . . .	114
Plate 6.6	Superficial muscles of the sow. . . . .	115
Plate 6.7	Deep muscles and <i>in situ</i> viscera of the boar. . . . .	116
Plate 6.8	Deep cervical muscles, major joints, and <i>in situ</i> viscera of the sow. . . . .	117
Plate 6.9	Median section of the porcine head. . . . .	118
Plate 6.10	A. Permanent dentition of the boar. . . . .	119
	B. Cutting the deciduous incisor and canine teeth of a piglet. . . . .	119
Plate 6.11	Isolated stomach and intestines of the swine. . . . .	120
Plate 6.12	Lymph nodes and vessels of the sow. . . . .	121
Plate 6.13	Reproductive and urinary organs, stomach, liver, heart, and adjacent major vessels related to the skeleton of the boar. . . . .	122
Plate 6.14	Reproductive and urinary organs, abdominal viscera, spleen, heart, and adjacent major vessels of the sow. . . . .	123
Plate 6.15	Relations of the reproductive organs of the boar. . . . .	124
Plate 6.16	Relations of the reproductive organs of the sow. . . . .	125

## **SECTION 7 THE CHICKEN (*Gallus gallus domesticus*)**



Plate 7.1	Right lateral view of a rooster (cock). . . . .	128
Plate 7.2	Left lateral view of a hen. . . . .	129
Plate 7.3	Feather coat of the rooster. . . . .	130
Plate 7.4	Skeleton of the chicken. . . . .	131
Plate 7.5	Superficial muscles of the rooster. . . . .	132
Plate 7.6	Superficial muscles of the hen. . . . .	133
Plate 7.7	Relations of <i>in situ</i> viscera to the skeleton and cervical muscles of the rooster. . . . .	134
Plate 7.8	Relations of <i>in situ</i> viscera and blood vessels to the skeleton and cervical muscles of the hen. . . . .	135
Plate 7.9	Isolated gastrointestinal tract of the chicken. . . . .	136
Plate 7.10	Air sacs and lungs of the chicken. . . . .	137
Plate 7.11	<i>In situ</i> viscera, major blood vessels, and axial skeleton of the rooster. . . . .	138
Plate 7.12	<i>In situ</i> viscera, major blood vessels, and axial skeleton of the hen. . . . .	139
Plate 7.13	Reproductive organs of the rooster. . . . .	140
Plate 7.14	Reproductive organs of the hen. . . . .	141



# INTRODUCTION

**S**urgeon's *Color Atlas of Large Animal Anatomy: The Essentials* is not a complete, detailed anatomic atlas. Instead, it presents topographic relationships of the major organs of the horse, ox, sheep, goat, llama, alpaca (a smaller species with long, lustrous hair), swine, and chicken in a simple yet technically accurate format. As an important food animal, the chicken is included with the large domestic animals in this atlas. Throughout the *Atlas*, most male and female of a given species are on facing pages. The majority of the plates contain information on the entire body. Some plates are confined to a region; a few contain organs isolated from the rest of the body. Whereas most systems (e.g., digestive and reproductive) are presented for each animal, other systems are included only for some species to illustrate general anatomic patterns. Structures common to the various animals are labeled several times; other structures are labeled on only one or two species, usually emphasizing specific anatomy (the anatomy peculiar to a certain species). Animal specialists authored plates illustrating selected clinical or husbandry applications that reflect the anatomy of the organs involved.

The *Atlas* is intended for use by individuals at different stages of their education, serving as a survey of the specific anatomy of the different animals. Advanced 4-H club members, high school vocational agriculture students, and college students studying veterinary medical technology, veterinary medicine, animal science, and wildlife biology can use this *Atlas* as an introduction to the anatomy of common farm animals. The *Atlas* can also serve as a reference for horse breeders and trainers, as well as livestock and poultry producers. It will provide a quick review for persons with previous training in anatomy and will be an invaluable aid for the professional—e.g., a veterinarian or animal scientist—in explaining to a client some aspect of anatomy that pertains to an animal's condition and needs.

The following introductory pages provide the reader with a background in nomenclature and anatomic orientation.

# NOMENCLATURE AND ANATOMIC ORIENTATION

## ANIMAL CLASSIFICATION

The horse (*Equus caballus*) is classified as an odd-toed ungulate (hoofed mammal) in the order Perissodactyla, suborder Hippomorpha, and family Equidae. Members of this family are termed equids. “Equine” is an adjective. Equine characteristics include the grouping of limb muscles close to the trunk with tendons extending over long third metacarpal and metatarsal bones to the digits, providing leverage for sustained, rapid locomotion. Because this leverage arrangement does not develop great force, the heavy draft horse must rely on body weight to perform pulling tasks. Another equine characteristic is the horse’s extensive large intestine, the site of final microbial digestion and absorption of nutrients.

Cloven-hoofed ungulates that walk on their third and fourth digits are in the order Artiodactyla. Domestic ungulates in the suborder Ruminantia include those in the family Bovidae, subfamily Bovinae—the ox (*Bos taurus*) and zebu (*Bos indicus*)—and subfamily caprinae, the sheep (*Ovis aries*) and goat (*Capra hircus*). The noun “bovids” (after Bovidae) is usually reserved for cattle, bison, yak, and water buffalo; sheep are ovids and goats are caprids, named according to each genus. Adjectives end in -ine: bovine, ovine, and caprine, respectively.

The llama (*Lama glama*) and alpaca (*Lama pacos*) are cud-chewing artiodactyls from South America called camelids, named after the family Camelidae in the suborder Tylopoda. South American camelids are also called lamoids. Both ruminants and camelids have large, compartmented stomachs essential for the microbial digestion of cellulose. Feed is more finely divided by rumination, a physiologic sequence of regurgitation of stomach contents, remastication (chewing), and redeglutition (swallowing).

Swine (pigs are young; hogs are mature) are artiodactyls in the suborder Suiformes, family Suidae. Domestic swine (*Sus scrofa domesticus*) are descended from the European wild boar with some input from the smaller *Sus indica* from China. The adjective “porcine” is derived from the Latin *porcinus*, from *porcus*, a hog. Reflecting its omnivorous diet, the swine’s digestive tract is somewhat simpler than those of ruminating animals.

The chicken or domestic fowl (*Gallus gallus domesticus*) is classified with other comb-bearing gallinaceous birds in the order Galliformes. Descended from the Red Junglefowl of southeast Asia, the chicken is in the family Phasianidae.



## GENERAL TERMINOLOGY

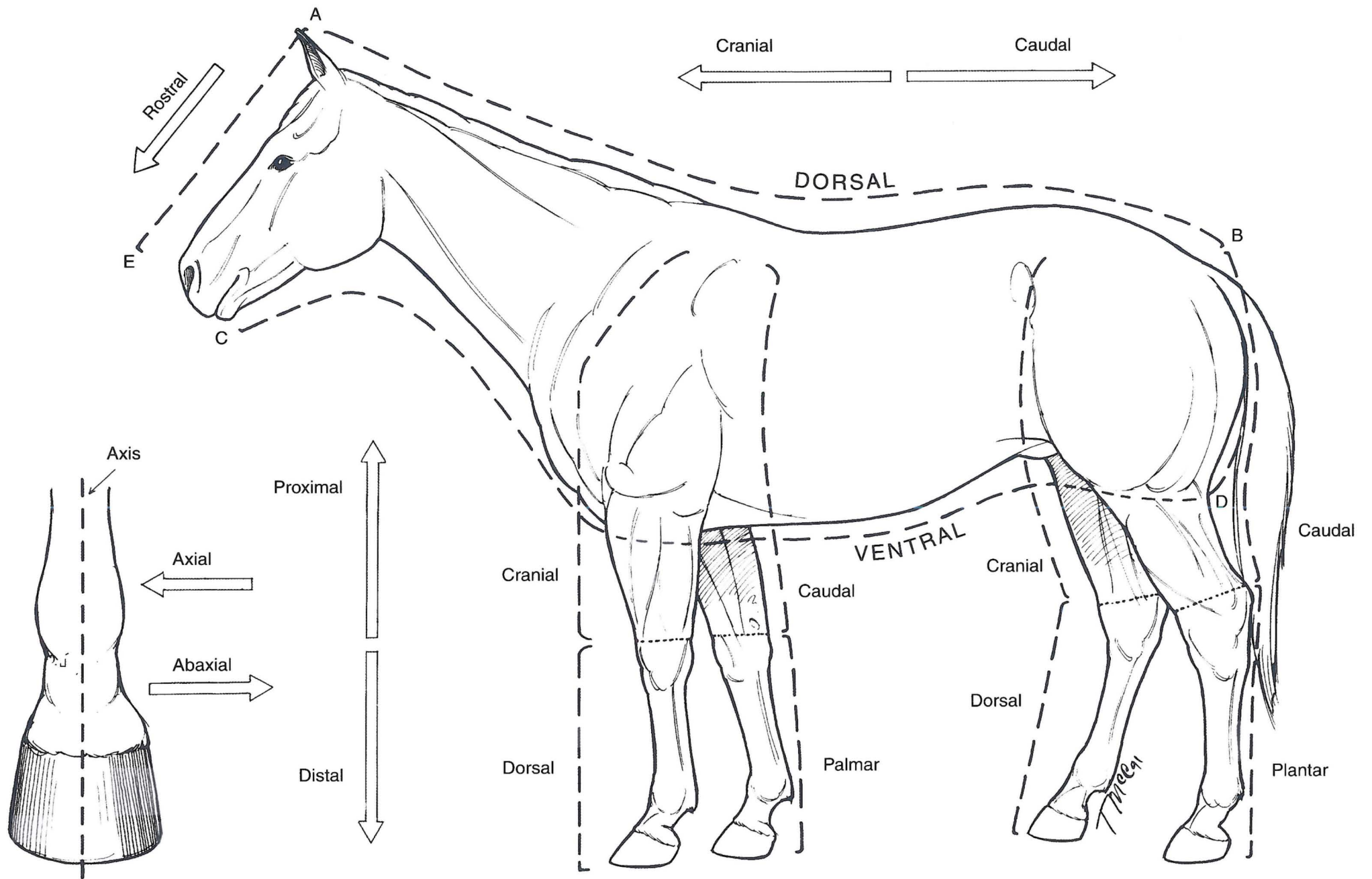
With some exceptions, particularly for most muscles wherein traditional Latin names are used, the terminology in this *Atlas* conforms to English translations of Latin terms in the *Nomina Anatomica Veterinaria (N.A.V.)*, 3rd ed., 1983. There are some departures from N.A.V., however. For example, according to N.A.V., the hoof includes the underlying corium (dermis) with the horny epidermis, whereas in common usage hoof refers only to the horny epidermal structure. In compliance with the intent of N.A.V., nomenclature will be consistent for all species. Common terms and meat-packing terms are used on some plates. Abbreviations for organs in this *Atlas* include: a, artery; b, bone; j, joint; lig., ligament; ln, lymph node; m, muscle; n, nerve; v, vein. Double letters indicate the plural form of these words (e.g., aa, arteries). Positional and directional terms, body planes, and the extent of body cavities are used to indicate the location of parts of the body and functional changes in position. The extent of diseased regions is defined using this anatomic terminology.

## POSITIONAL AND DIRECTIONAL TERMS

The following terms are illustrated on the accompanying drawing of a horse. **Dorsal** and **ventral** are opposite terms indicating relative locations toward the back (L., dorsum) or belly (L., venter). Above the knee (carpus) and hock (tarsus) and from the belly to the back, a structure located closer to the cranium (skull case) is **cranial** to another structure, and a structure located toward the tail (L., cauda) is **caudal** to another. On the head, the term **rostral** indicates a structure closer to the nose (L., rostrum).

**Proximal** indicates a location toward the attached end of a limb; **distal** indicates a location toward the free end of a limb, that is, further from the trunk. Distal to and including the carpus, **dorsal** replaces cranial; **palmar** replaces caudal. Distal to and including the hock, dorsal replaces cranial, but **plantar** replaces caudal.

On a frontal view of the distal end of a limb, notice that an **axial** structure is located toward the **axis**. An **abaxial** structure is located away from it.





## **BODY PLANES**

Drawings of a horse are used to illustrate body planes. The **median plane** (L., medius, middle) divides the animal body into right and left halves. A **sagittal plane** (L., sagitta, arrow) is any plane parallel to the median plane. **Medial** and **lateral** (L., latus, side) are directional terms relative to the median plane. Medial structures are located closer to the median plane. Lateral structures lie away from the median plane, that is, toward the side. A **transverse plane** passes through the head, trunk, or limb perpendicular to the part's long axis. A **dorsal plane** (also called a **frontal plane**) is a longitudinal plane that passes through the body parallel to its dorsal surface at right angles to the median plane.

Figure 1

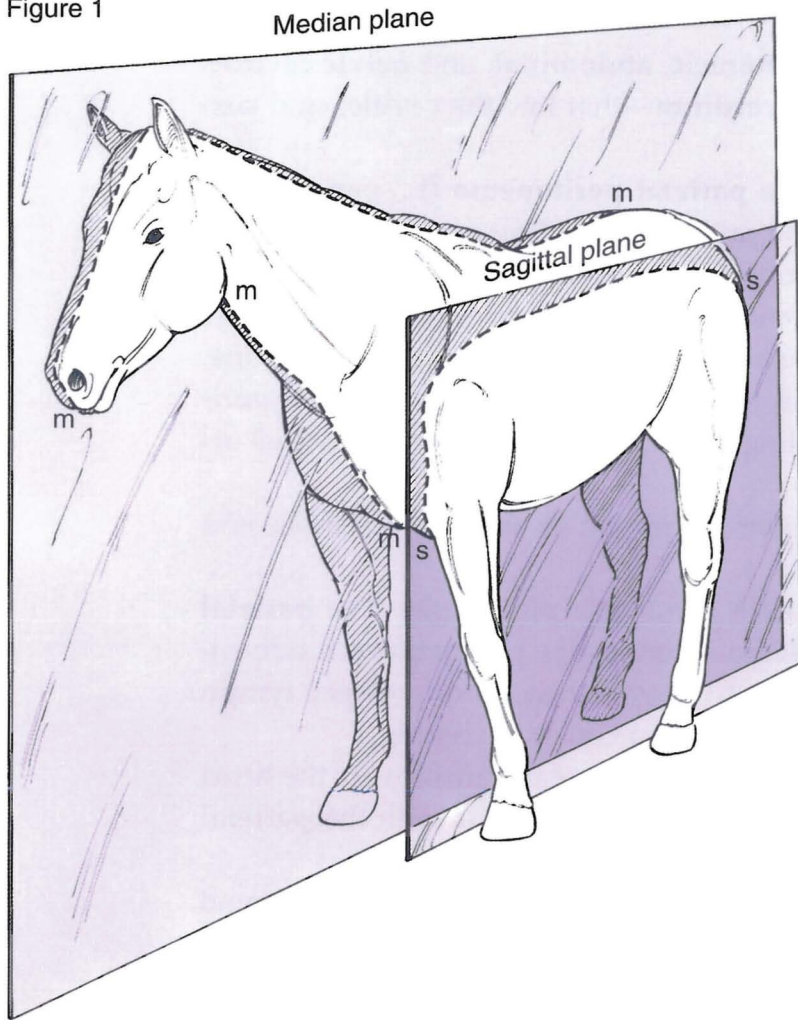


Figure 3

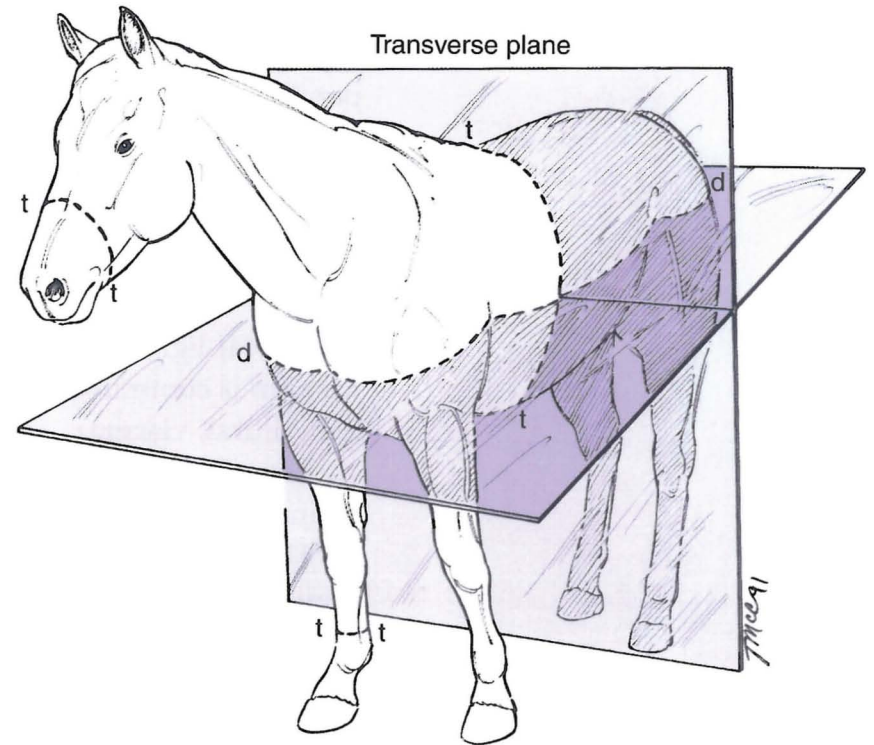
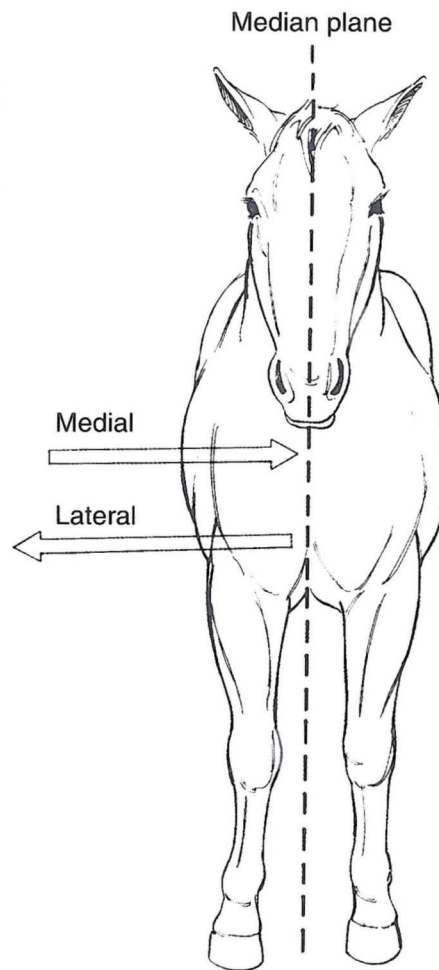


Figure 2



## BODY CAVITIES AND MEMBRANES

A diagrammatic drawing of a mare's trunk illustrates the **thoracic, abdominal, and pelvic cavities** and the serous membranes—**peritoneum, pleura, and pericardium**—that line the cavities and suspend organs.

The peritoneum consists of three continuous parts. The **parietal peritoneum** (L., *paries*, wall) lines the abdominal cavity and the cranial part of the pelvic cavity. **Connecting peritoneum** reflects from the parietal peritoneum and suspends organs in a double fold containing vessels and nerves as it extends to an organ. The connecting peritoneum is indicated by *mes-* (G., *mesos*, middle) plus the Latin or Greek name of the organ. An example is *mesentery*: *mes-* plus G., *enteron*, small intestine. Peritoneal ligaments suspend and support—e.g., the *falciform ligament* of the liver. **Visceral peritoneum** is continuous with connecting peritoneum, encircling a viscus (Latin for a large, internal organ; plural, **viscera**).

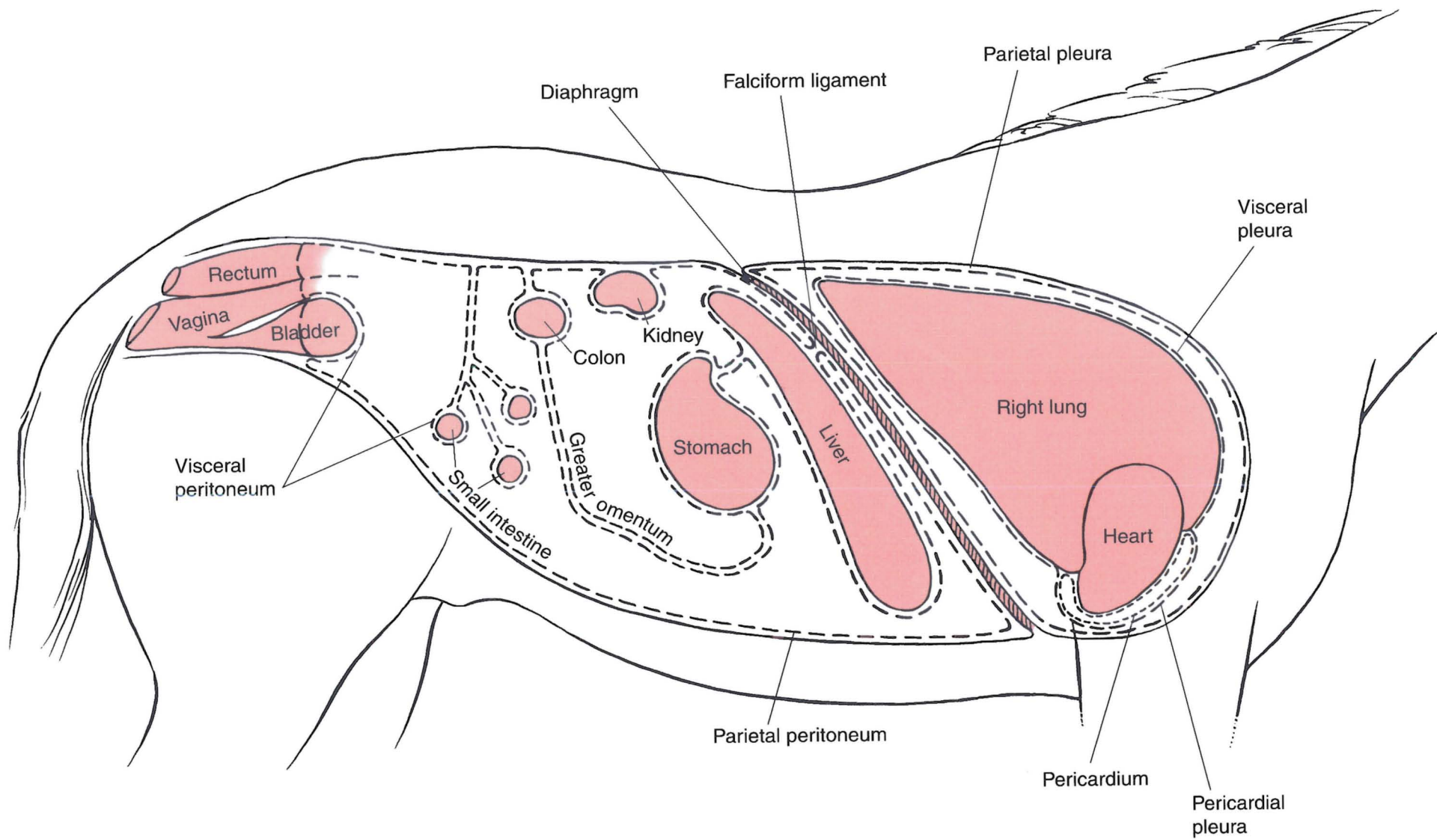
The musculomembranous **diaphragm** is covered with peritoneum on its abdominal surface and pleura on its thoracic surface.

The **pleurae** are two continuous serous membranes, each forming a pleural sac. The **parietal pleura** lines each half of the thoracic cavity. **Mediastinal pleura** is connecting pleura on each side enclosing the **mediastinum**, a space containing the heart, esophagus, trachea, blood vessels, lymph nodes and ducts, thymus, nerves, and adipose tissue. **Visceral pleura** covers each lung.

The **pericardium** is the heart sac. **Visceral pericardium** (also called *epicardium*) covers the heart and reflects around the base of the heart and great vessels to become continuous with the **parietal pericardium**.

The serous cavities—**peritoneal cavity, pleural cavity, and pericardial cavity**—are potential spaces between parietal and visceral membranes containing lubricating serous fluids named for each cavity.



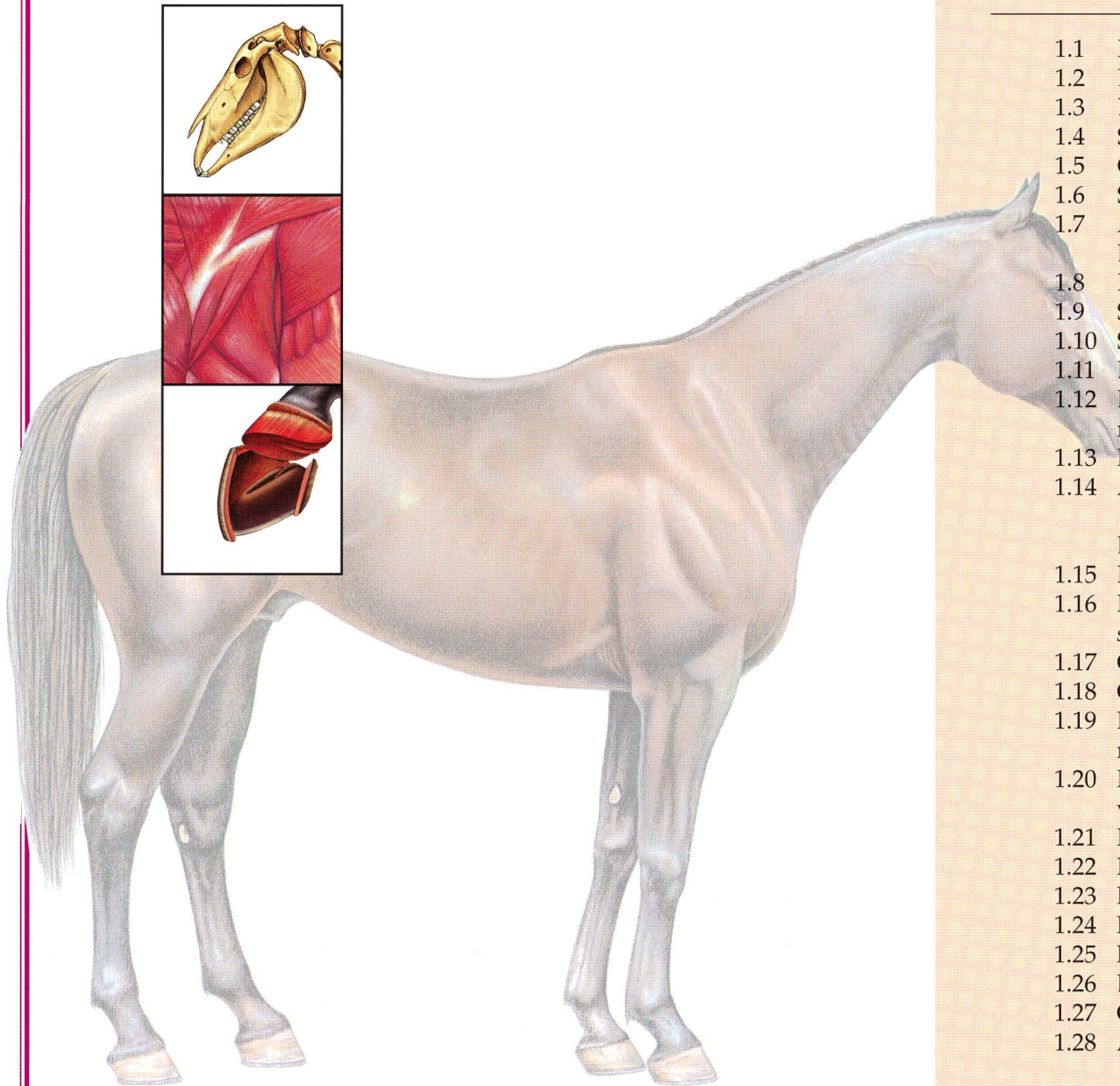






# SECTION 1 THE HORSE (*Equus caballus*)

## P L A T E S



- 1.1 Right lateral view of a stallion.
- 1.2 Left lateral view of a mare.
- 1.3 Body regions of the horse.
- 1.4 Skeleton of the horse.
- 1.5 Cutaneous muscles and major fasciae of the stallion.
- 1.6 Superficial muscles and veins of the mare.
- 1.7 A. Parasagittal section of the equine digit.  
B. Palmar (plantar) view of major structures of the digit.
- 1.8 Relations of the hoof.
- 1.9 Stay apparatus of the equine forelimb.
- 1.10 Stay apparatus and reciprocal apparatus of the hindlimb.
- 1.11 Deep muscles and *in situ* viscera of the stallion.
- 1.12 Deep cervical muscles, major joints, and *in situ* viscera of the mare.
- 1.13 Median section of the horse's head.
- 1.14 A. Occlusal (grinding) surfaces of an equine lower first incisor tooth related to continuous eruption and wear.  
B. Complete dentition of the male horse circa 5 years of age.
- 1.15 Isolated stomach and intestines of the horse.
- 1.16 Equine cecum, large (ascending) colon, and transverse colon *in situ*.
- 1.17 Clinical condition: Right dorsal displacement of the large colon.
- 1.18 Clinical condition: Left dorsal displacement of the large colon.
- 1.19 Reproductive organs, urinary organs, liver, heart, and adjacent major vessels related to the skeleton of the stallion.
- 1.20 Heart and some adjacent major vessels, abdominal and pelvic viscera, and udder (mammary glands) of the mare.
- 1.21 Relations of the reproductive organs of the stallion.
- 1.22 Relations of the reproductive organs of the mare.
- 1.23 Neonatal organs of the foal.
- 1.24 Major arteries of the mare.
- 1.25 Major veins of the stallion. Portal system excluded.
- 1.26 Lymph nodes and vessels of the horse.
- 1.27 Central and somatic nervous system of the stallion.
- 1.28 Autonomic nervous system of the mare.



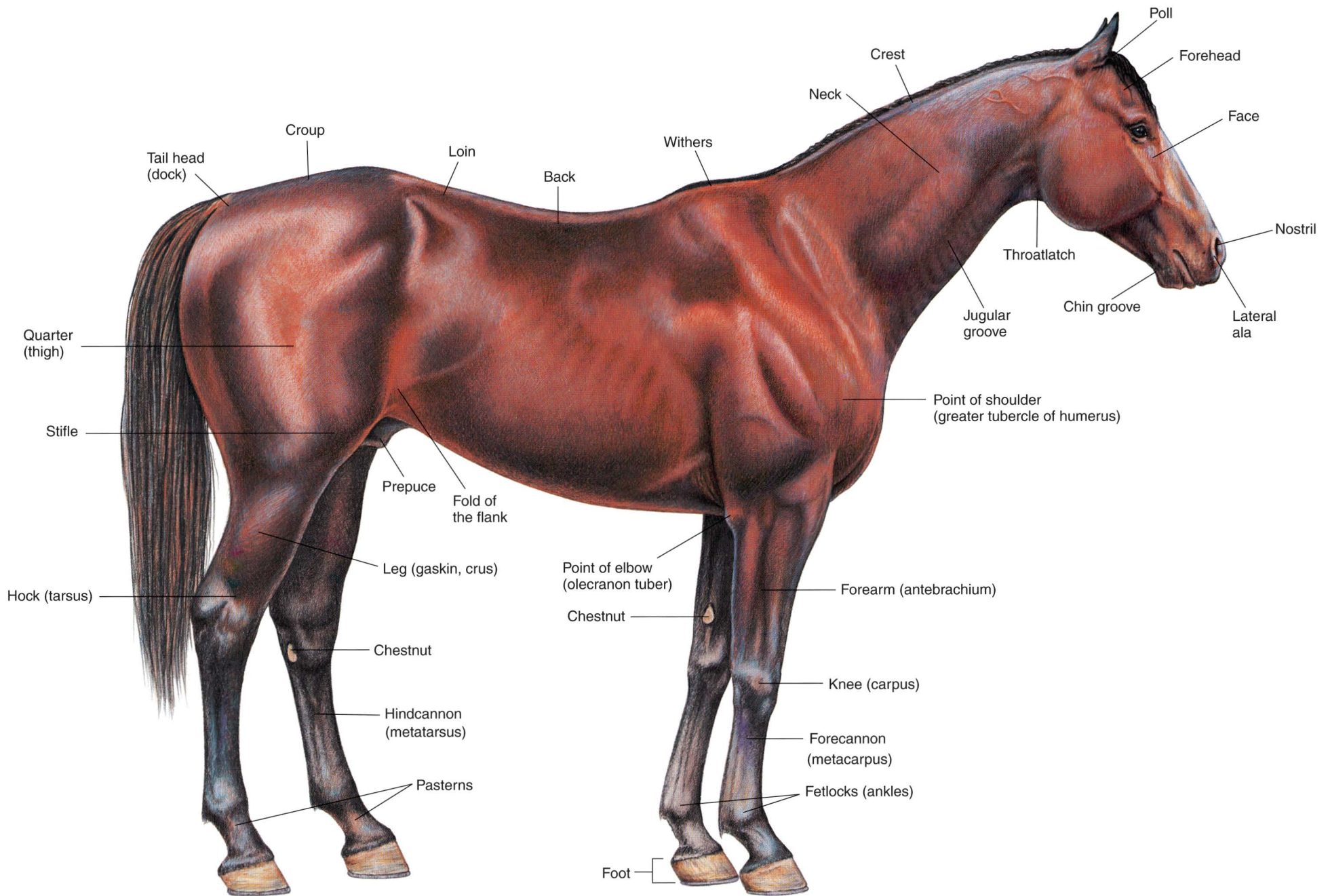


PLATE 1.1 Right lateral view of a stallion.

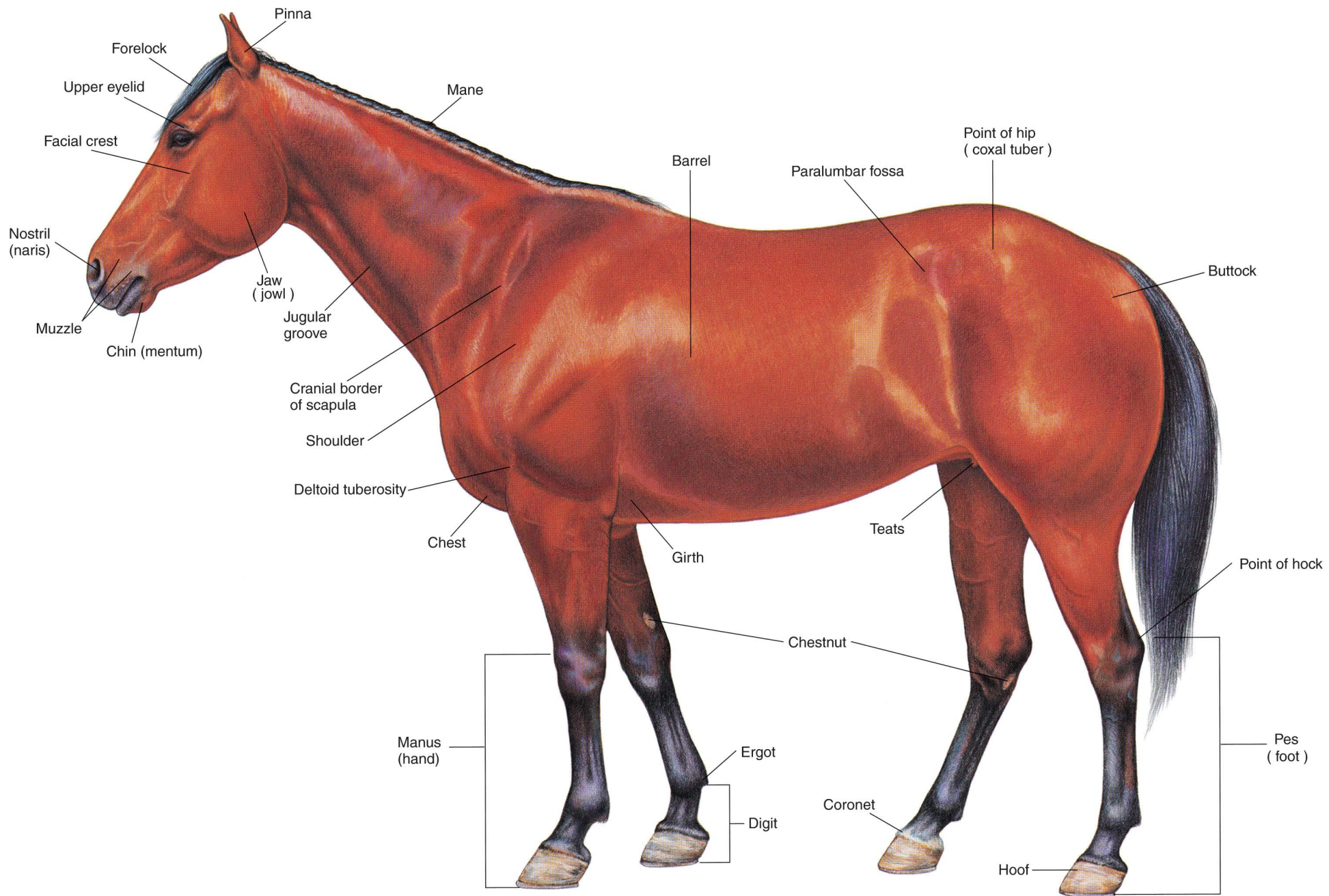


PLATE 1.2 Left lateral view of a mare.



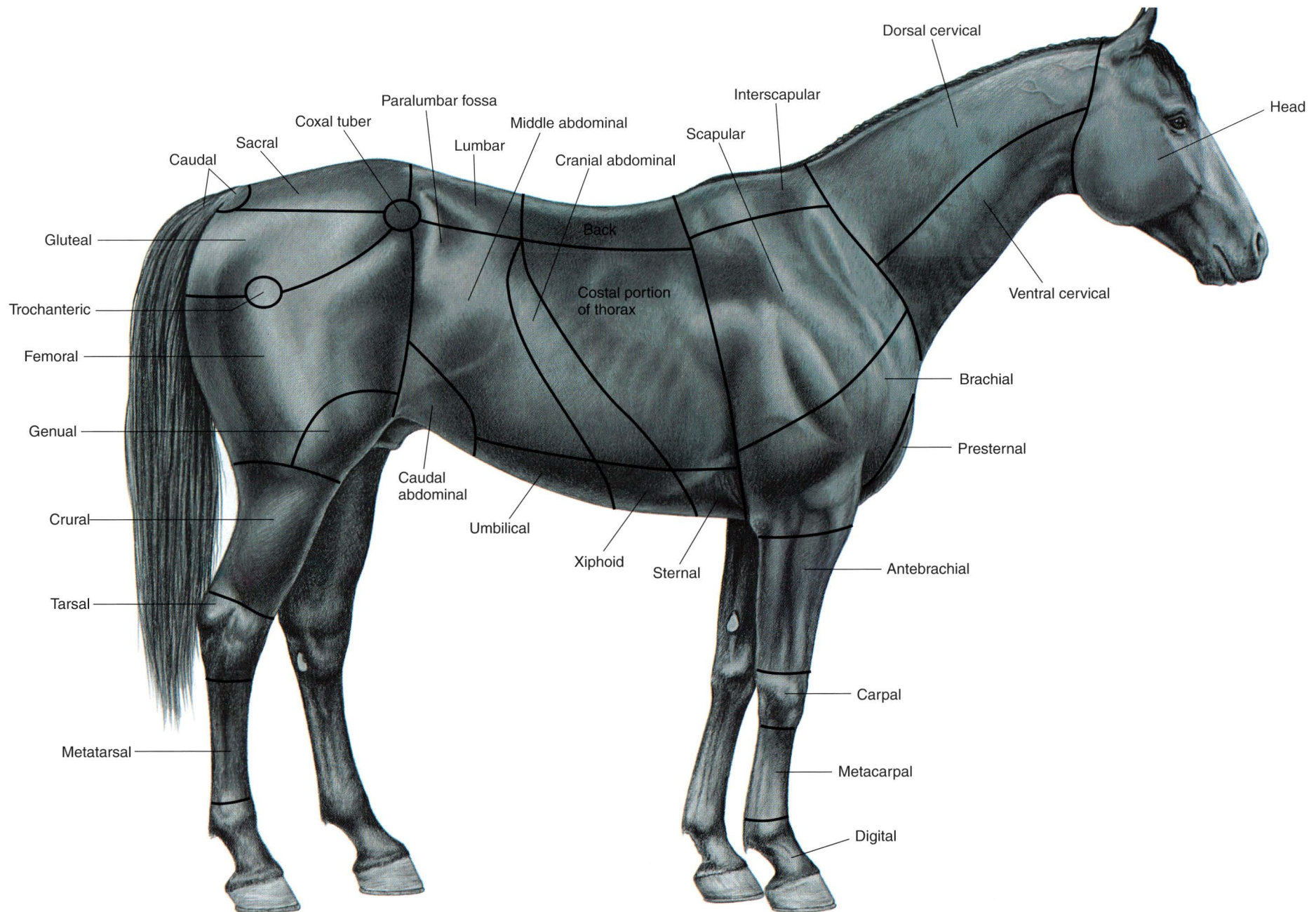


PLATE 1.3 Body regions of the horse. Right lateral view.






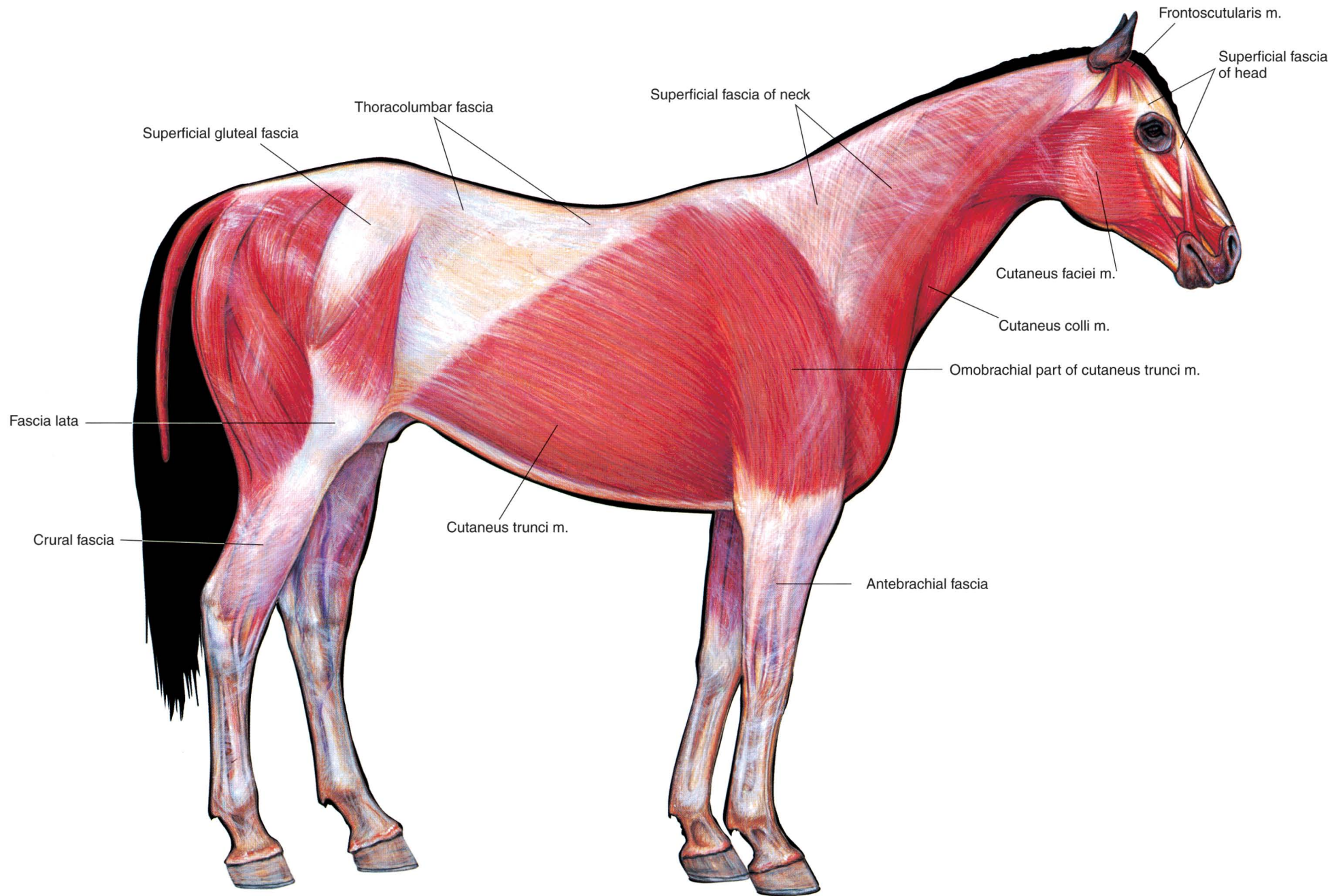


PLATE 1.5 Cutaneous muscles and major fasciae of the stallion. Right lateral view. m = muscle



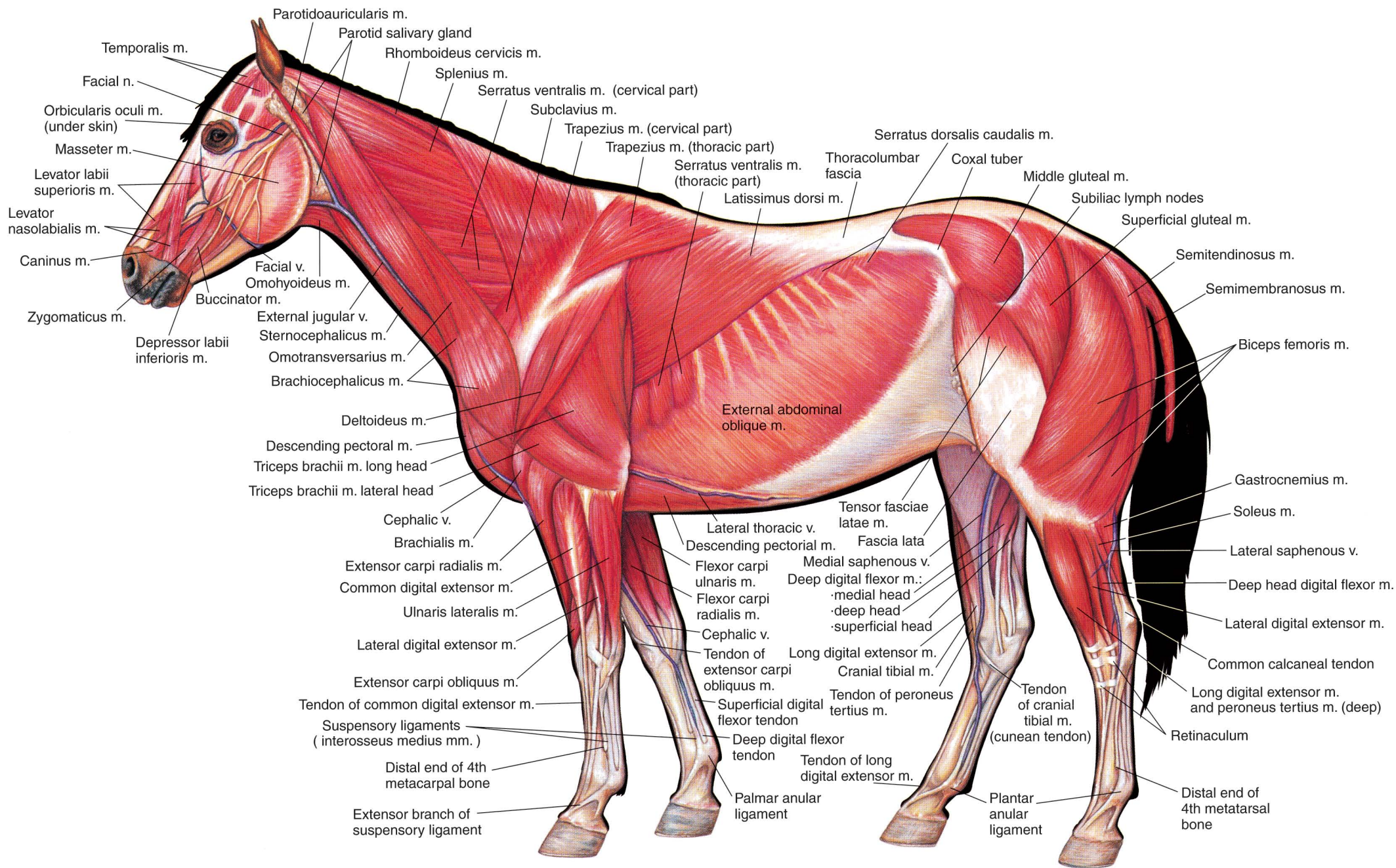
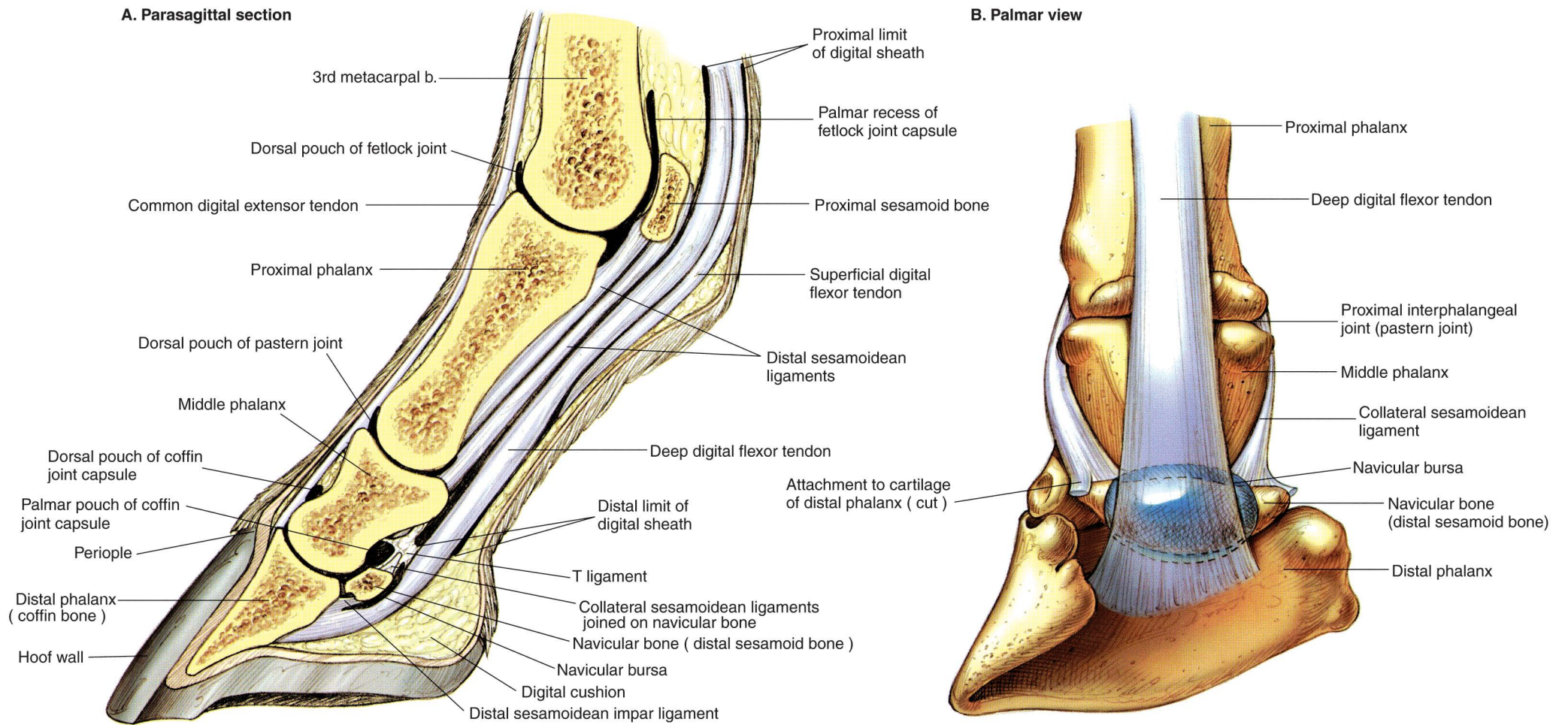
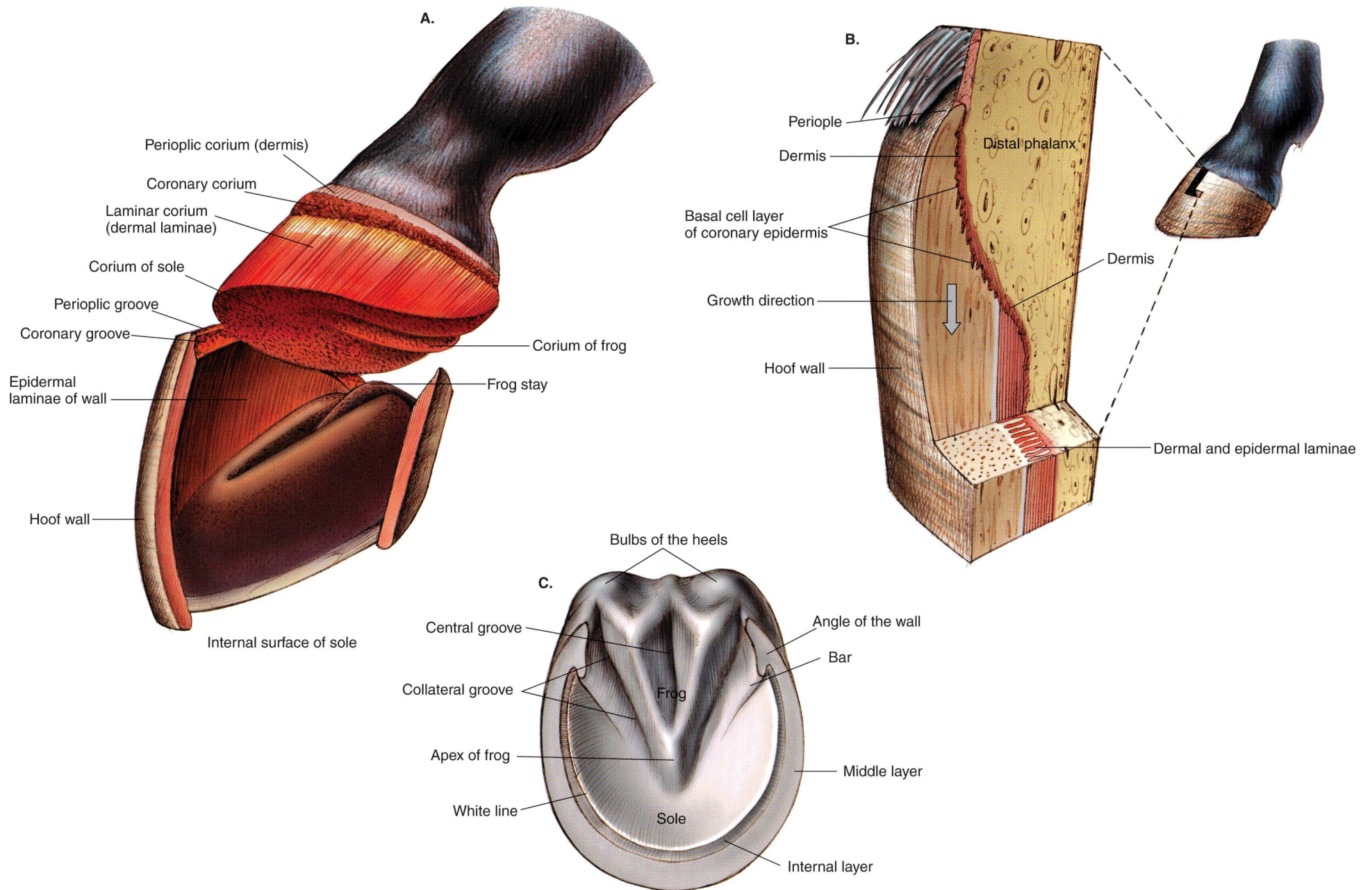


PLATE 1.6 Superficial muscles and veins of the mare. Left lateral view.  
 m = muscle, n = nerve, v = vein




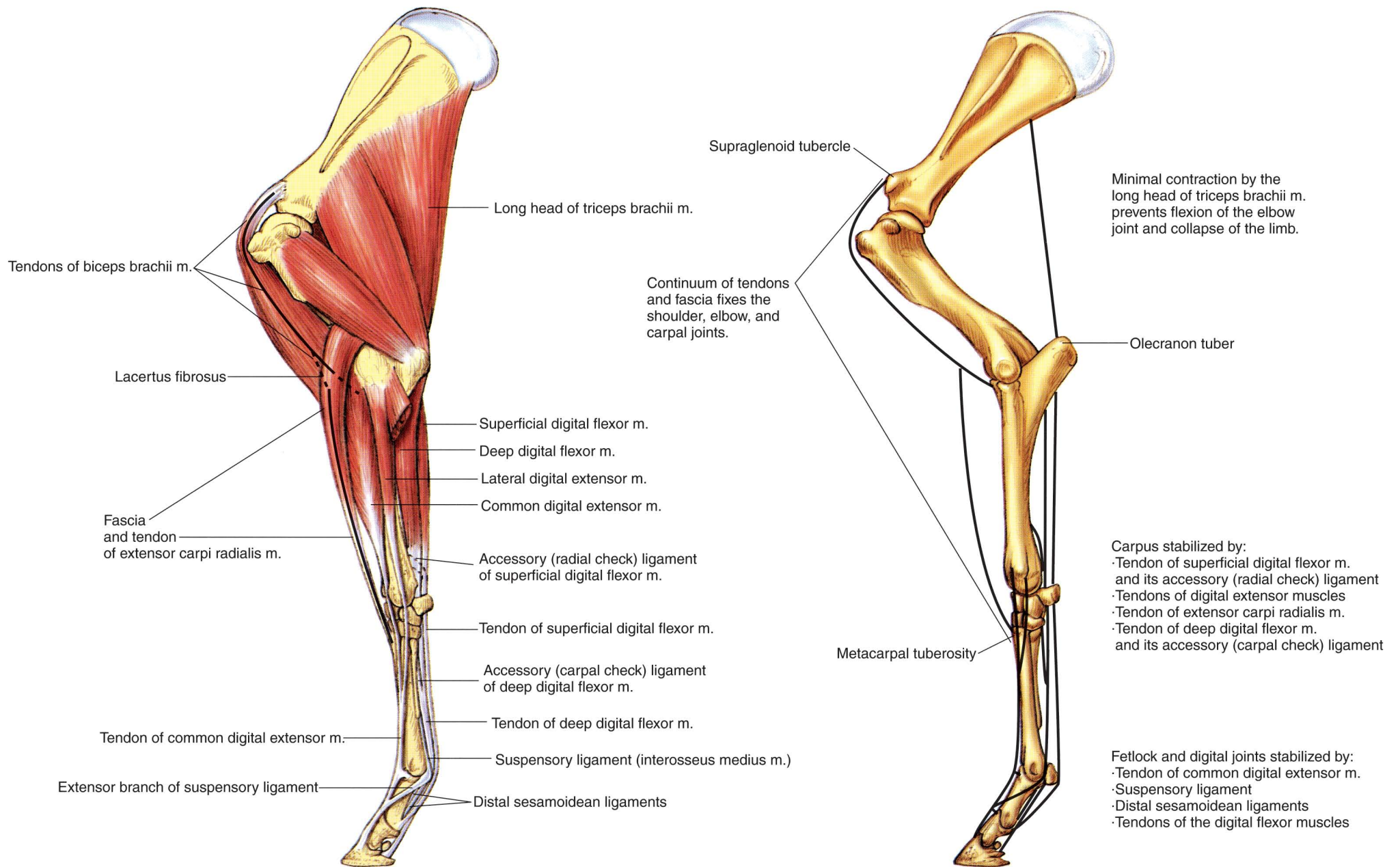


**PLATE 1.7** A. Parasagittal section of the equine digit. B. Palmar (plantar) view of major structures of the equine digit. Navicular bursa obscures joining of collateral sesamoidean ligaments on the navicular bone. b = bone



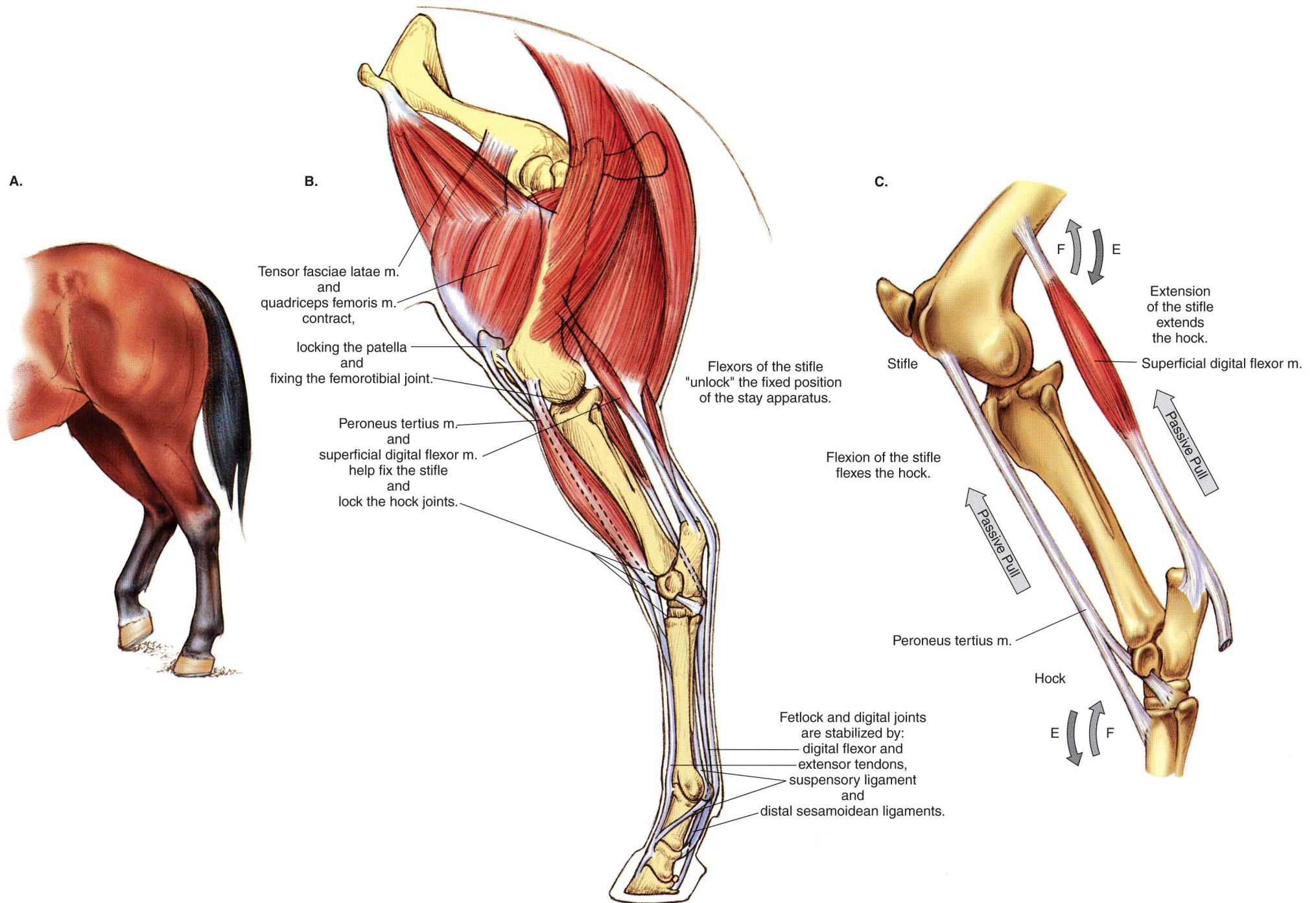
**PLATE 1.8** Relations of the hoof. **A.** Separation of the hoof to show its relations to regions of the corium. **B.** Three-dimensional dissection to show relations of the hoof wall, coronary and laminar corium, and distal phalanx. **C.** Solar surface of the hoof.





**PLATE 1.9** Stay apparatus of the equine forelimb. The continuum of tendons and ligaments with minimal muscular activity stabilizes joints of the forelimb in the standing position. m = muscle





**PLATE 1.10** Stay apparatus and reciprocal apparatus of the hindlimb. **A.** One hindlimb partly flexed with its toe on the ground, and the foot of the opposite limb fixed with minimal muscular activity by the stay apparatus. **B.** Stay apparatus of the hindlimb. **C.** The reciprocal apparatus. m = muscle



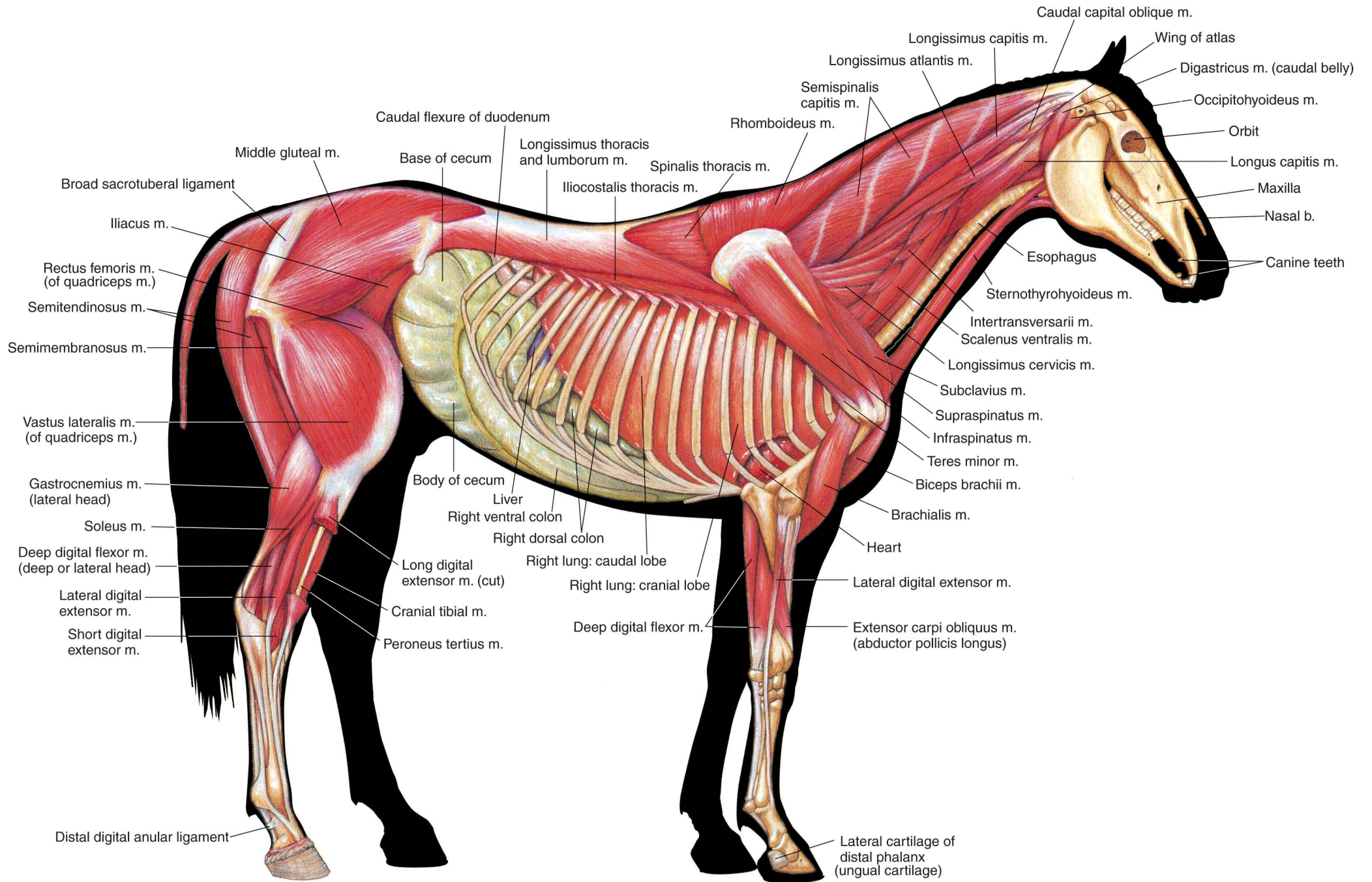
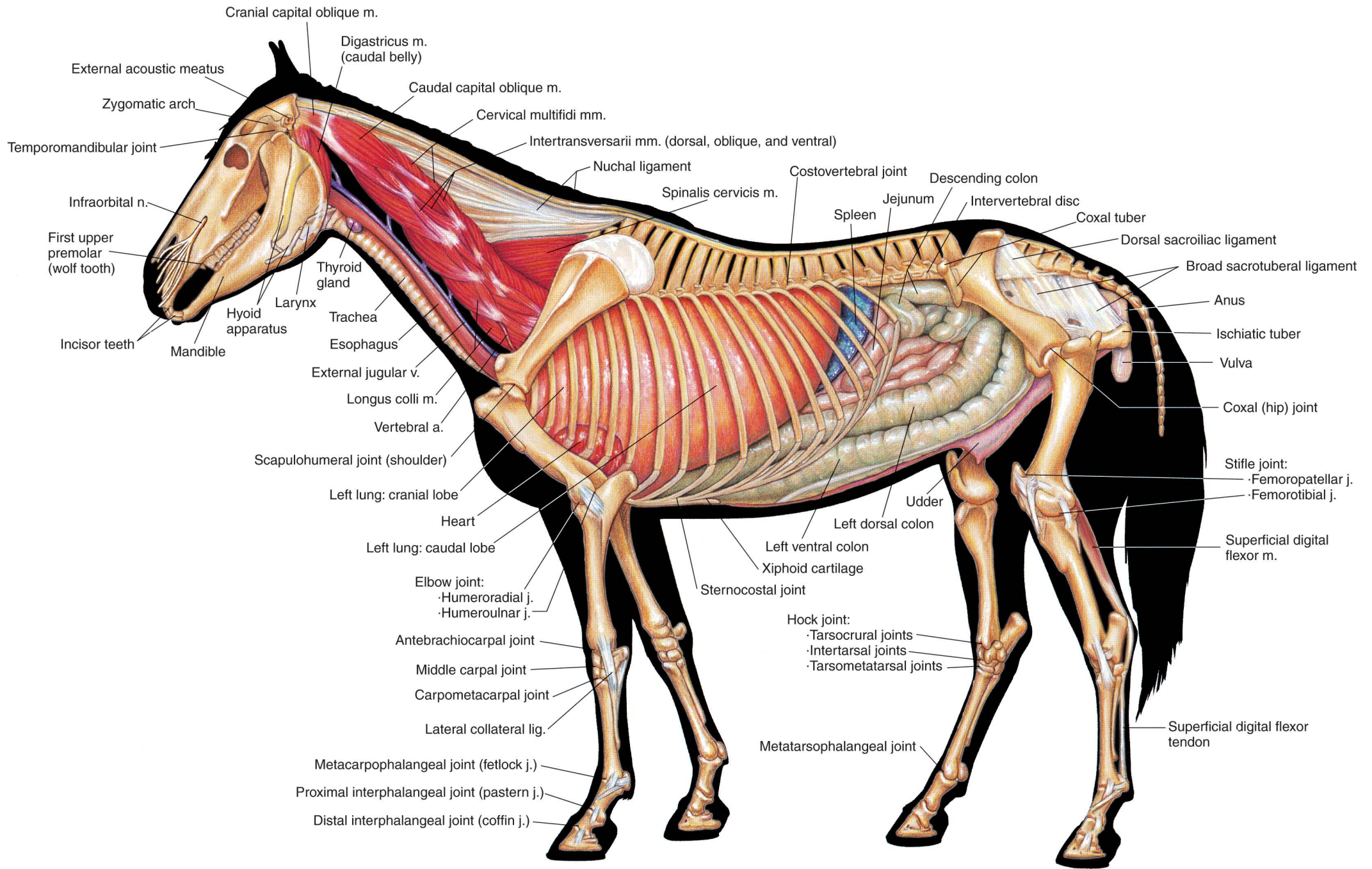


PLATE 1.11 Deep muscles and *in situ* viscera of the stallion.  
 Right lateral view. m = muscle, b = bone





**PLATE 1.12** Deep cervical muscles, major joints, and *in situ* viscera of the mare. Left lateral view.  
 n = nerve, v = vein, m = muscle, a = artery, j = joint, lig = ligament



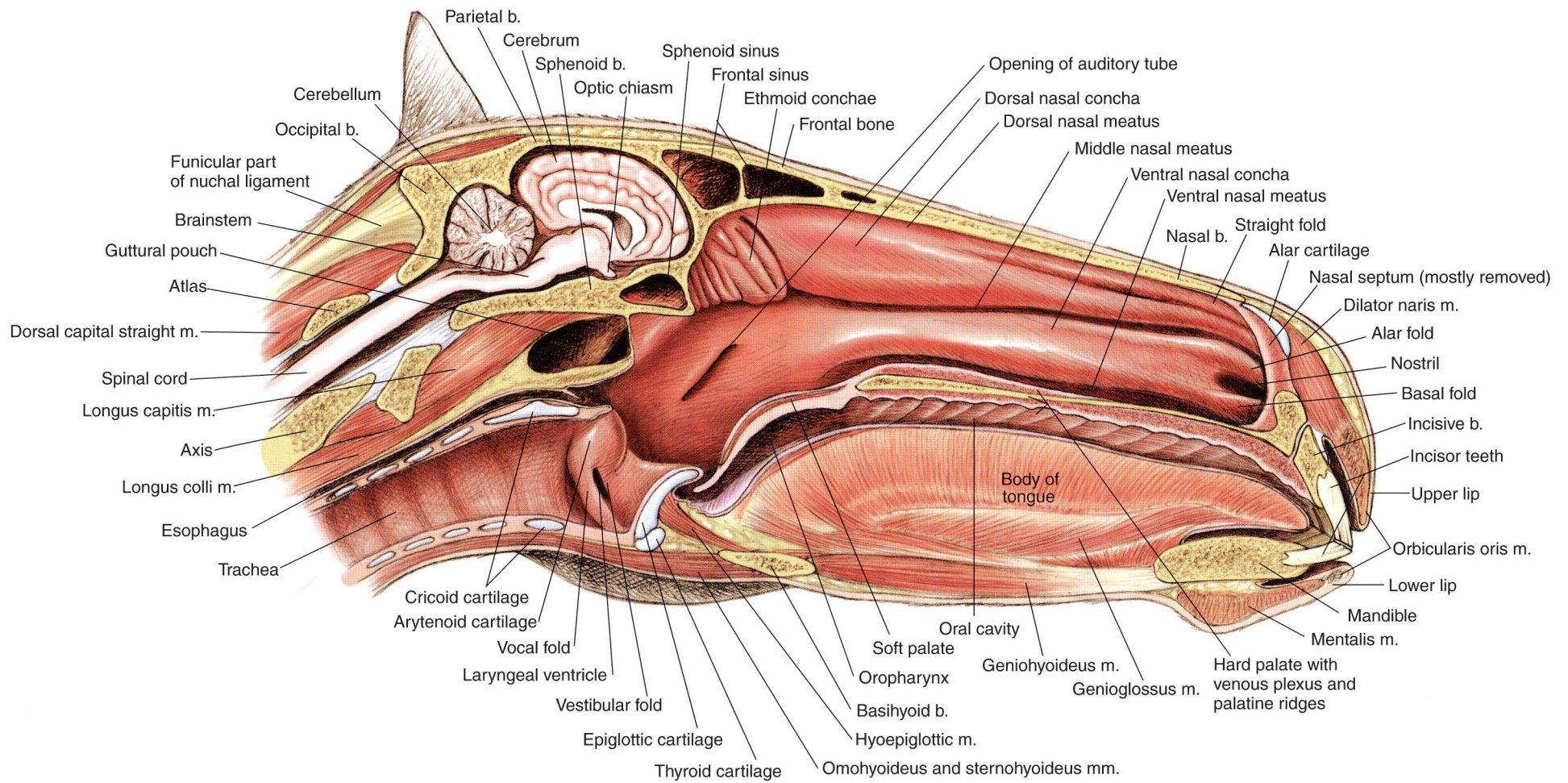
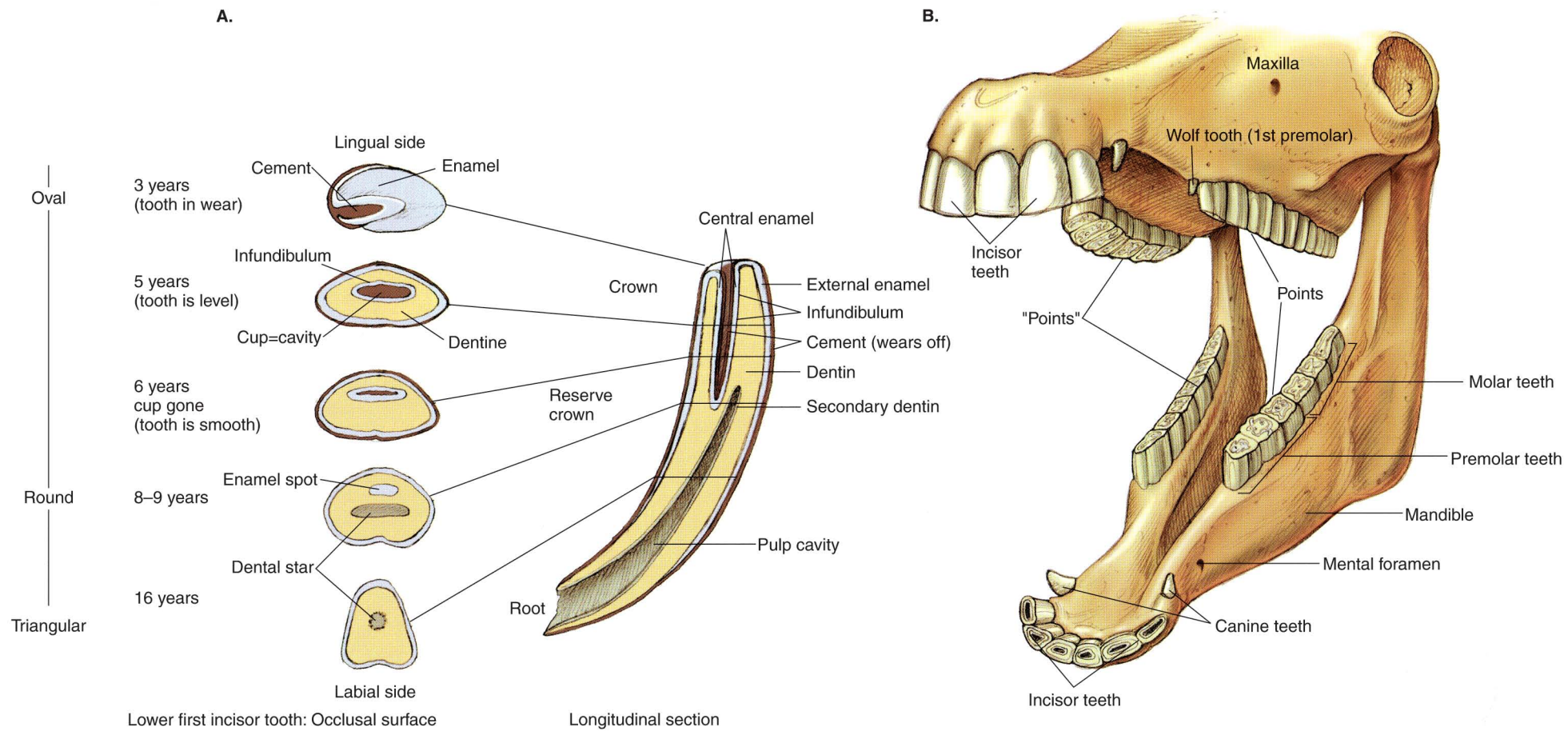
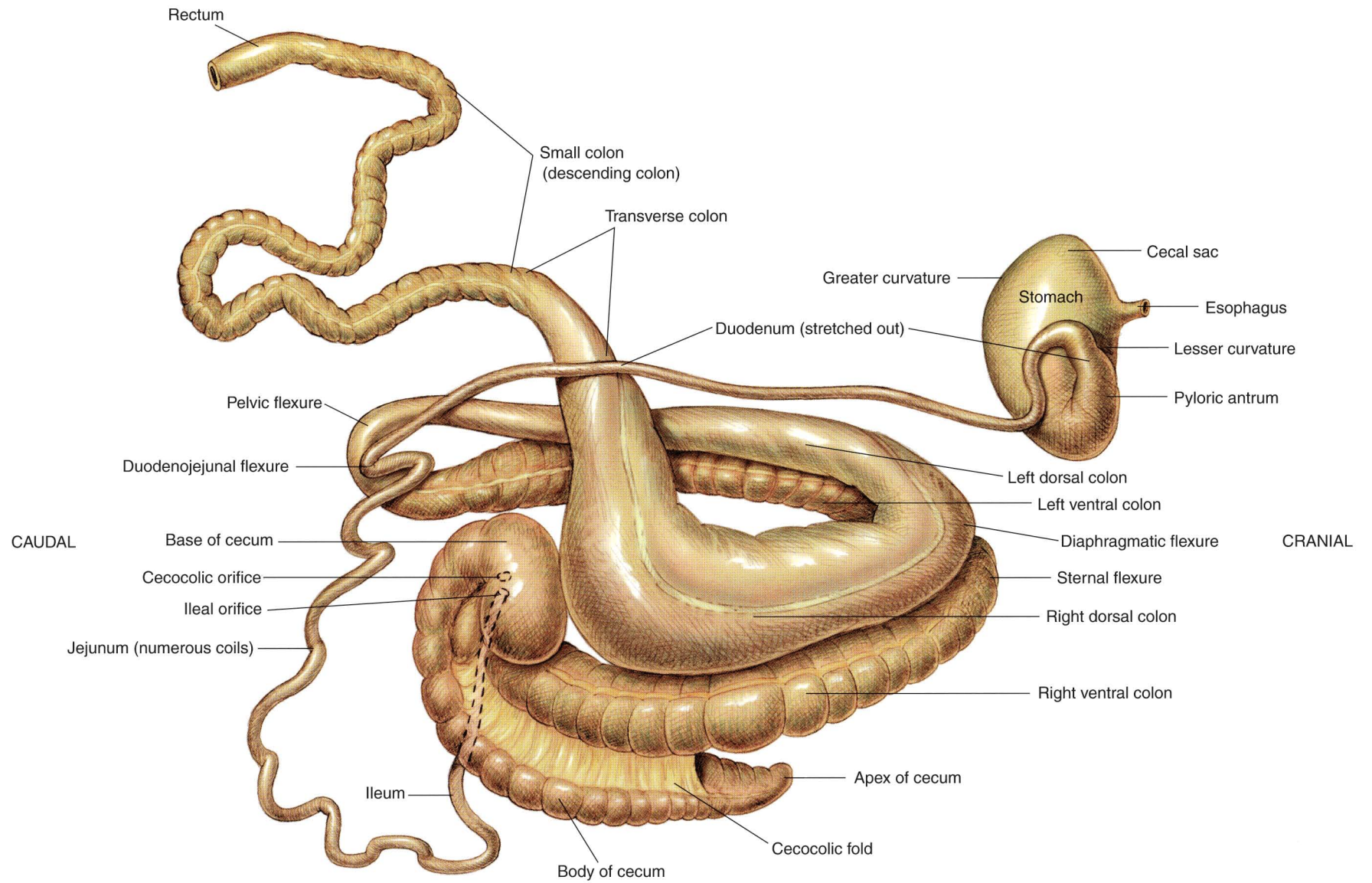


PLATE 1.13 Median section of the horse's head. Nasal septum mostly removed.  
 b = bone, m = muscle

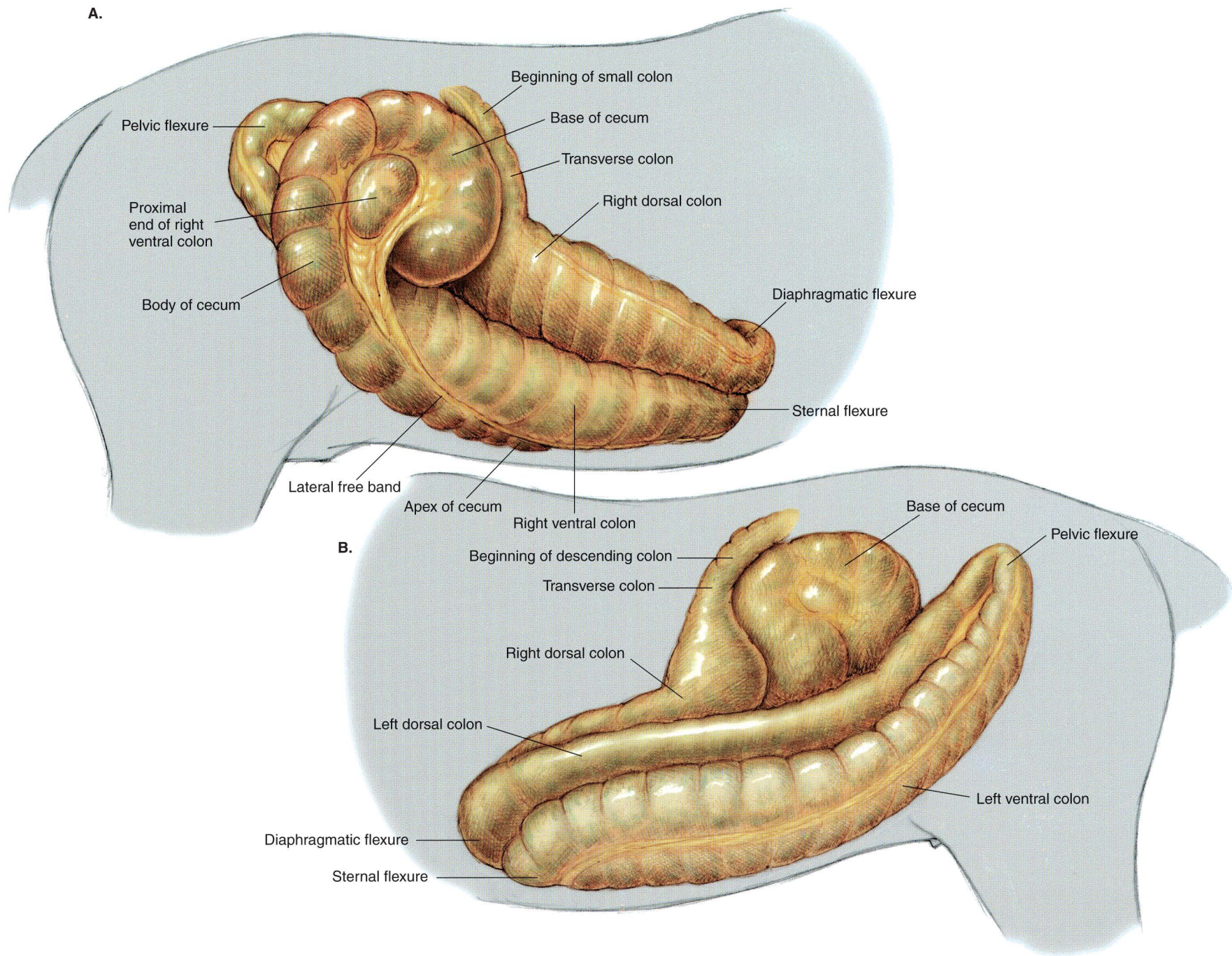




**PLATE 1.14** A. Occlusal (grinding) surfaces of an equine lower first incisor tooth related to continuous eruption and wear. Approximate levels at advancing ages indicated on a longitudinal section. B. Complete dentition of the male horse circa 5 years of age.



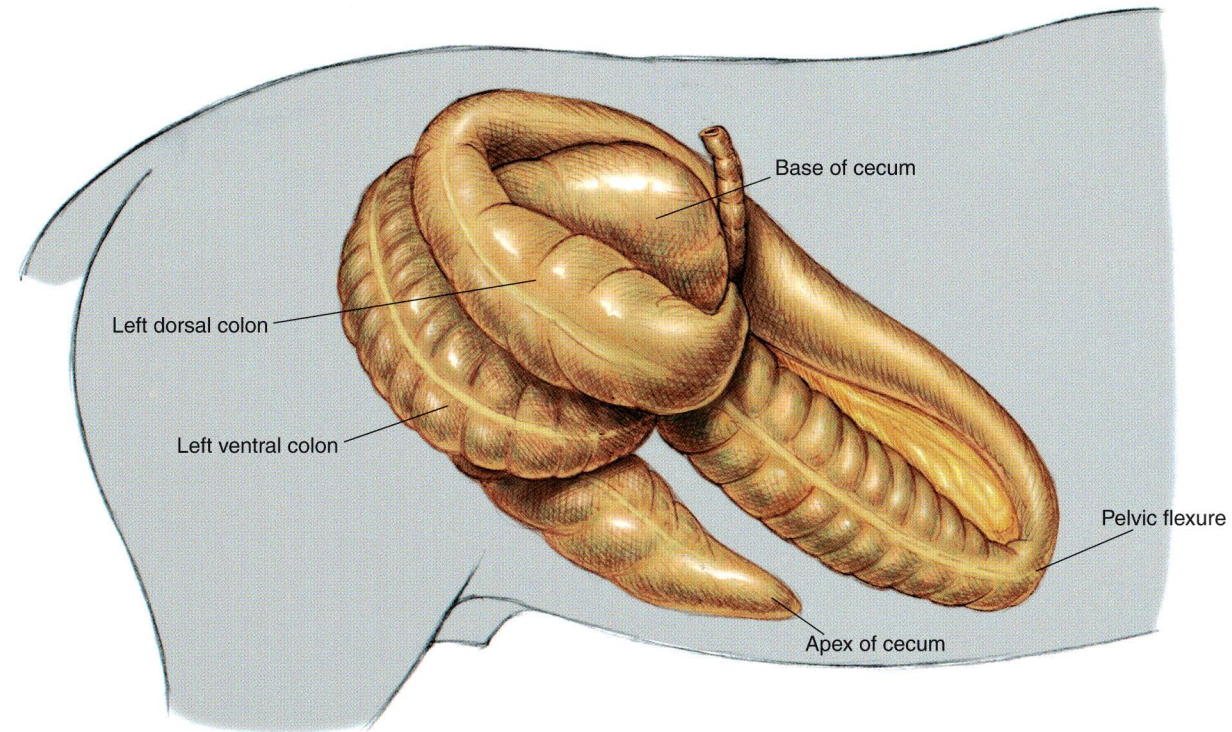




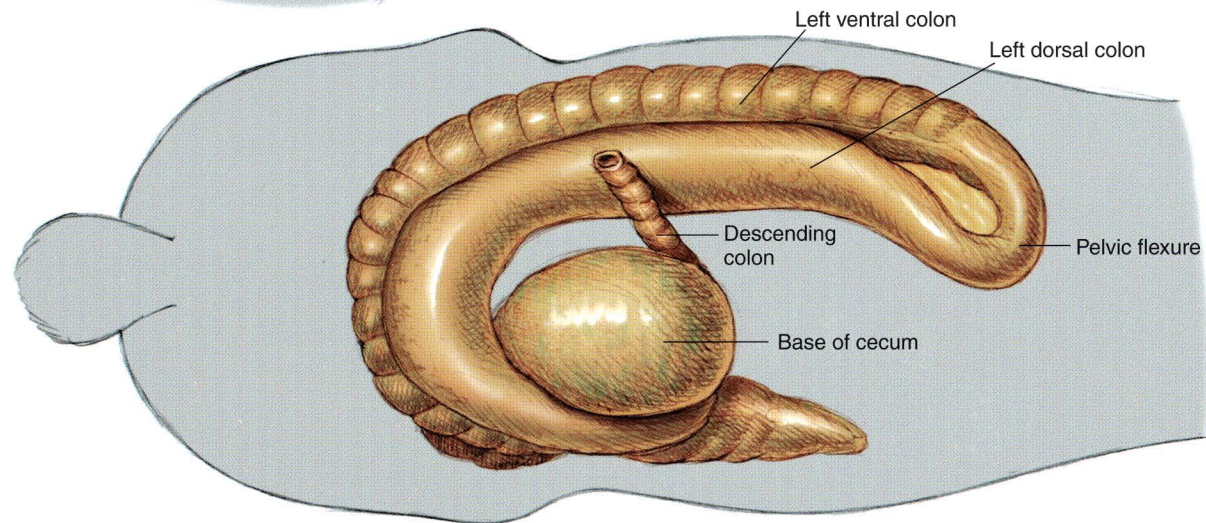
**PLATE 1.16** Equine cecum, large (ascending) colon, and transverse colon *in situ*.  
**A.** Right lateral view. **B.** Left lateral view.



A.

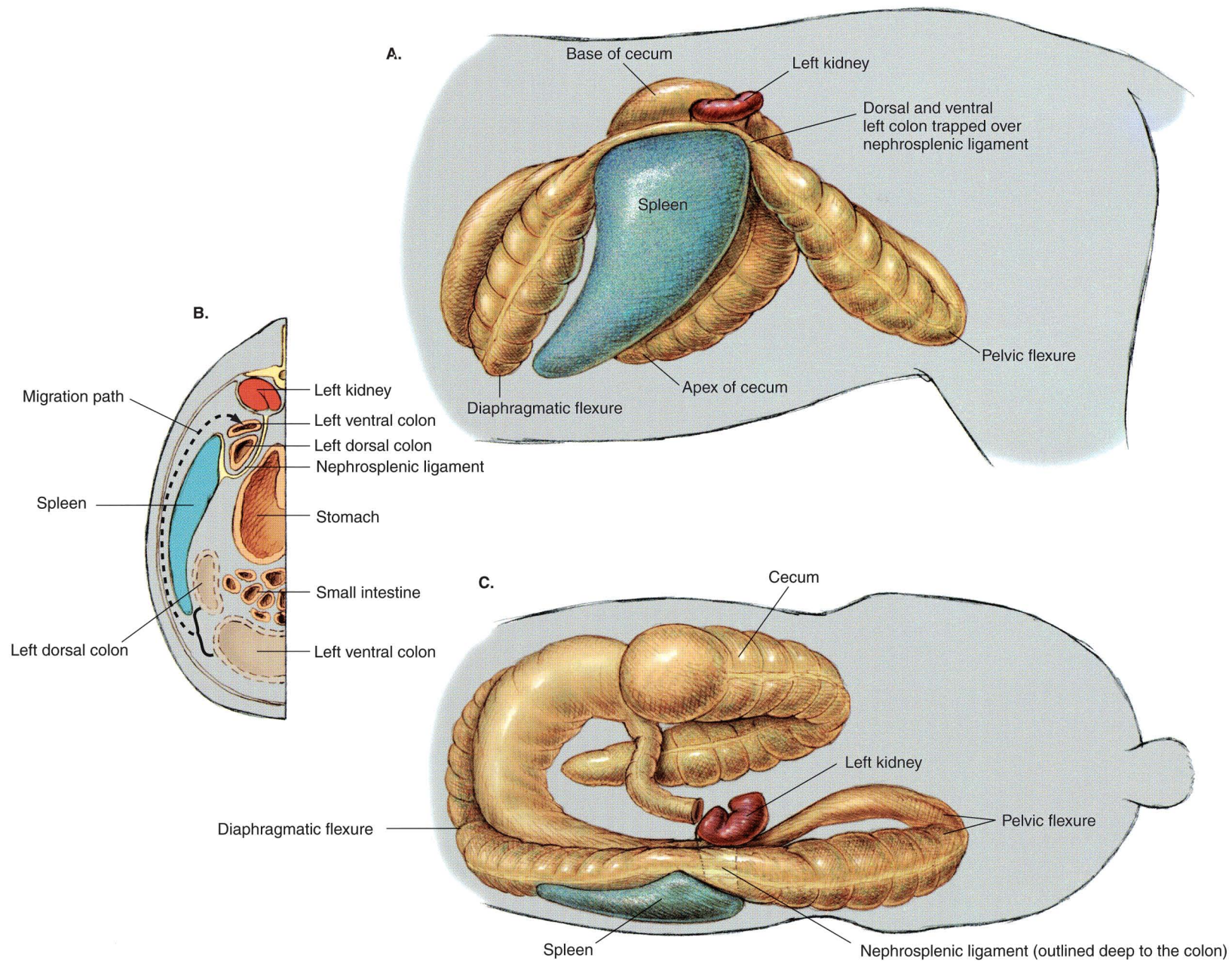


B.



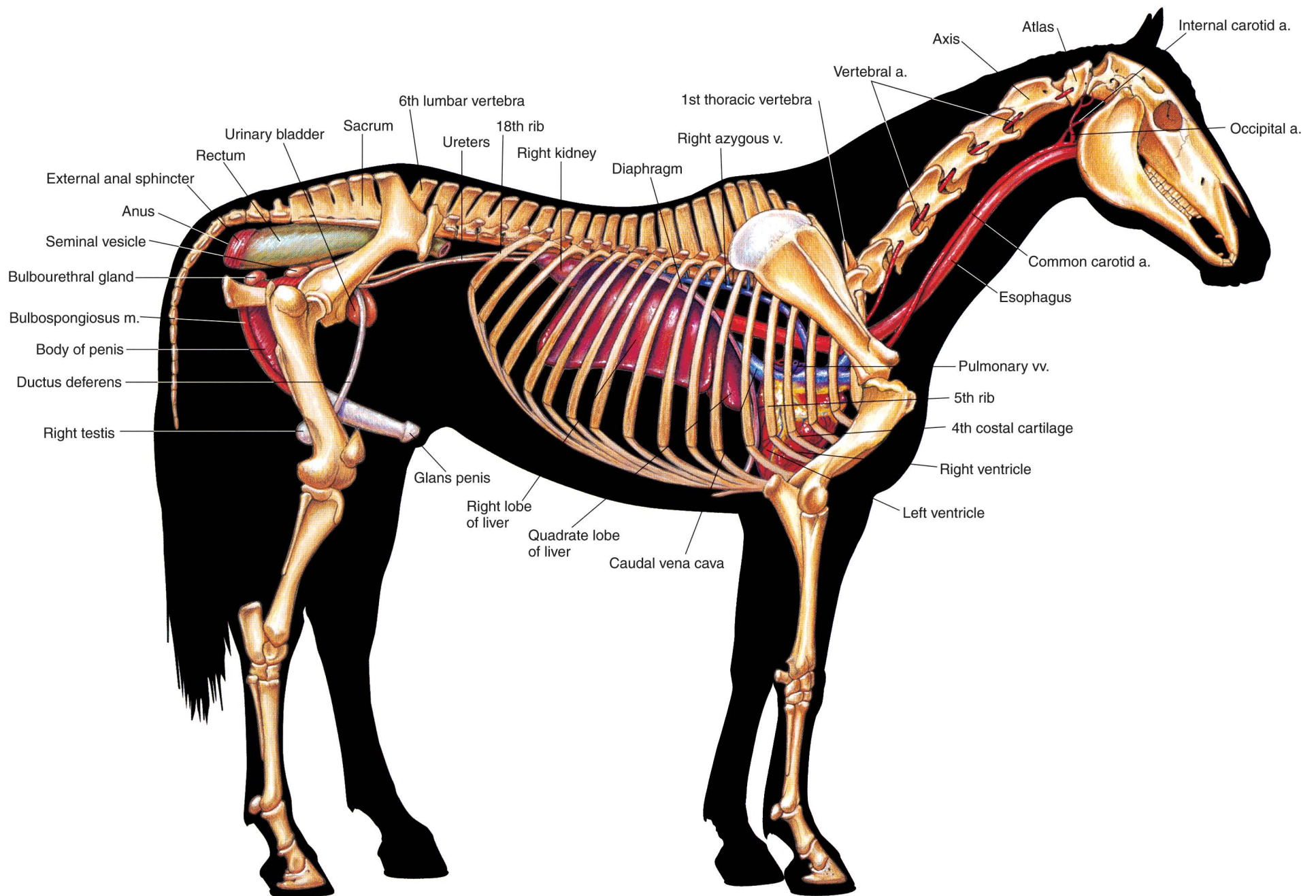
**PLATE 1.17** Clinical condition: Right dorsal displacement of the large colon. **A.** Right lateral view. **B.** Dorsal view. This displacement is a common cause of colic in adult horses. Most commonly, the large colon moves from the left side of the abdomen, courses caudad between the right body wall and the cecum, and comes to lie again in the left portion of the abdomen with the pelvic flexure facing toward the diaphragm. In many cases, the pelvic flexure will not migrate that far craniad and will instead be located in the caudal aspect of the abdomen on either side of the body or the median plane.





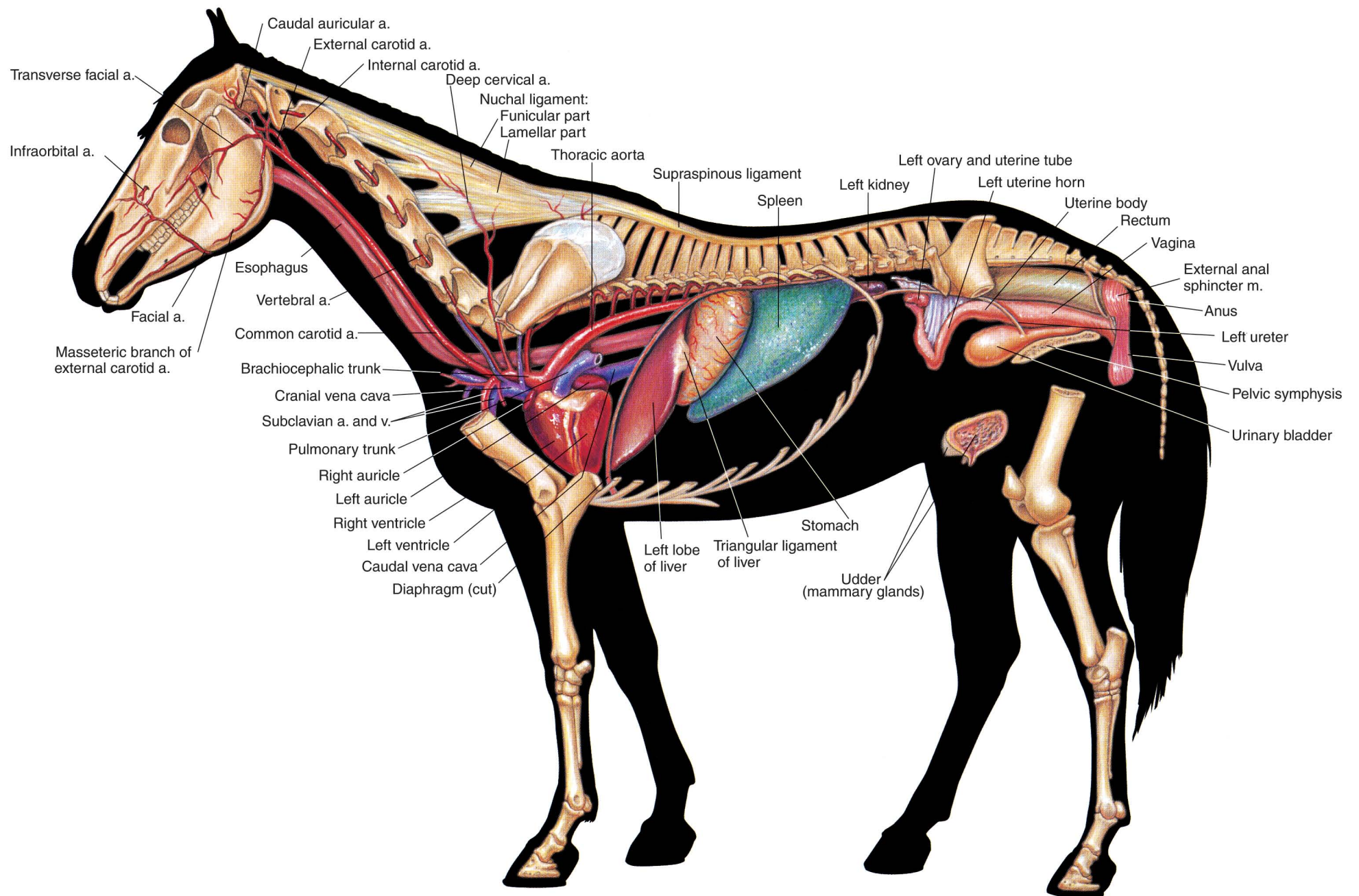
**PLATE 1.18** Clinical condition: Left dorsal displacement of the large colon. **A.** Left lateral view. **B.** Cross-section of the left side of the abdomen. Caudocranial view. **C.** Dorsal view. In this displacement, the left colon moves dorsad and becomes entrapped over the nephrosplenic ligament. The abnormal position of the left colon can often be confirmed by rectal examination, and, many times, left dorsal displacement can be corrected by anesthetizing and rolling the horse to free the entrapment.





**PLATE 1.19** Reproductive organs, urinary organs, liver, heart, and adjacent major vessels related to the skeleton of the stallion. Intestines and lungs are removed.  
Right lateral view. v = vein, a = artery, m = muscle





**PLATE 1.20** Heart and some adjacent major vessels, abdominal and pelvic viscera, and udder (mammary glands) of the mare. Intestines and lungs are removed. Left lateral view. a = artery, v = vein, m = muscle



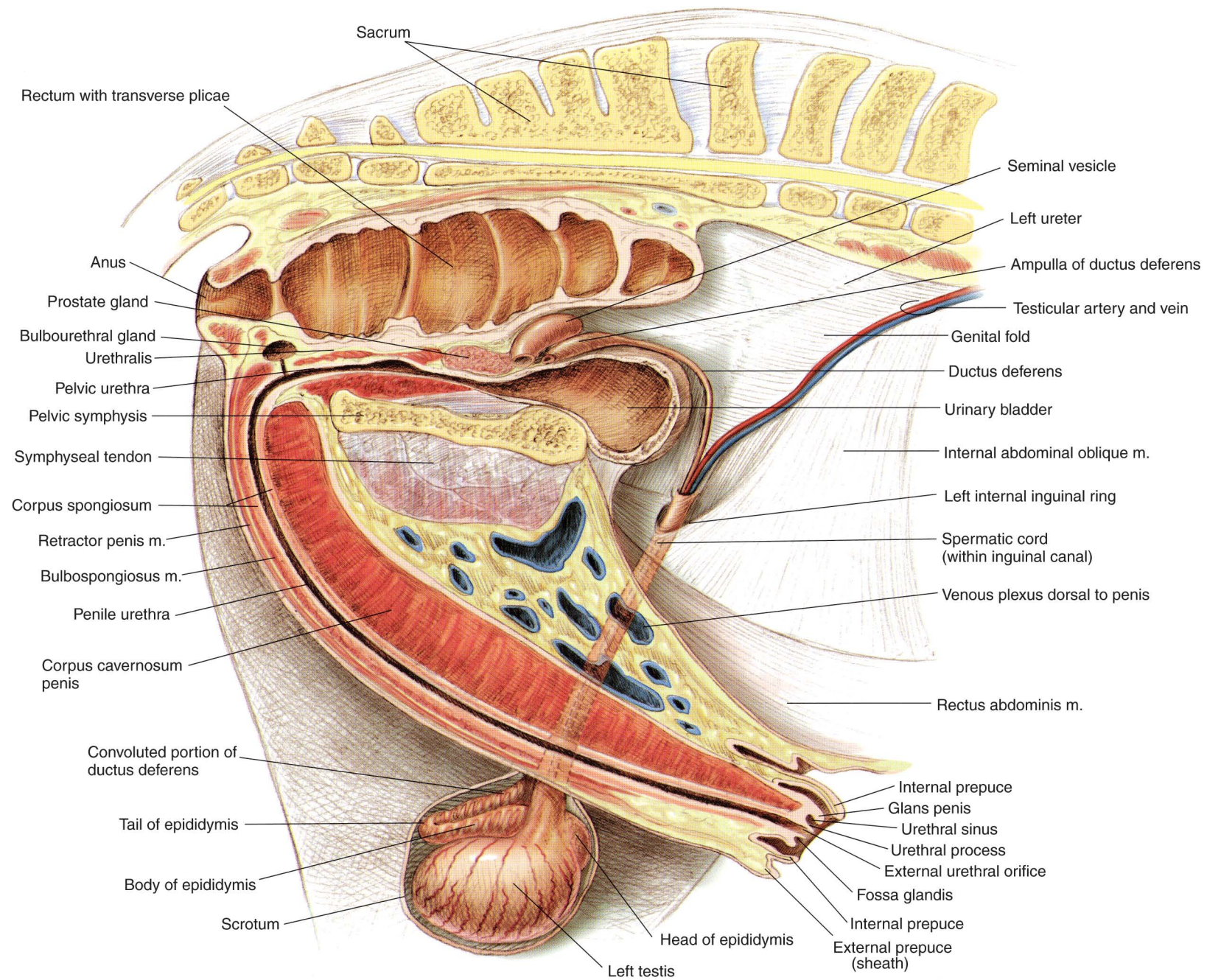
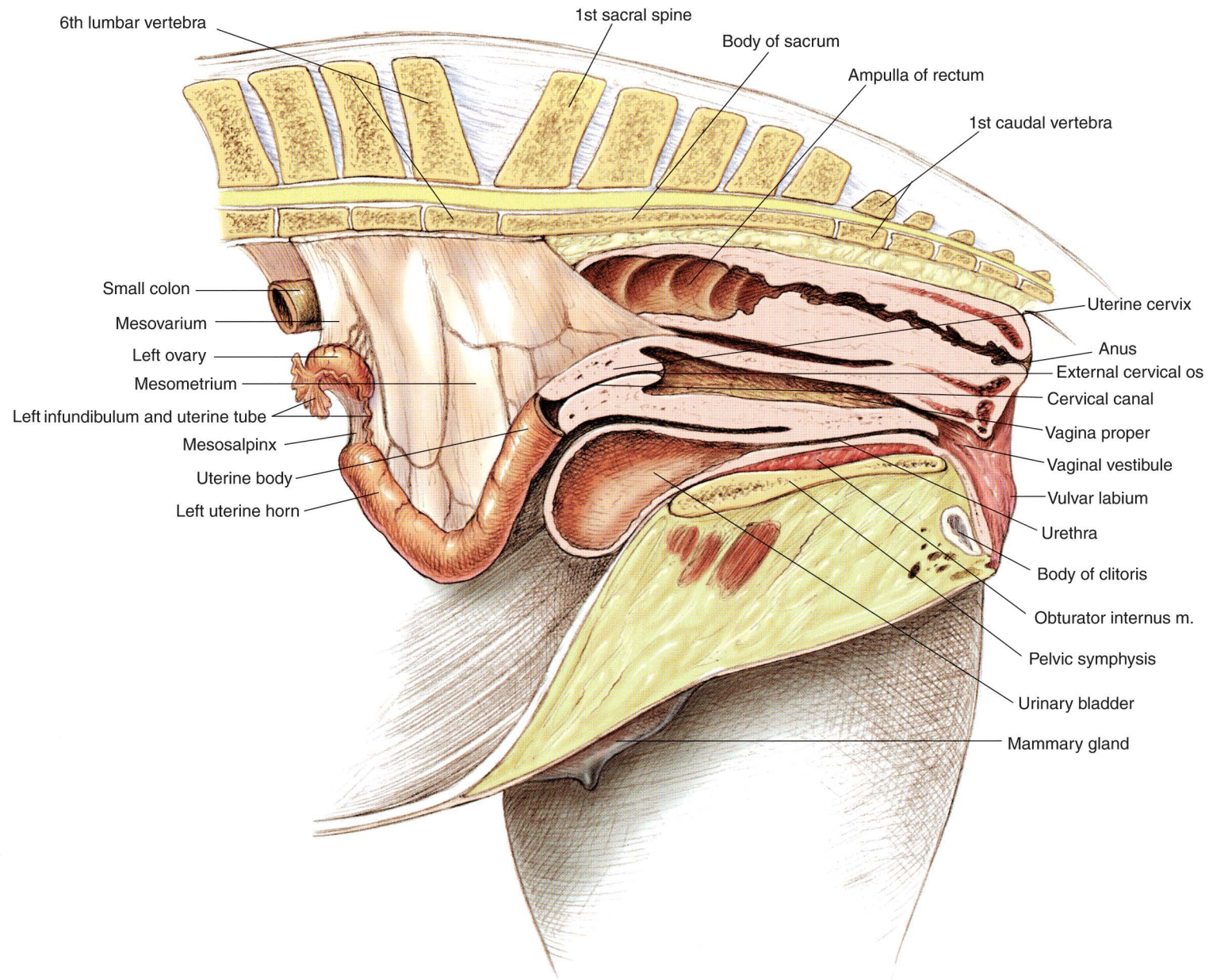
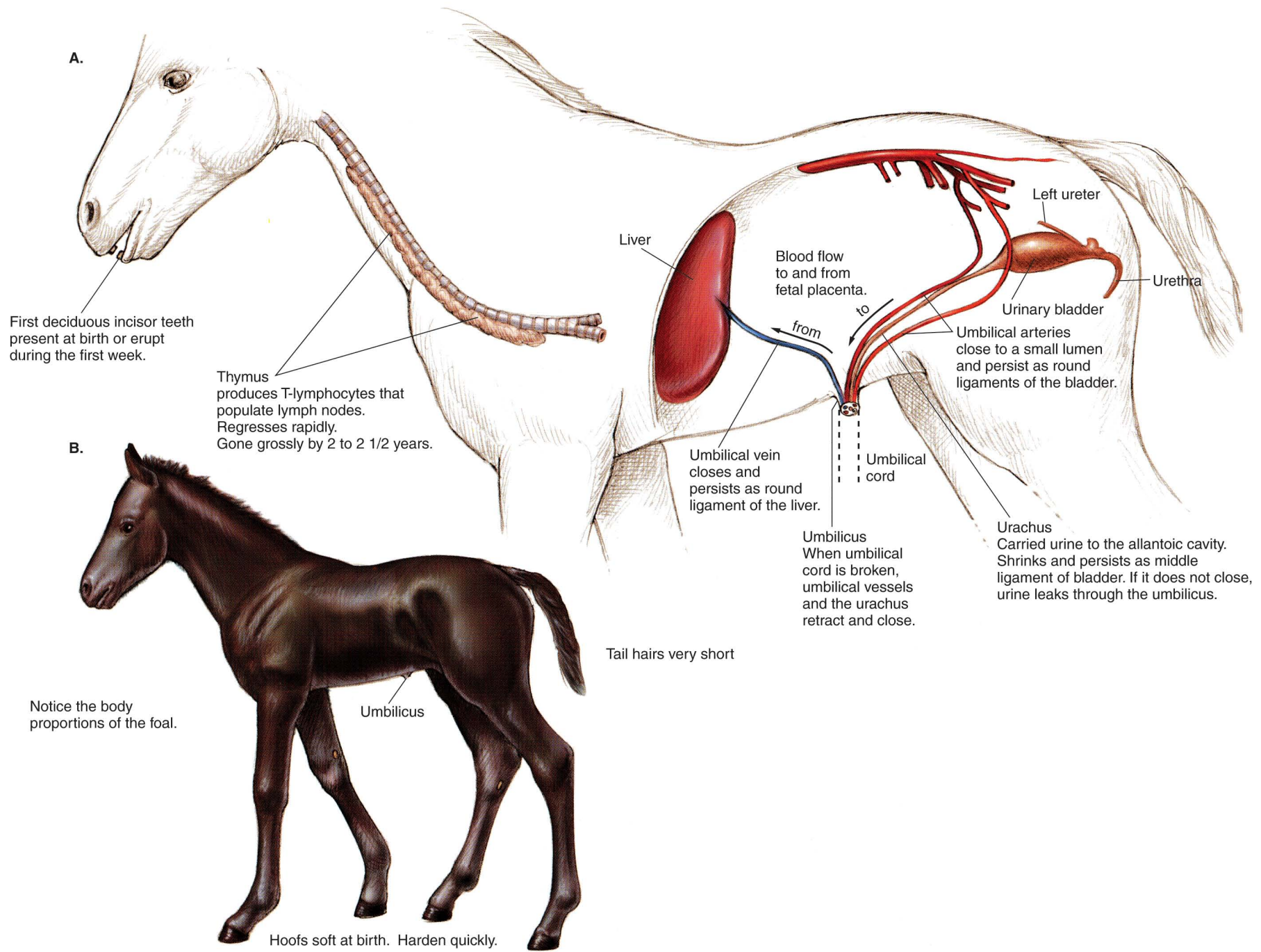


PLATE 1.21 Relations of the reproductive organs of the stallion.  
Median section, right lateral view. m = muscle





**PLATE 1.22** Relations of the reproductive organs of the mare. Partial median section.  
Left lateral view. m = muscle





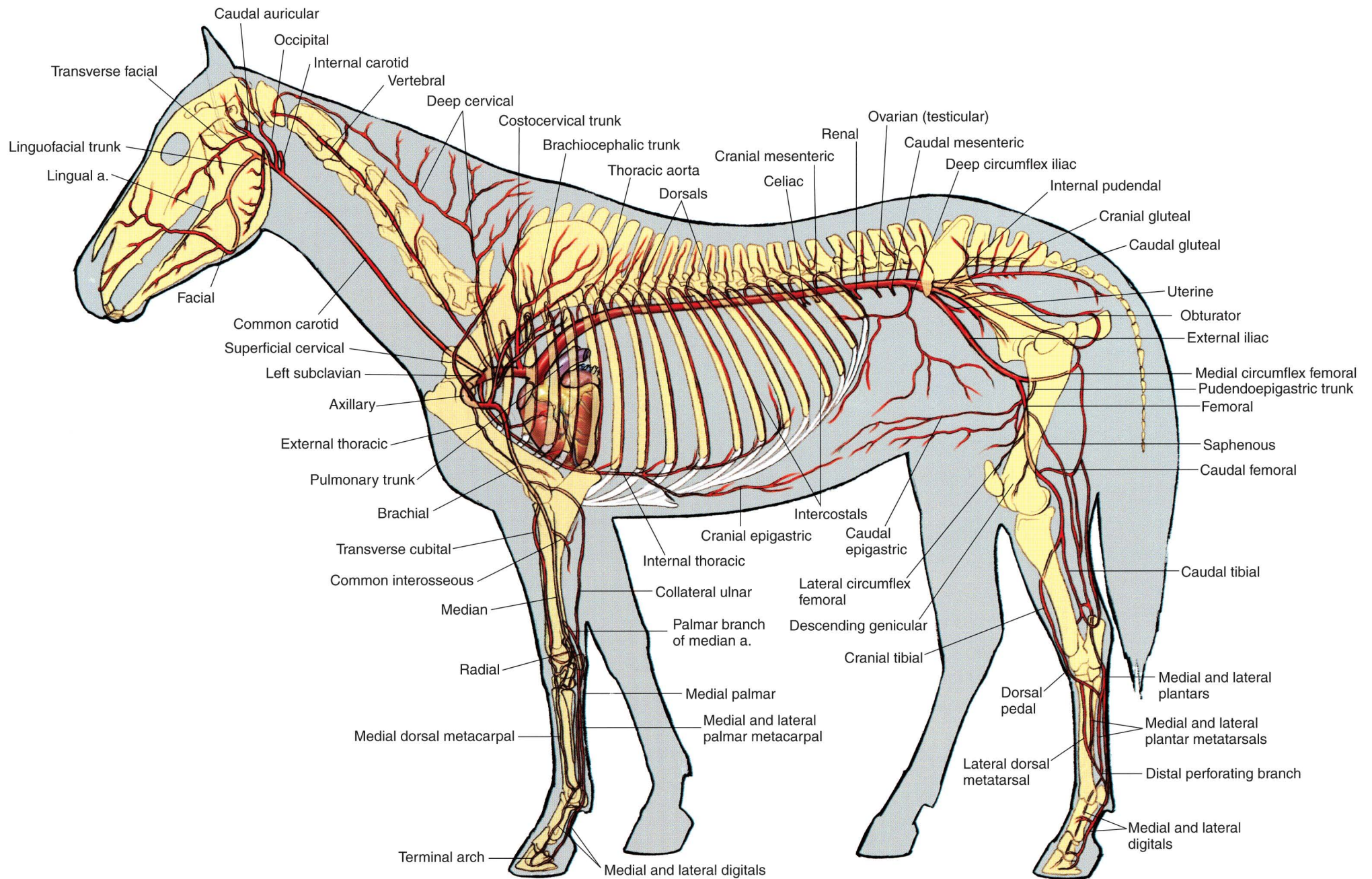


PLATE 1.24 Major arteries of the mare. Left lateral view. a = artery



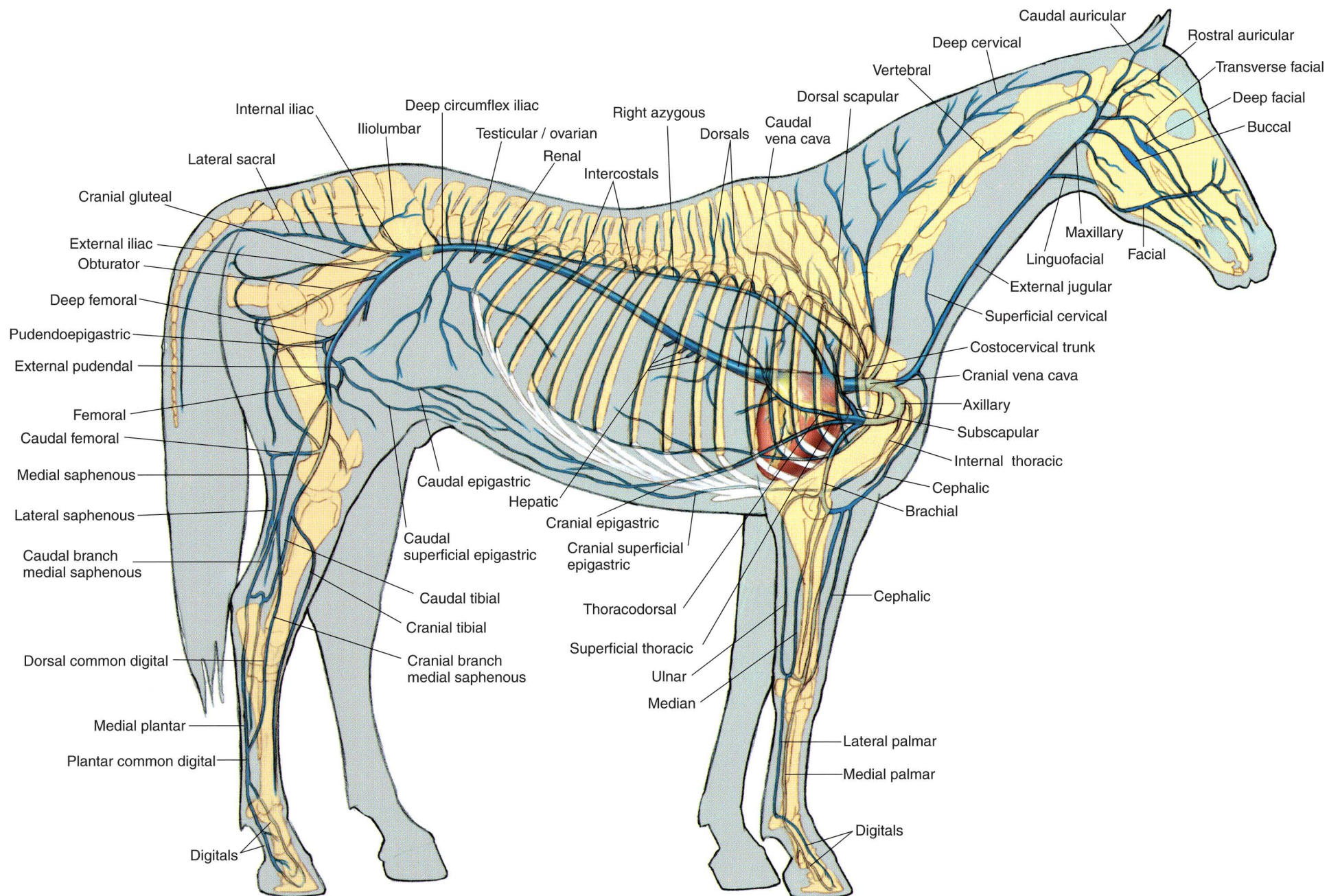
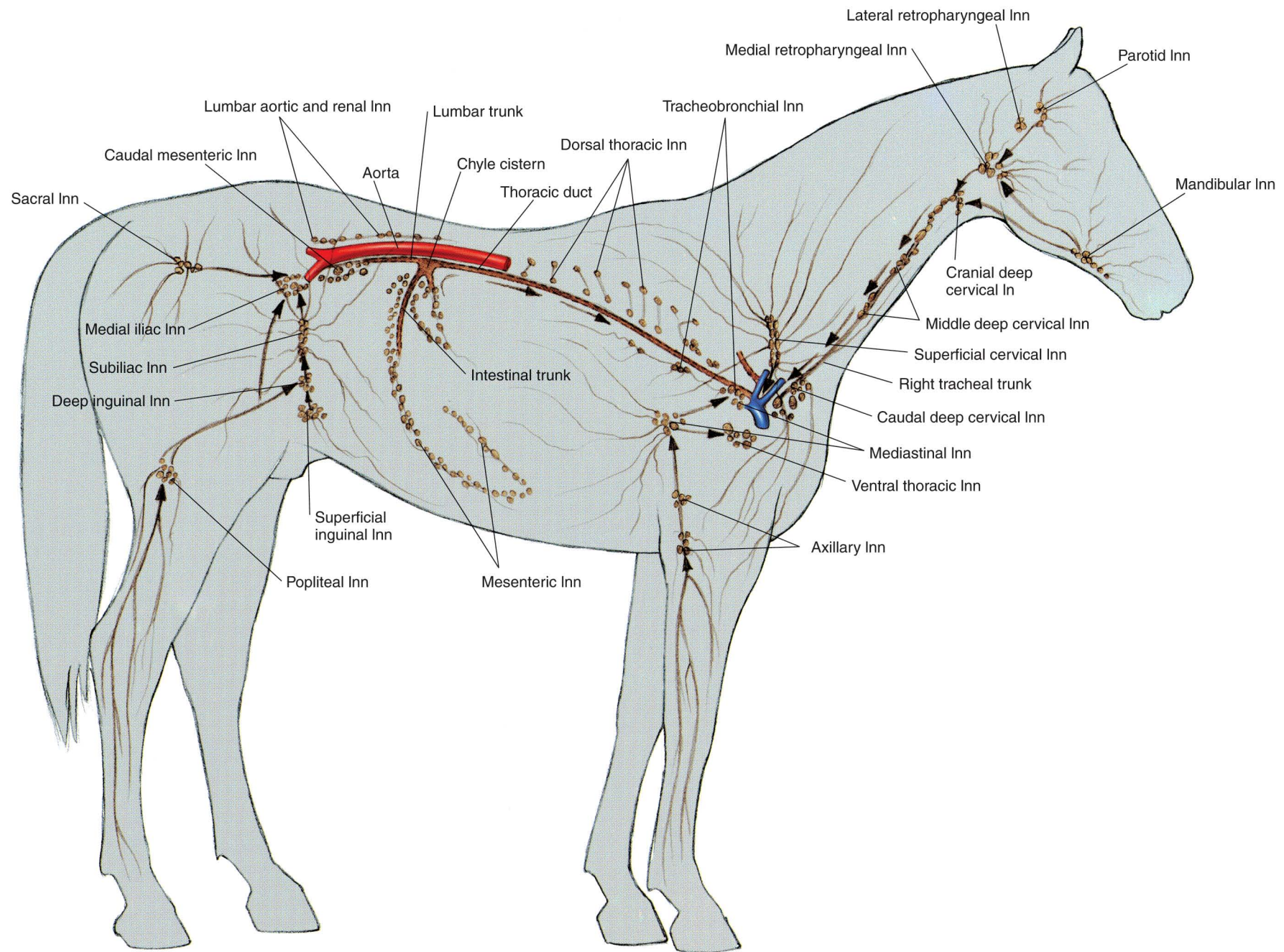


PLATE 1.25 Major veins of the stallion. Portal system excluded. Right lateral view.





**PLATE 1.26** Lymph nodes and vessels of the horse. Right lateral view. *Arrows* indicate the flow of lymph. Lymph node groups in the horse consist of up to dozens of lymph nodes ranging in size from a few millimeters to 2 centimeters in diameter. In = lymph node







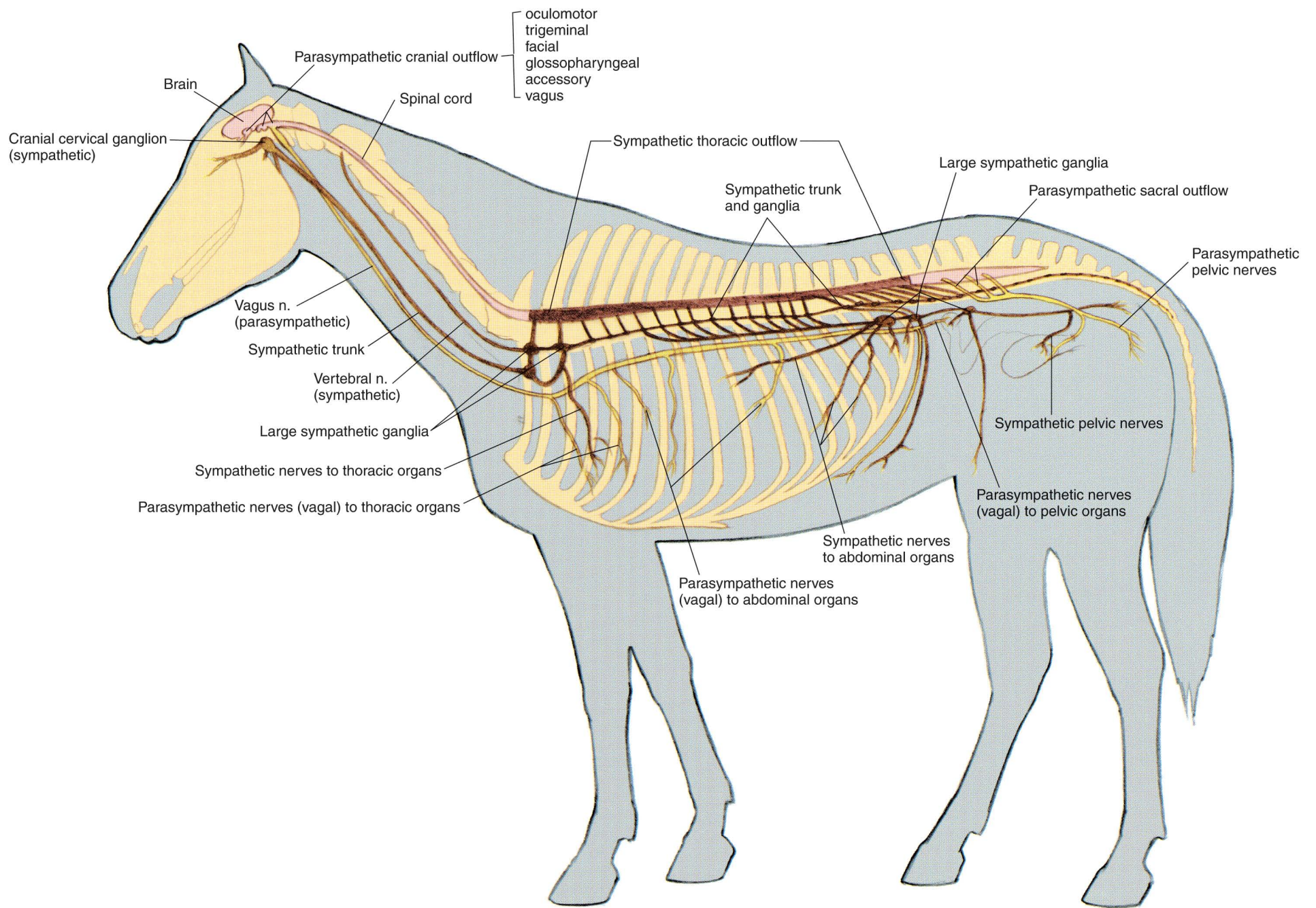


PLATE 1.28 Autonomic nervous system of the mare. Left lateral view. n = nerve

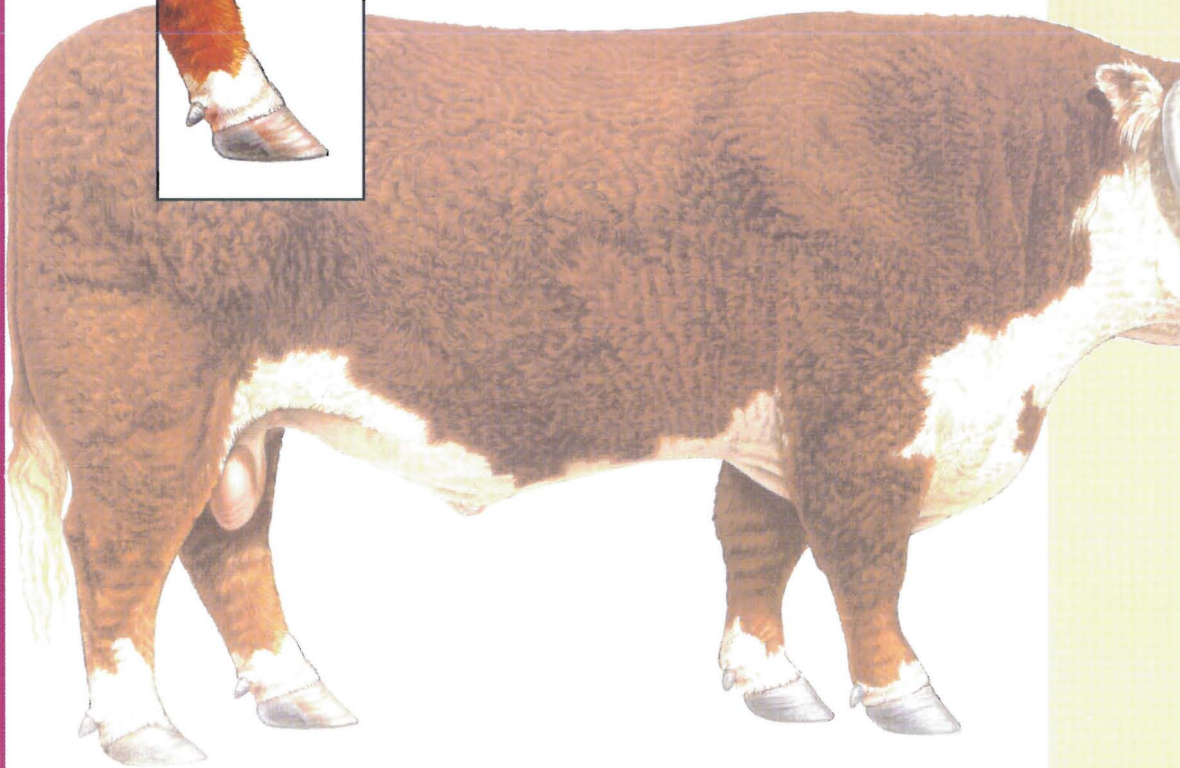



# SECTION 2 THE OX (*Bos taurus*, also *Bos indicus*)

## PLATES

- 2.1 Right lateral view of a beef bull.
- 2.2 Left lateral view of a dairy cow.
- 2.3 Body regions of the ox.
- 2.4 Skeleton of the ox.
- 2.5 Cutaneous muscles and major fasciae of the bull.
- 2.6 Superficial muscles and veins of the cow.
- 2.7 Deep cervical muscles and *in situ* viscera of the bull.
- 2.8 Deep cervical muscles, major joints, *in situ* viscera, and udder of the cow.
- 2.9 Median section of the head and left lateral view of the respiratory system of the ox.
- 2.10 Interior of the rumen and reticulum of the cow.
- 2.11 Clinical condition: Right volvulus of the abomasum in a bull.
- 2.12 Clinical condition: Left displacement of the abomasum in a cow.
- 2.13 Reproductive organs, urinary organs, liver, heart, and adjacent major vessels related to the skeleton of the bull.
- 2.14 Heart and adjacent major vessels, abdominal and pelvic viscera, and udder (mammary glands) of the cow.
- 2.15 Relations of the reproductive organs of the bull.
- 2.16 Relations of the reproductive organs of the cow.
- 2.17 Major veins of the bull.
- 2.18 Major arteries of the cow.
- 2.19 Central nervous system and principal nerves of the peripheral nervous system of the bull.
- 2.20 Significant lymphatic organs of the cow.





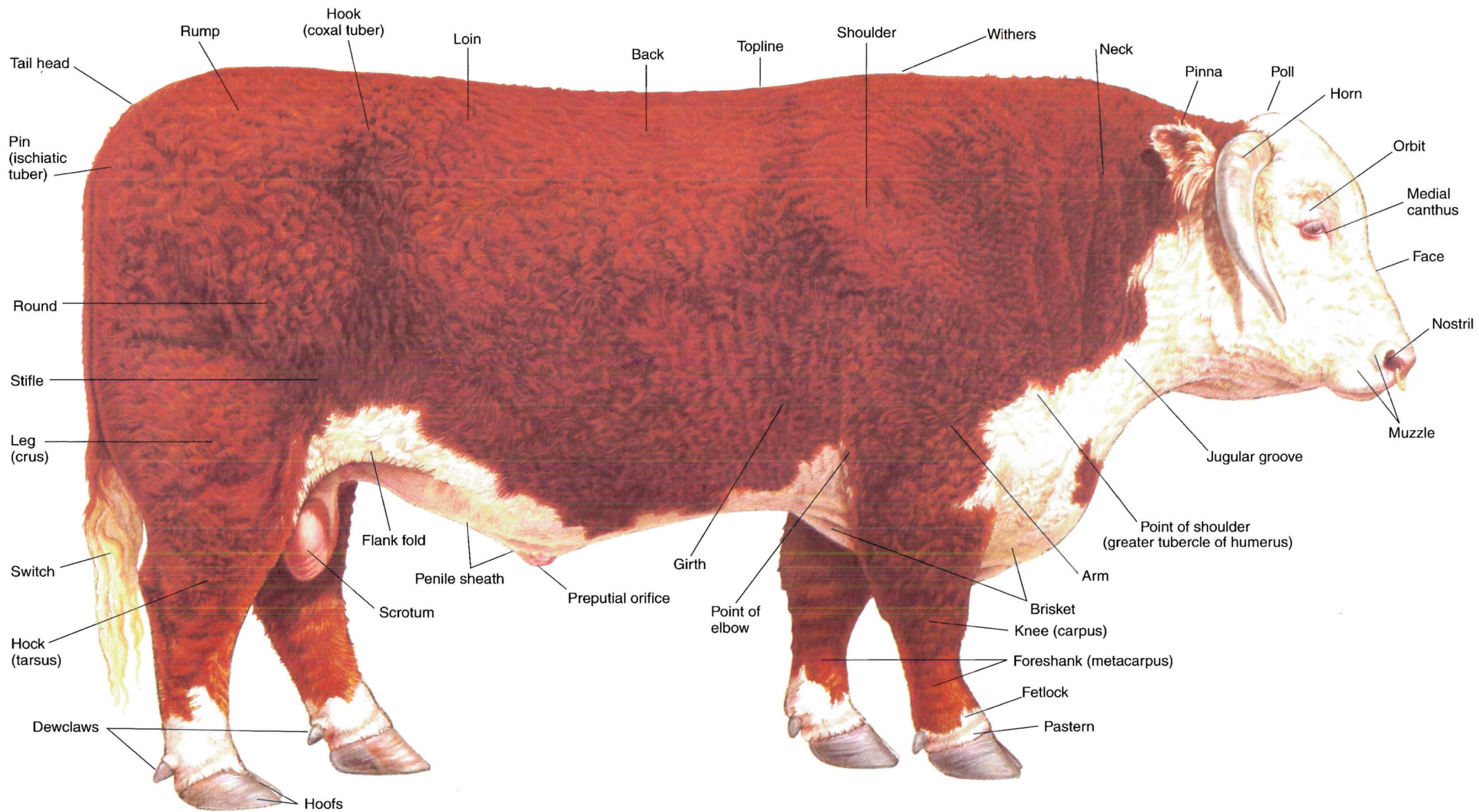


PLATE 2.1 Right lateral view of a beef bull.



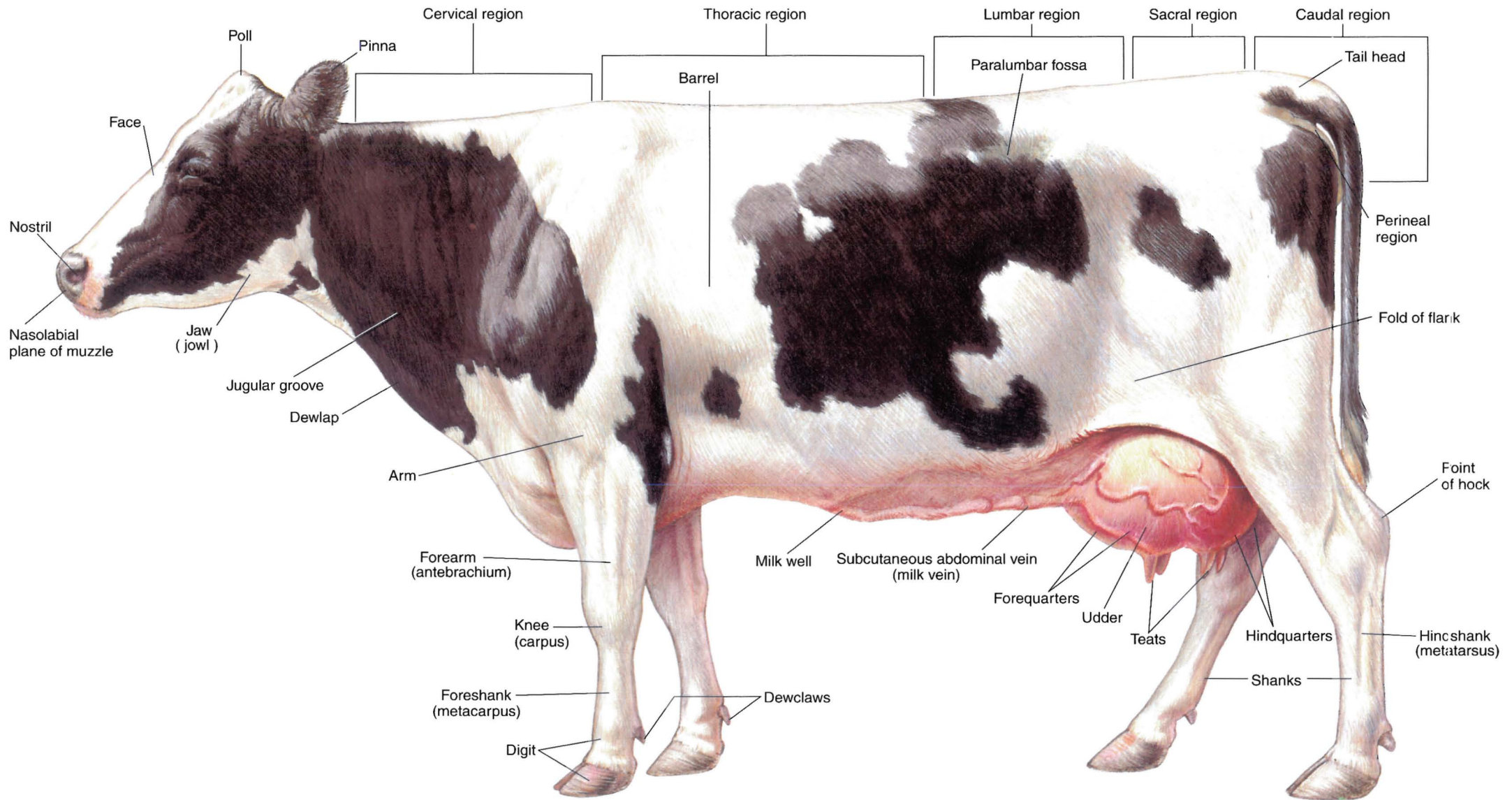


PLATE 2.2 Left lateral view of a dairy cow. Dorsal vertebral regions indicated.

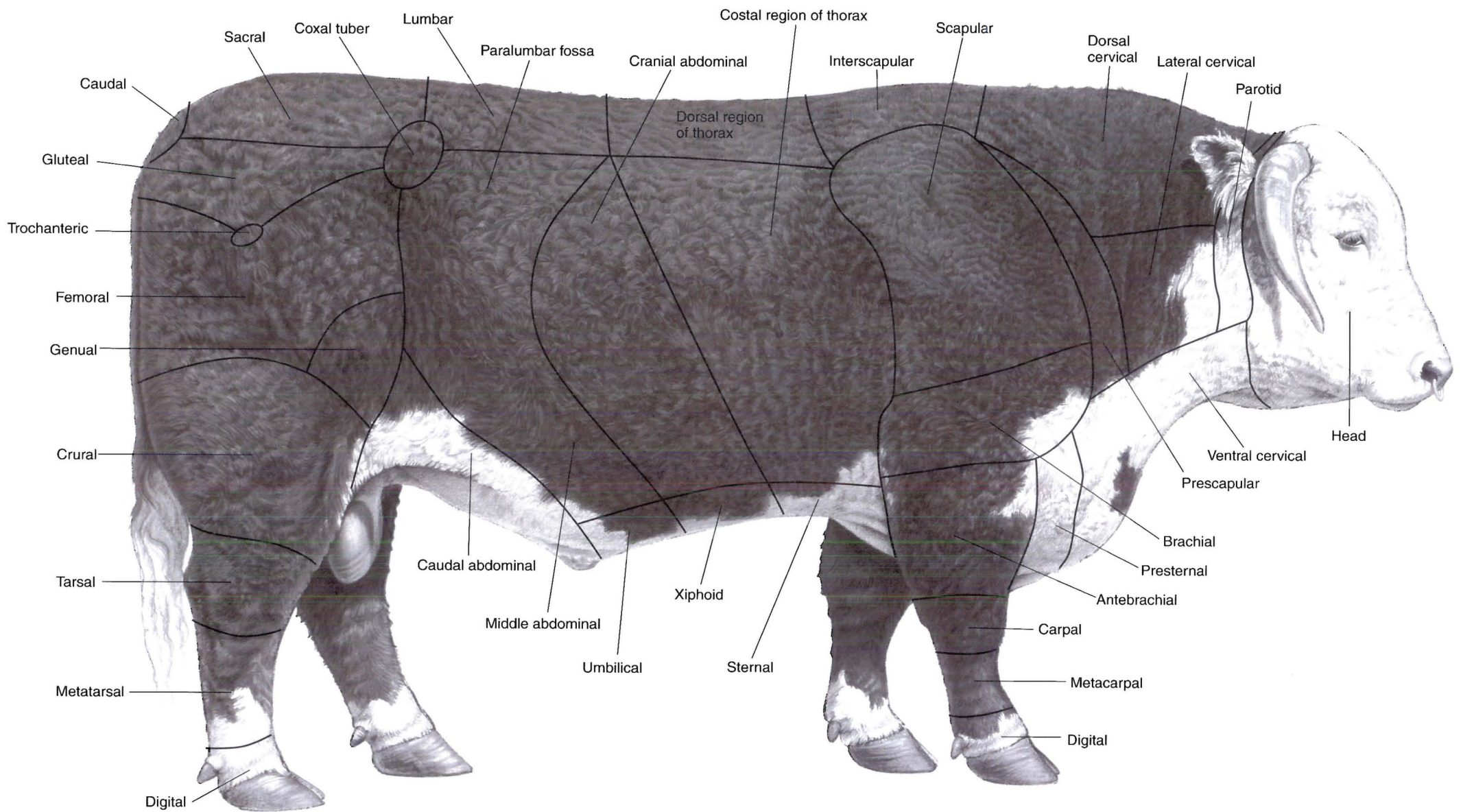
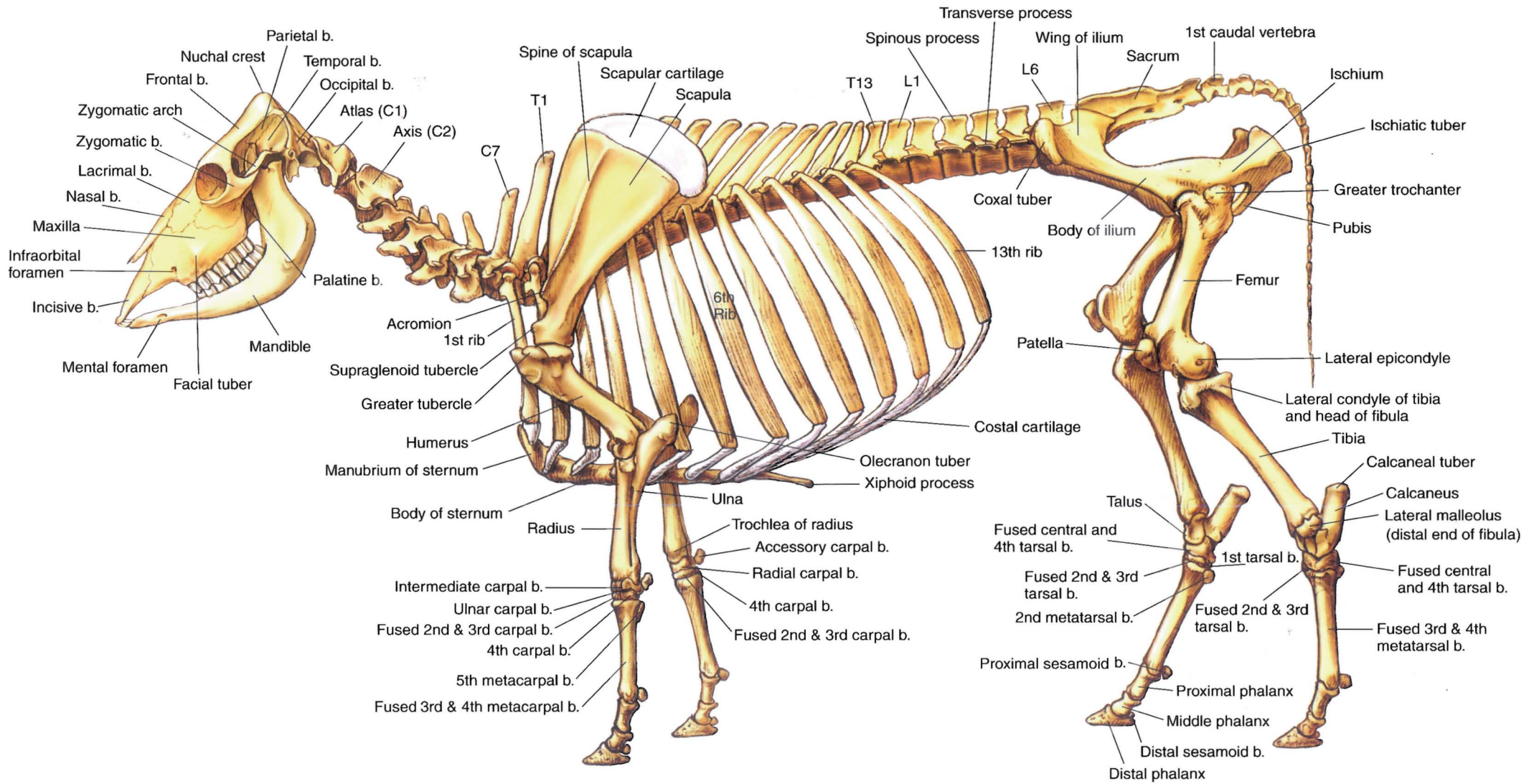


PLATE 2.3 Body regions of the ox. Right lateral view.





**PLATE 2.4** Skeleton of the ox. Left lateral view. C = cervical vertebra, T = thoracic vertebra, L = lumbar vertebra, b = bone

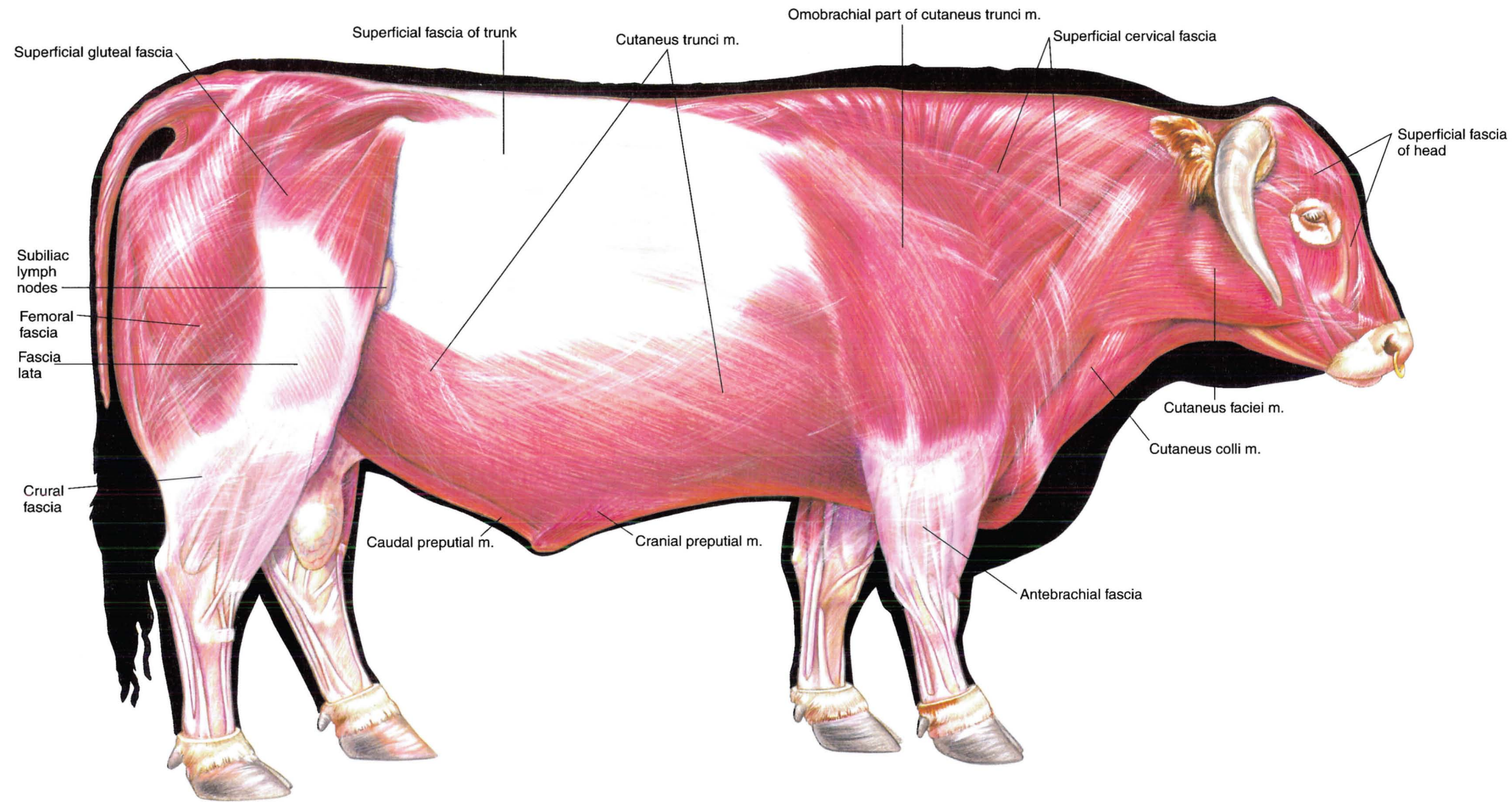
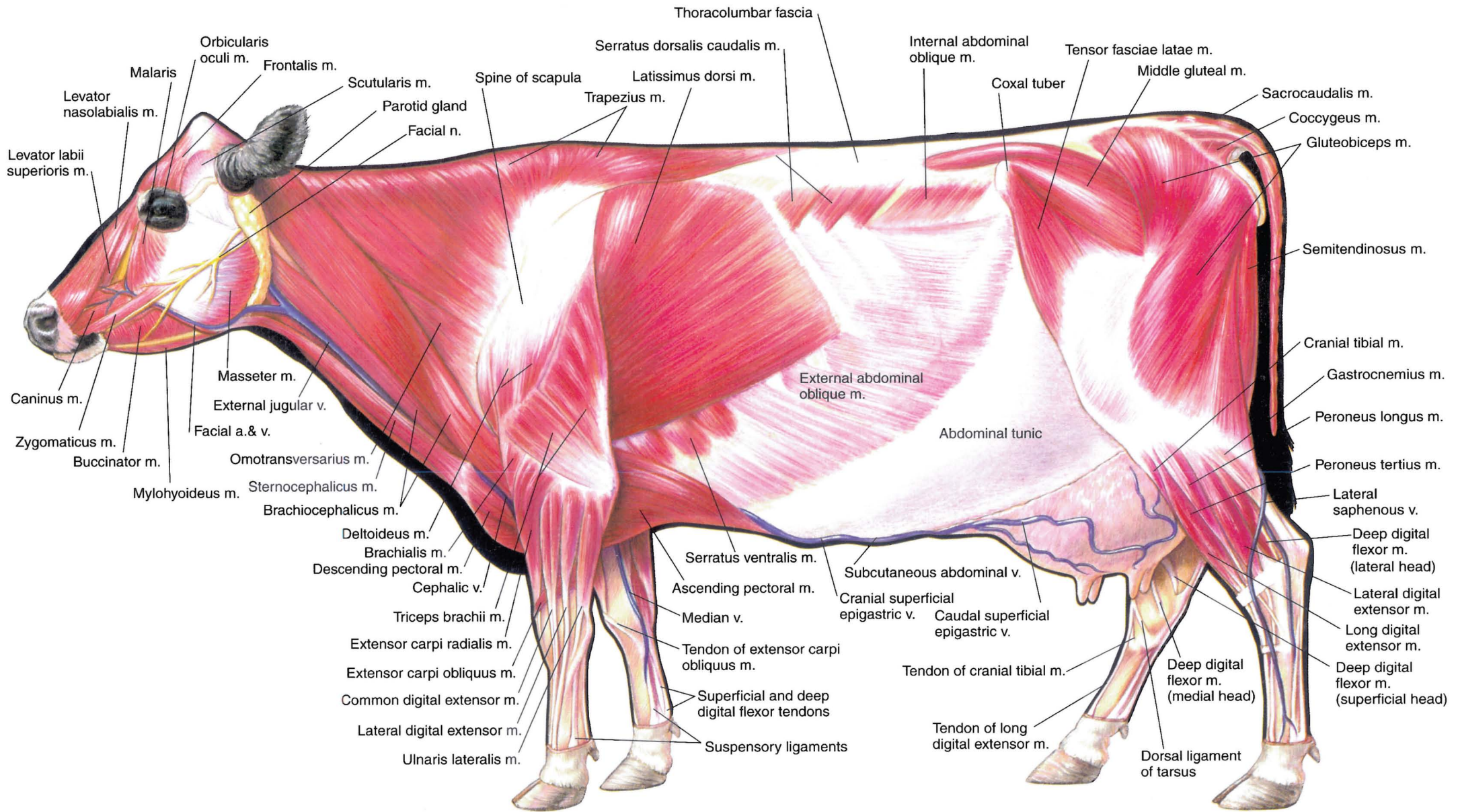


PLATE 2.5 Cutaneous muscles and major fasciae of the bull. Right lateral view. n = nerve, m = muscle





**PLATE 2.6** Superficial muscles and veins of the cow. Left lateral view.  
 m = muscle, v = vein, a = artery, n = nerve



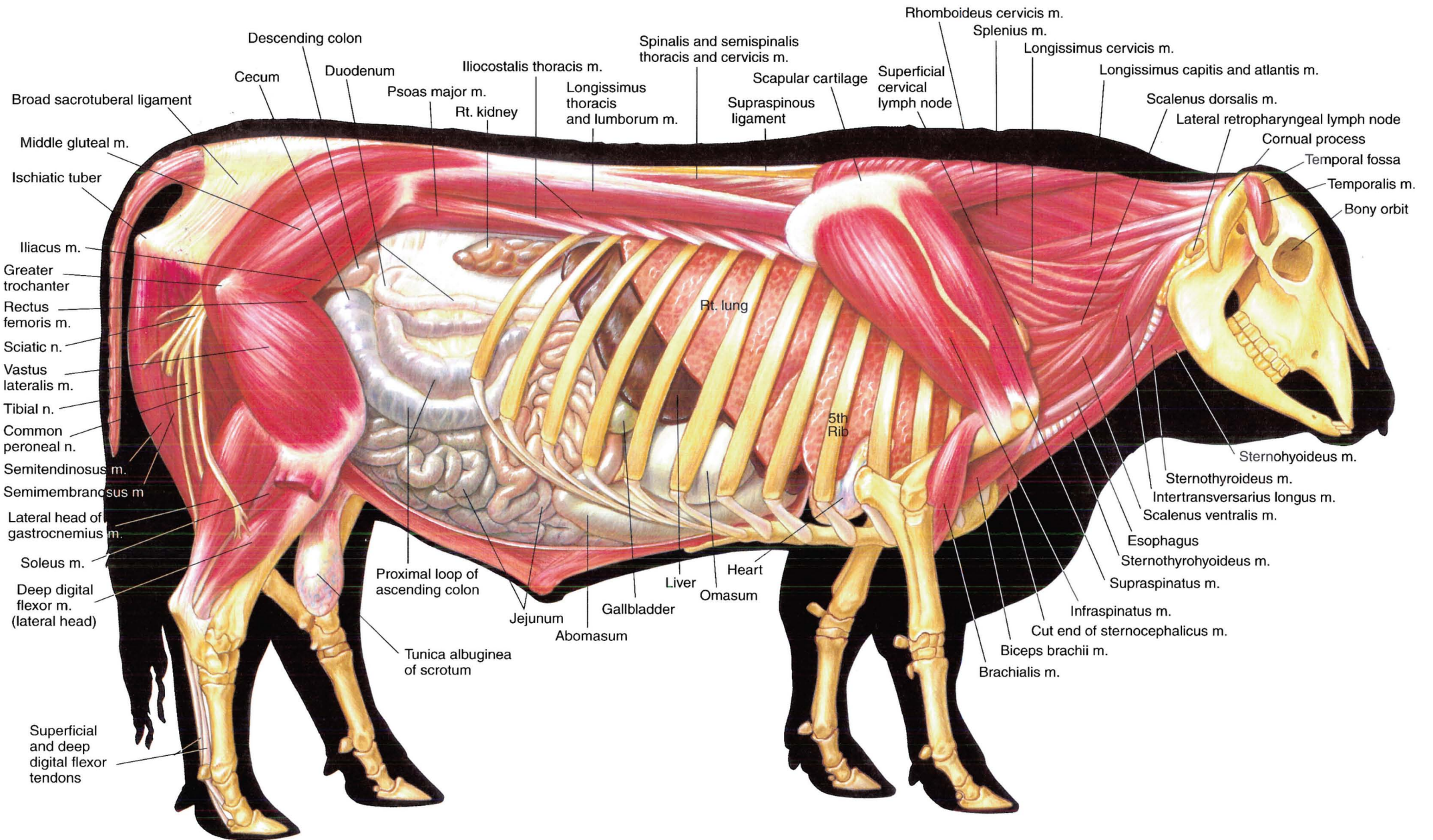
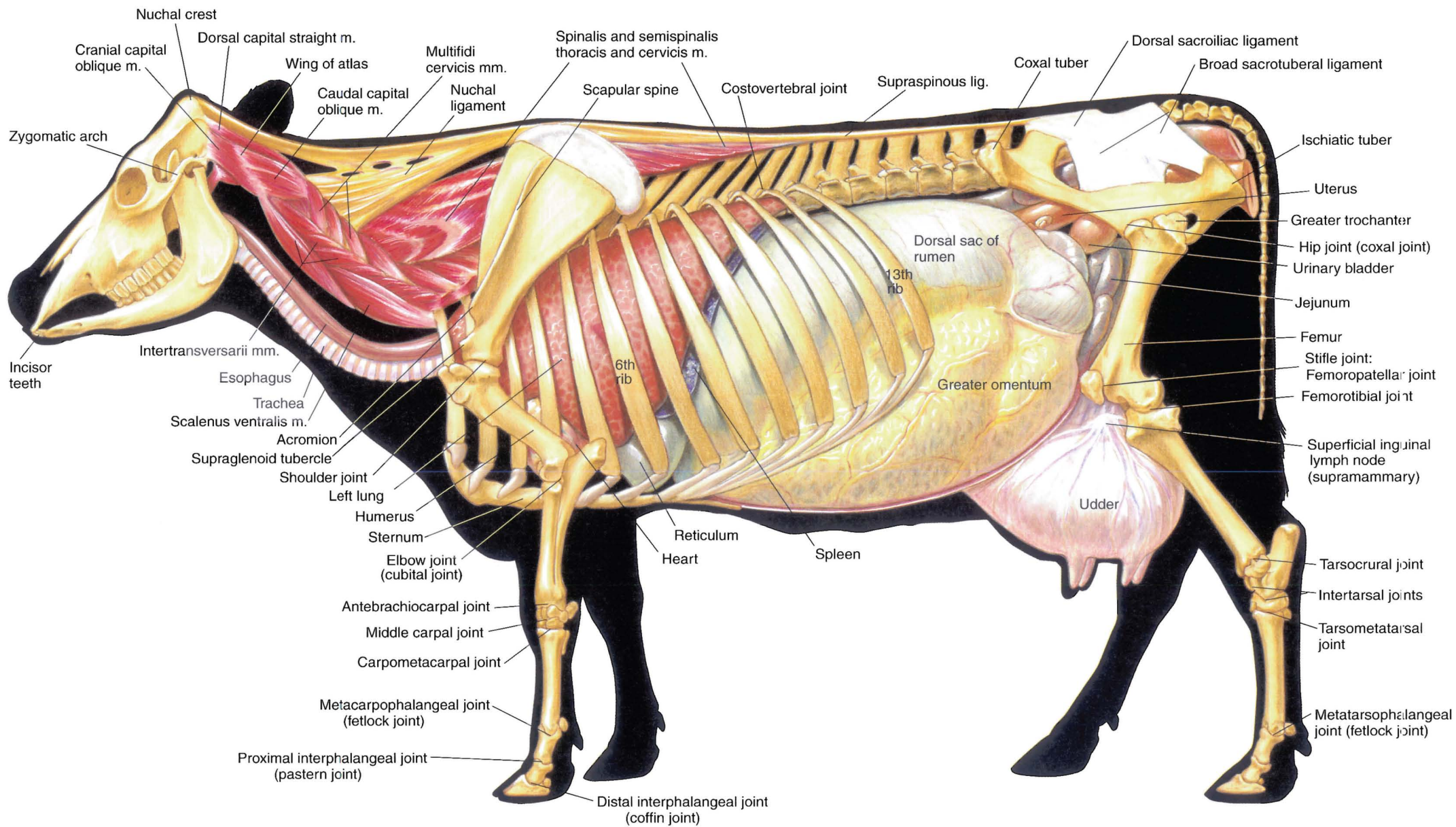
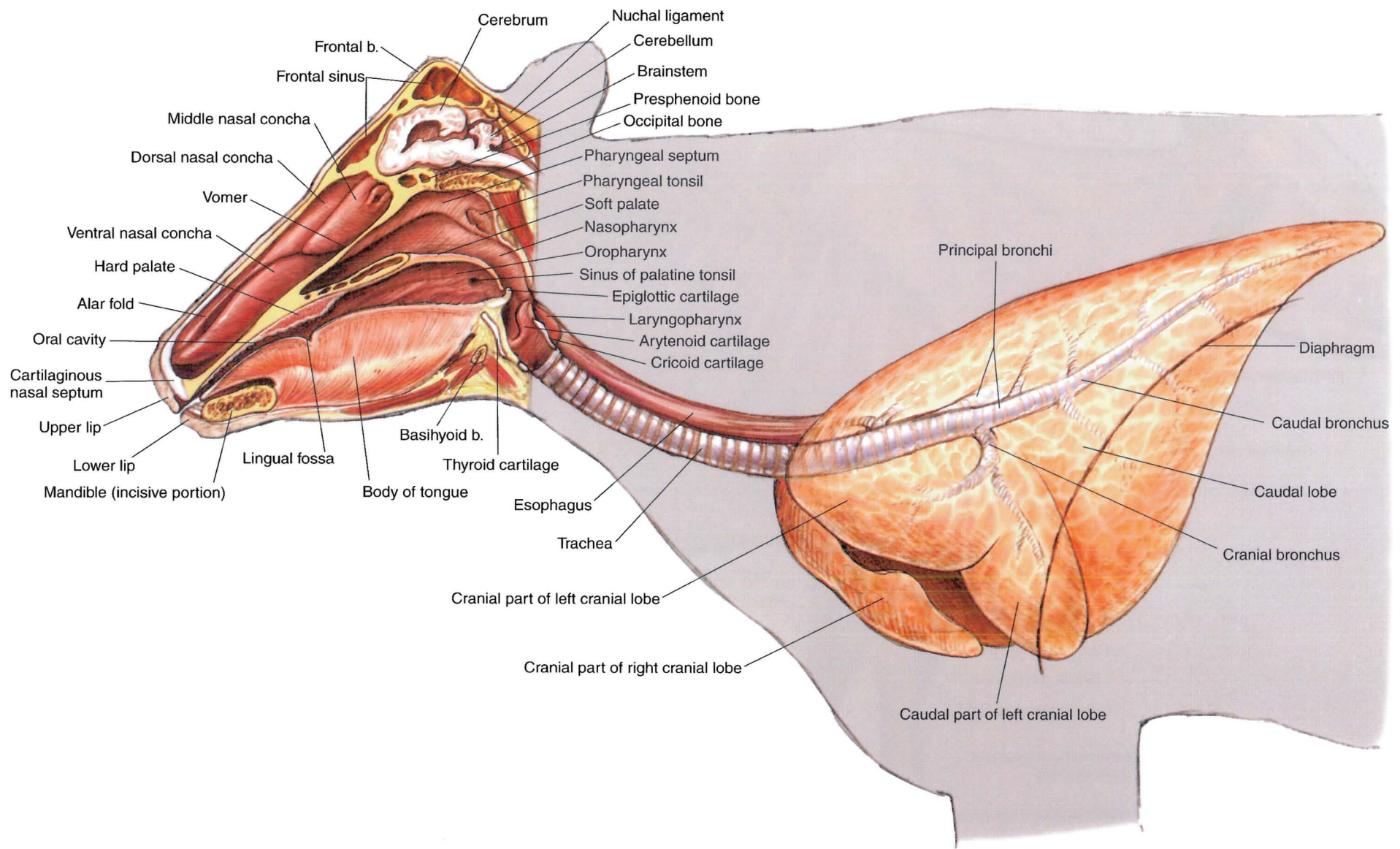


PLATE 2.7 Deep cervical muscles and *in situ* viscera of the bull. Greater omentum removed. Right lateral view. m = muscle, n = nerve





**PLATE 2.8** Deep cervical muscles, major joints, *in situ* viscera, and udder of the cow.  
 Left lateral view. m = muscle, lig = ligament



**PLATE 2.9** Median section of the head and left lateral view of the respiratory system of the ox. b = bone



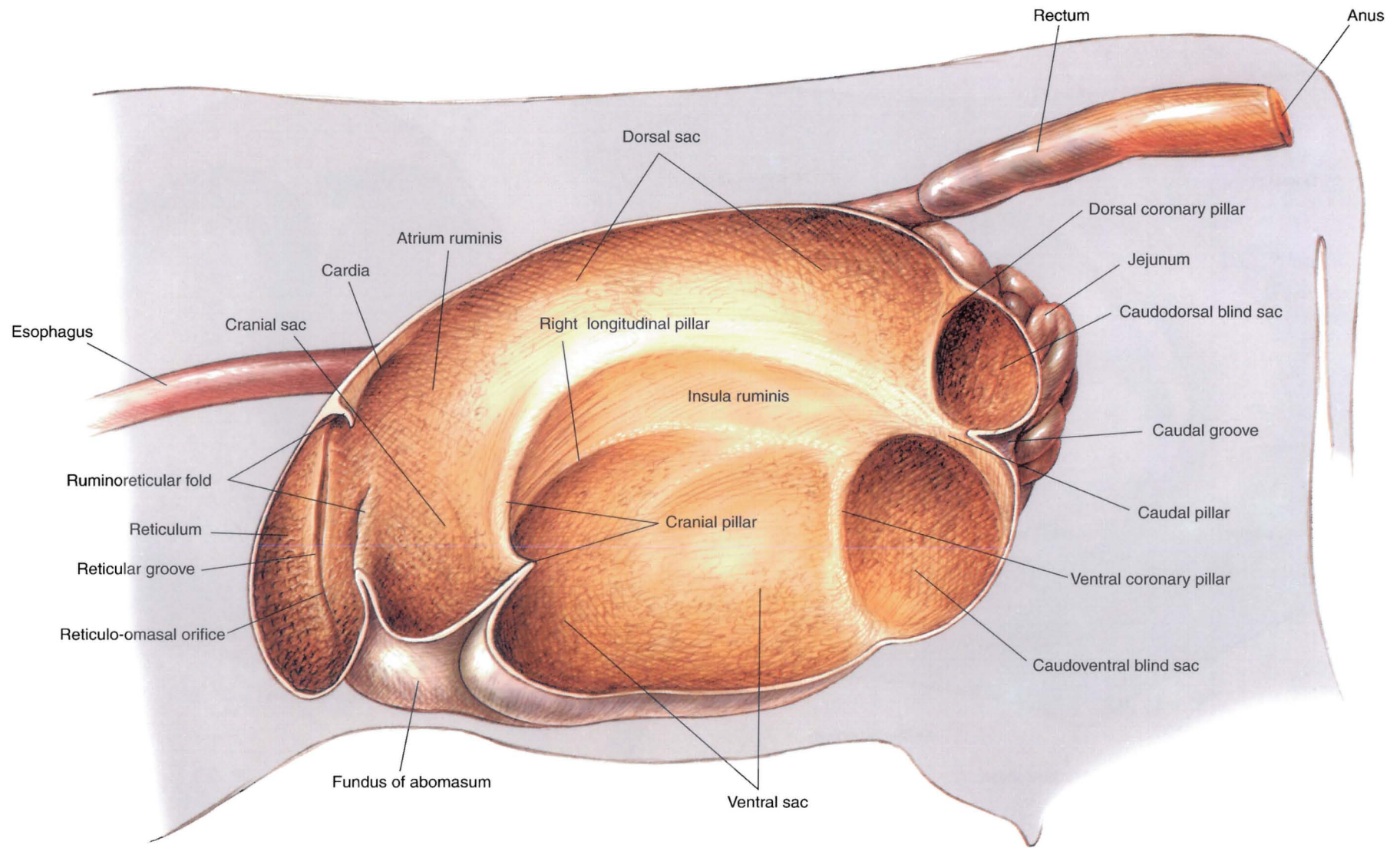
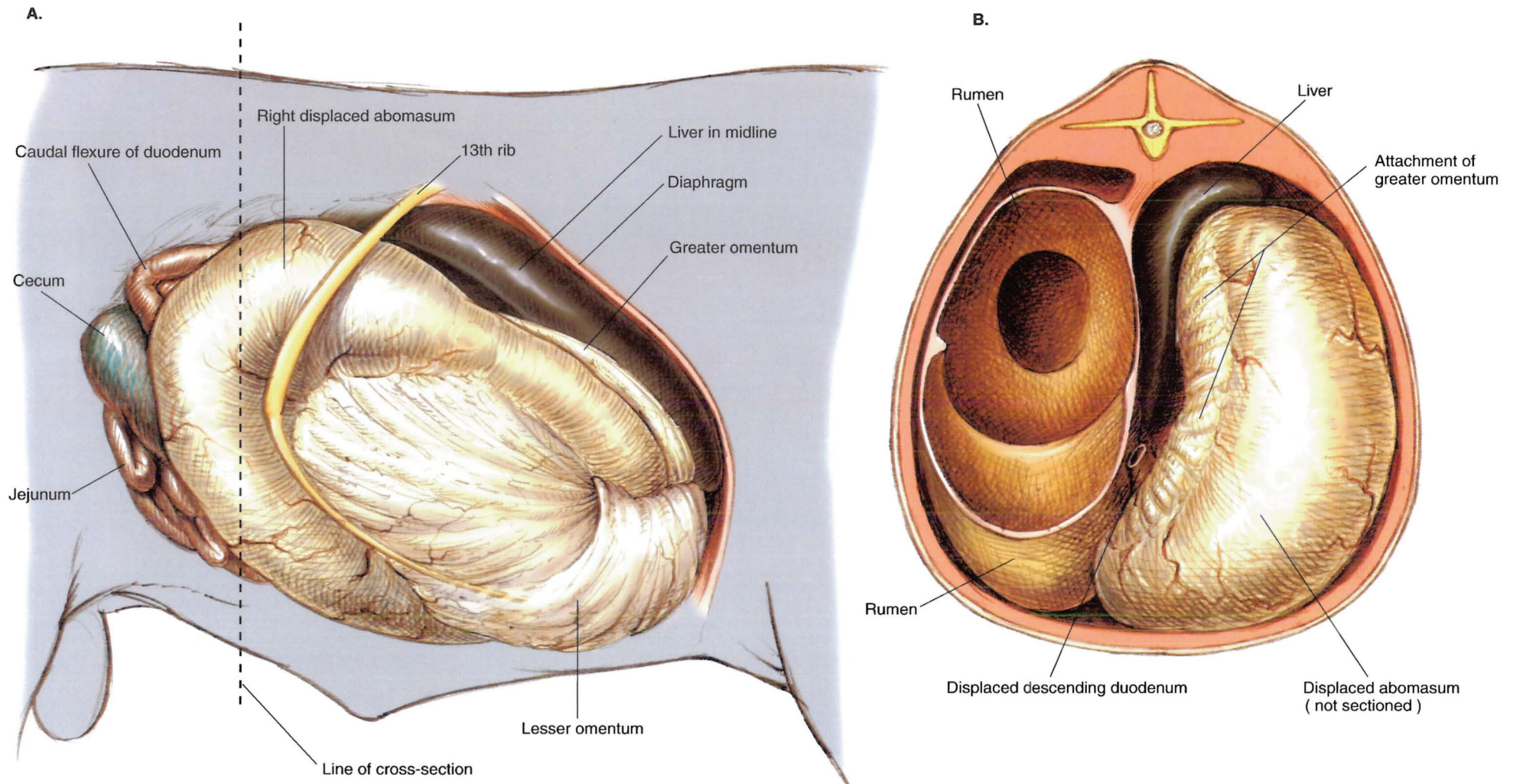
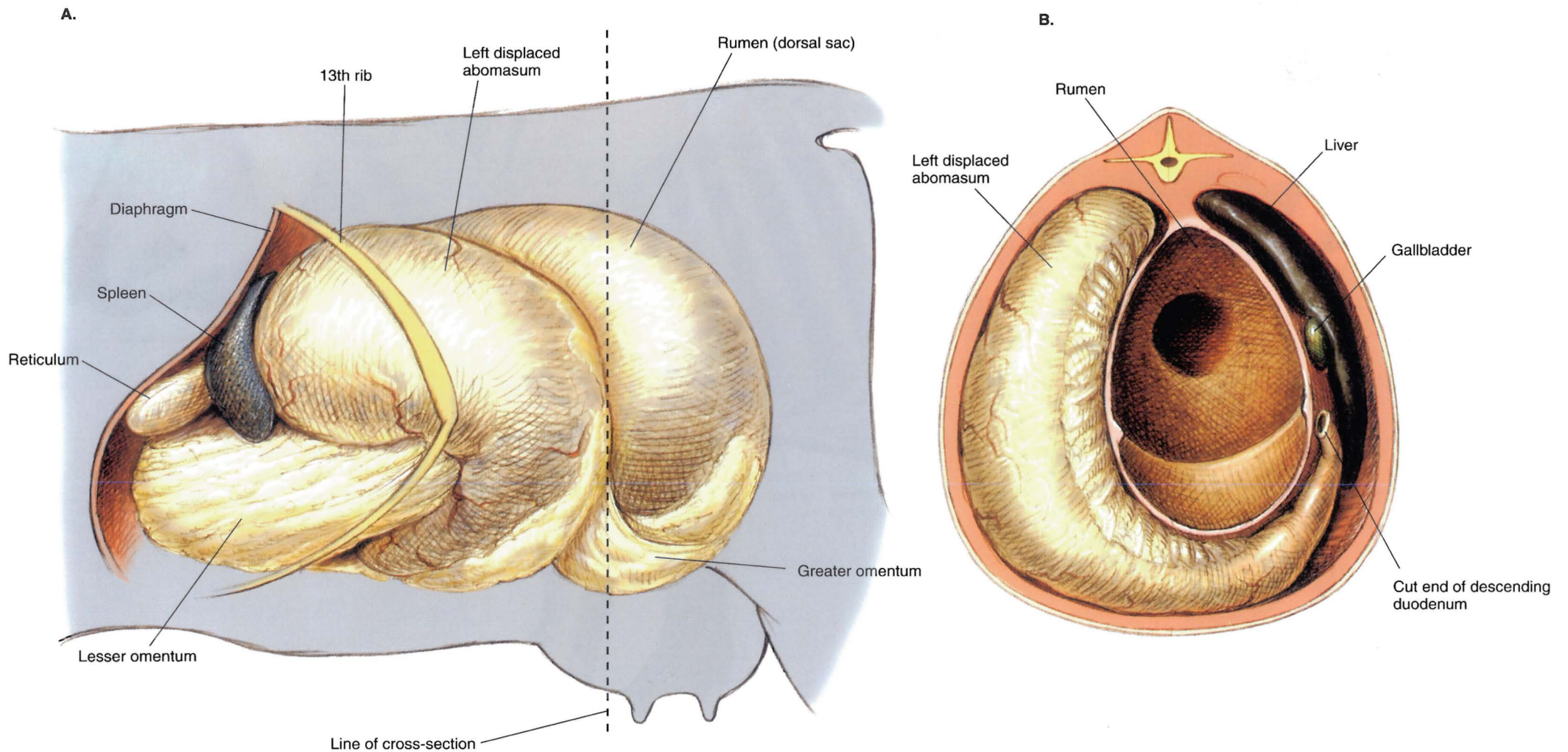


PLATE 2.10 Interior of the rumen and reticulum of the cow. Left lateral view.



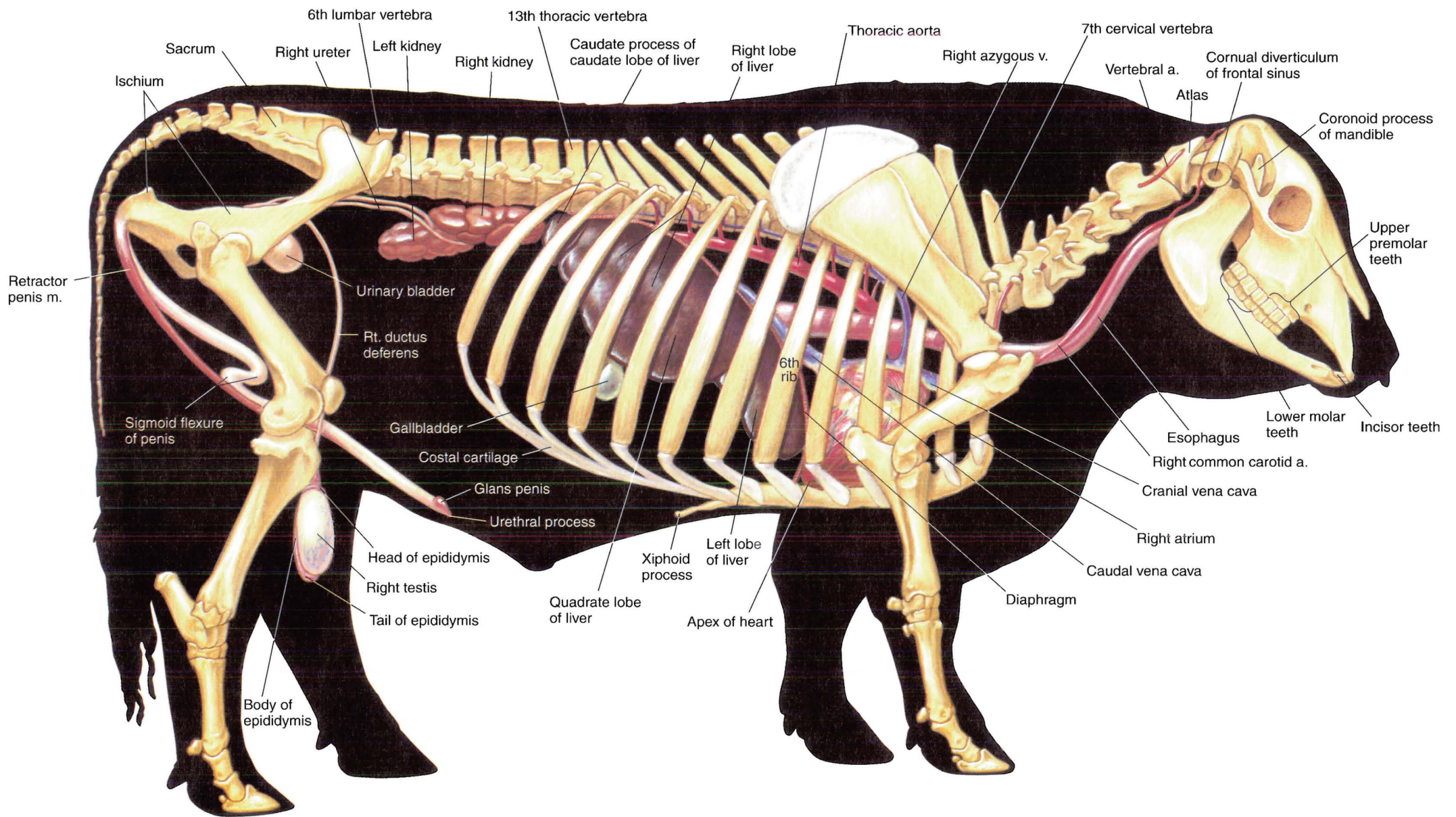
**PLATE 2.11** Clinical condition: Right volvulus of the abomasum in a bull. **A.** Right lateral view. **B.** Cross-section. Caudocranial view. This problem occurs in cattle of varying types and ages. The long axis of the abomasum rotates dorsad and caudad, moving the greater curvature of the abomasum counterclockwise and toward the pelvis. This abnormal configuration displaces the liver mediad and draws the pyloric antrum and duodenum around the cranial aspect of the omasum.





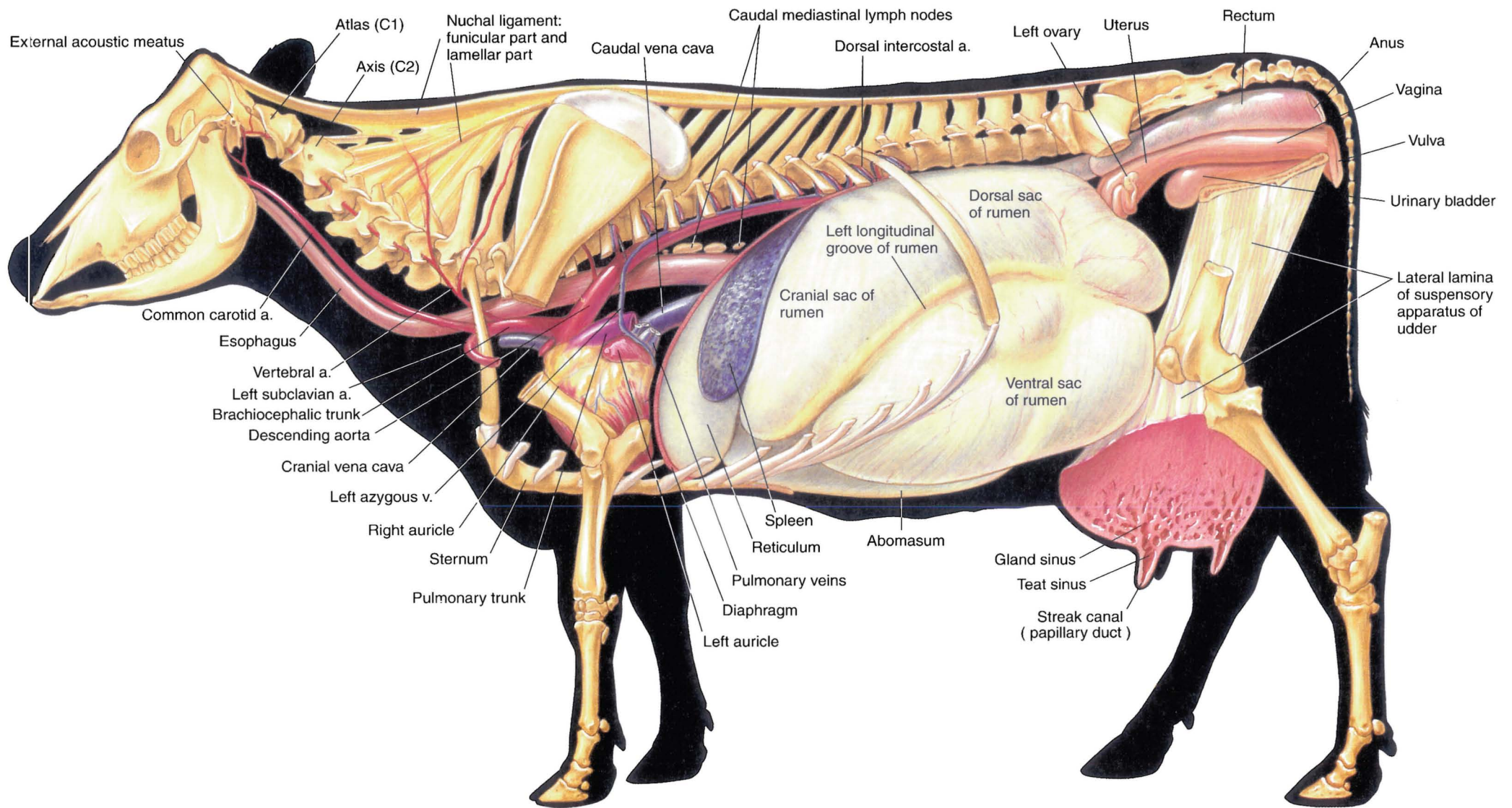
**PLATE 2.12** Clinical condition: Left displacement of the abomasum in a cow. **A.** Left lateral view. **B.** Cross-section. Caudocranial view. This problem can occur commonly in lactating dairy cattle during the first month postpartum and less frequently during other times or in other types of cattle. The gas-filled abomasum moves to the left and dorsad in the abdomen. It displaces the partially filled rumen mediad and distorts the normal position and orientation of the reticulum, omasum, and cranial rumen.





**PLATE 2.13** Reproductive organs, urinary organs, liver, heart, and adjacent major vessels related to the skeleton of the bull. Stomach, intestines, and lungs are removed. Right lateral view. a = artery, v = vein, m = muscle





**PLATE 2.14** Heart and adjacent major vessels, abdominal and pelvic viscera, and udder (mammary glands) of the cow. Lungs and intestines are removed. Left lateral view. v = vein, a = artery



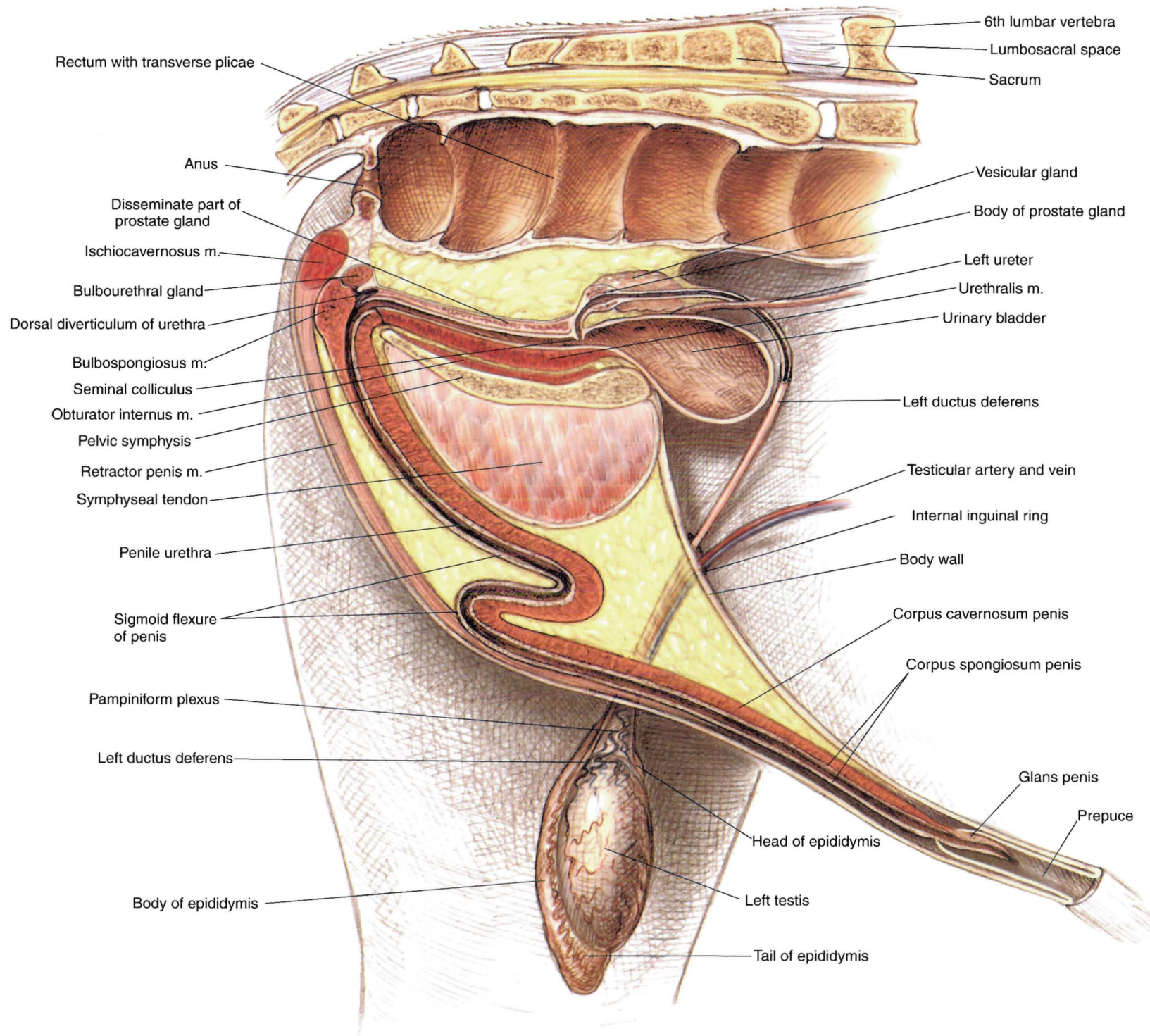
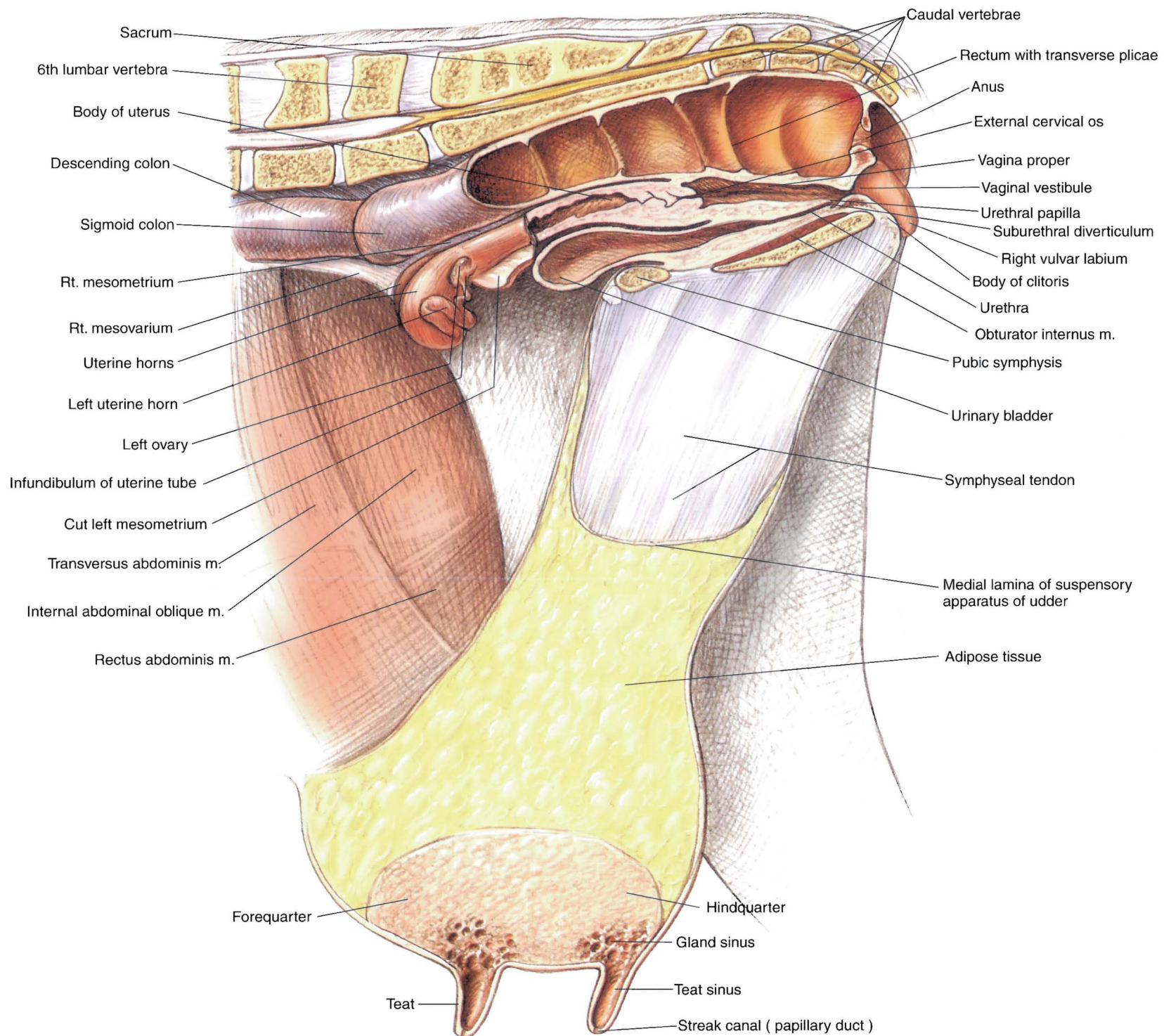


PLATE 2.15 Relations of the reproductive organs of the bull. Median section. m = muscle





**PLATE 2.16** Relations of the reproductive organs of the cow. Median section. m = muscle



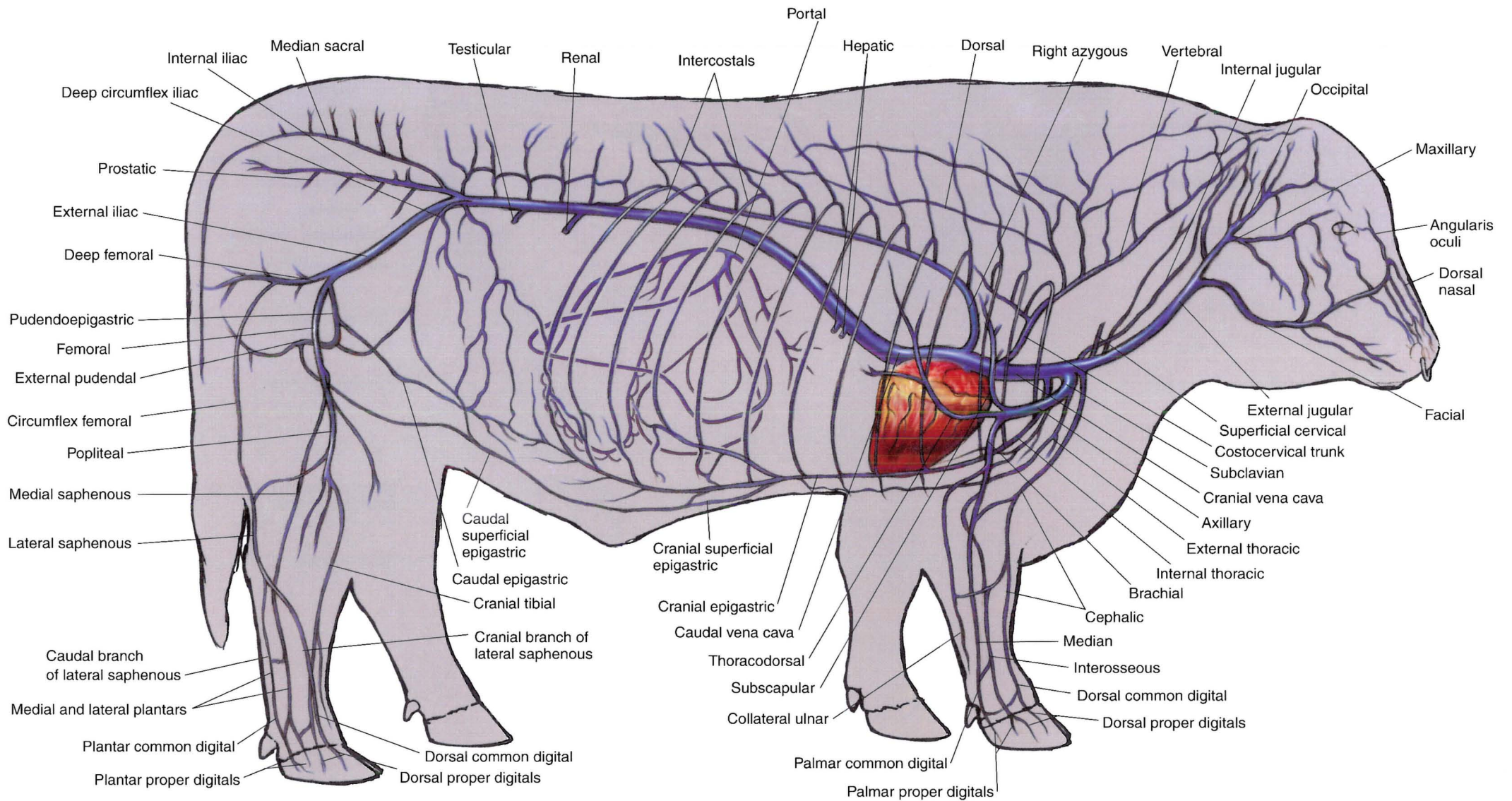


PLATE 2.17 Major veins of the bull. Right lateral view.



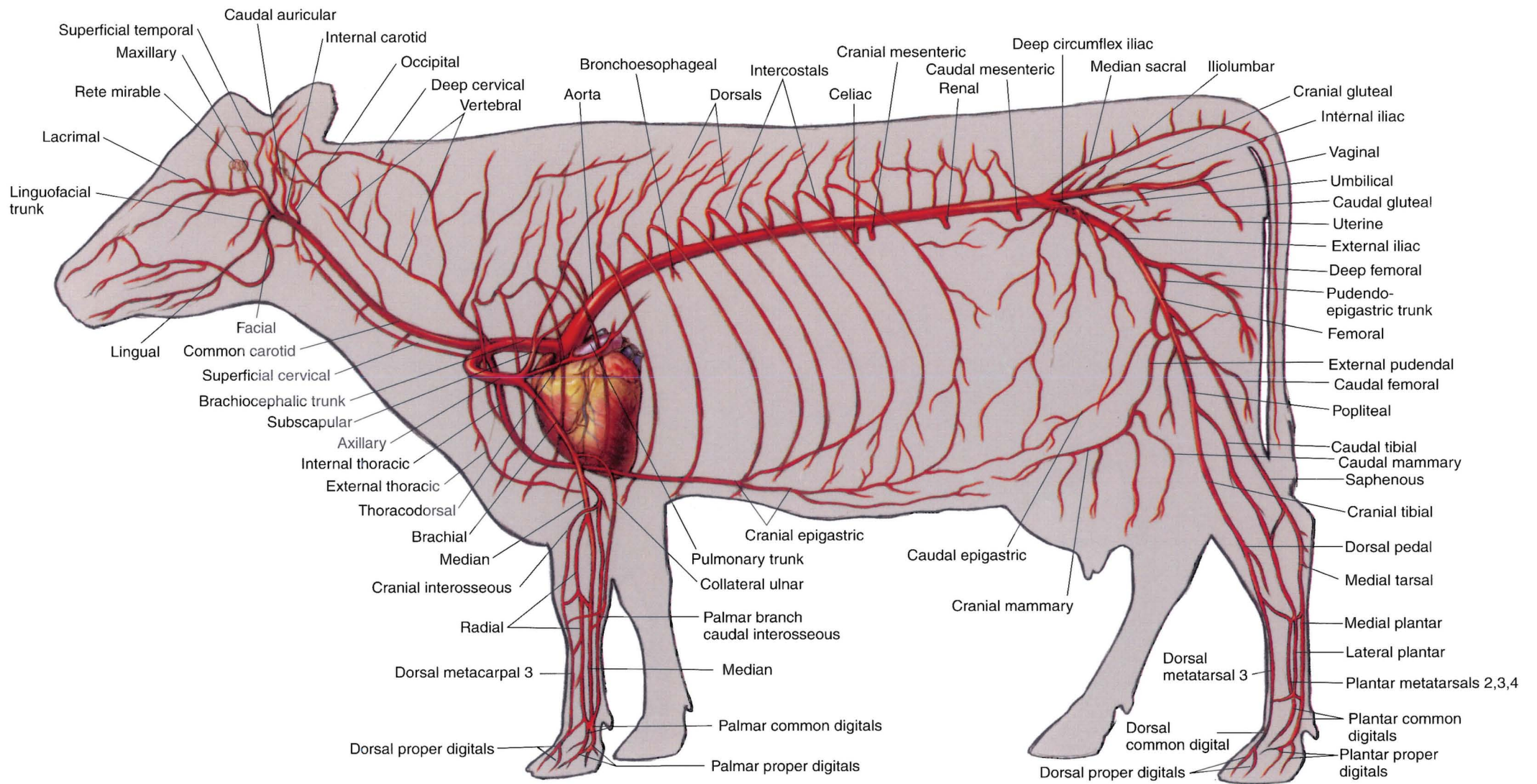
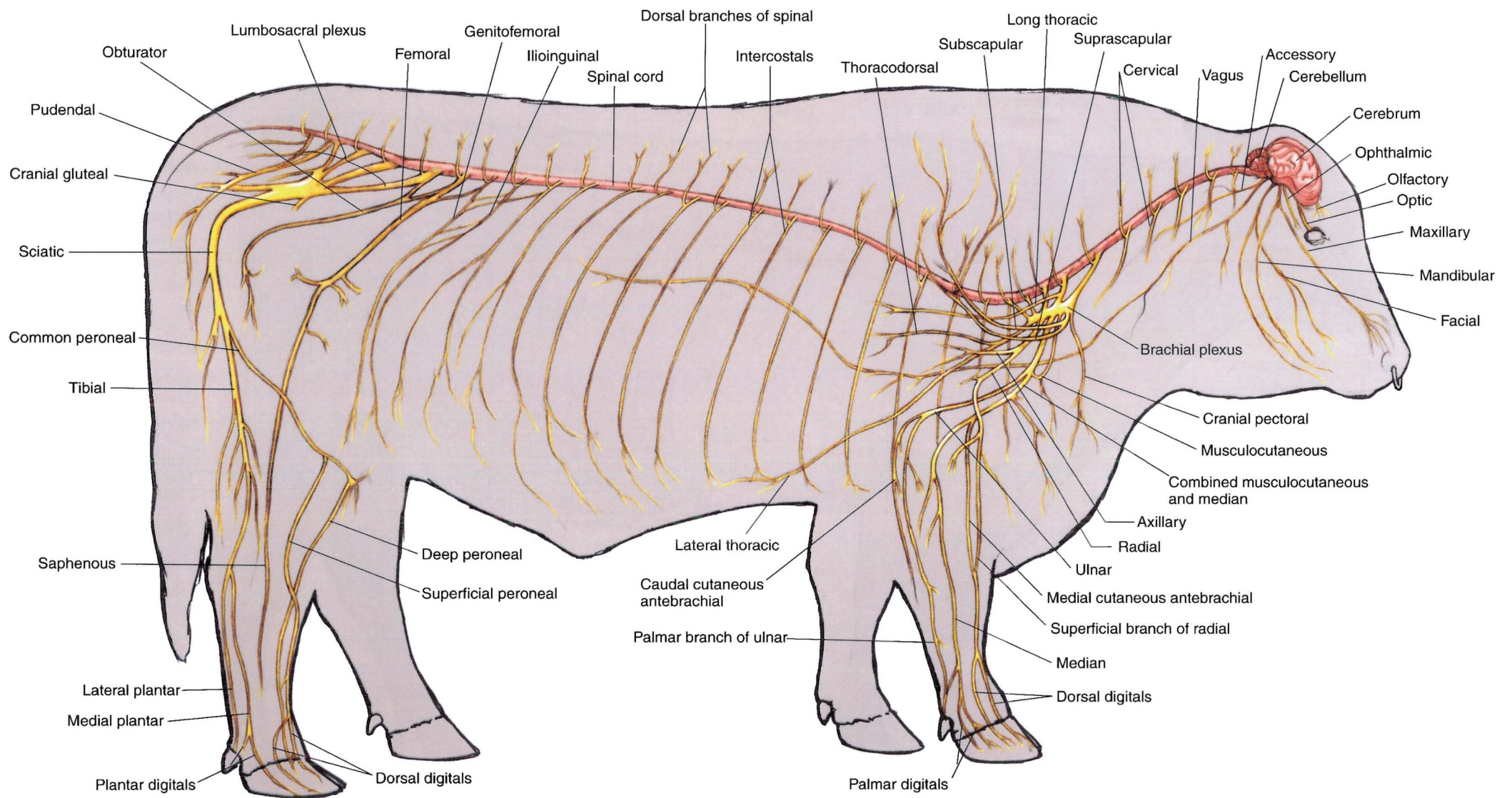


PLATE 2.18 Major arteries of the cow. Left lateral view.



**PLATE 2.19** Central nervous system and principal nerves of the peripheral nervous system of the bull. Right lateral view.



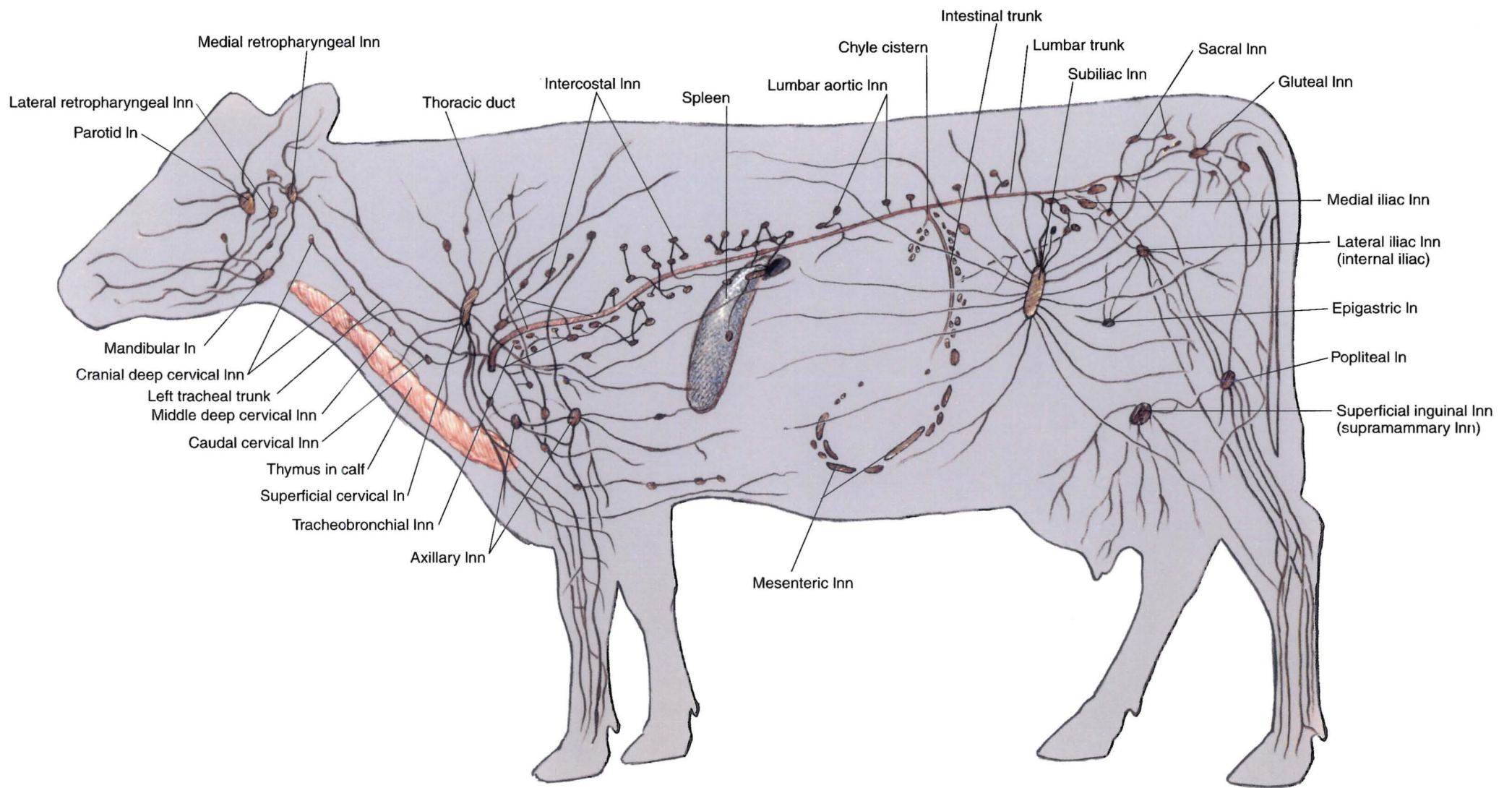



PLATE 2.20 Significant lymphatic organs of the cow. Left lateral view. In = lymph node





# SECTION 3 THE SHEEP (*Ovis aries*)

## PLATES



- 3.1 Right lateral view of a ram.
- 3.2 Left lateral view of an ewe.
- 3.3 Carcass cuts of the lamb.
- 3.4 Skeleton of the sheep.
- 3.5 Cutaneous muscles and major fasciae of the ram.
- 3.6 Superficial muscles and veins of the ewe.
- 3.7 Deep cervical muscles and *in situ* viscera of the ram.
- 3.8 Deep cervical muscles, *in situ* viscera, skeleton, and major joints of the ewe.
- 3.9 Dissection of the parotid region and cross-section of the neck of the sheep.
- 3.10 A. Location of the left flank incision.  
B. Cross-section through the left abdominal wall and subjacent ruminal wall.
- 3.11 Reproductive organs, urinary organs, esophagus and stomach, heart, and adjacent major vessels related to the skeleton of the ram.
- 3.12 Reproductive organs, urinary organs, heart, and adjacent major vessels, esophagus and stomach of the ewe.
- 3.13 Relations of the reproductive organs of the ram.
- 3.14 Relations of the reproductive organs of the ewe.
- 3.15 Penis of the ram.
- 3.16 Isolated reproductive organs of the ewe.



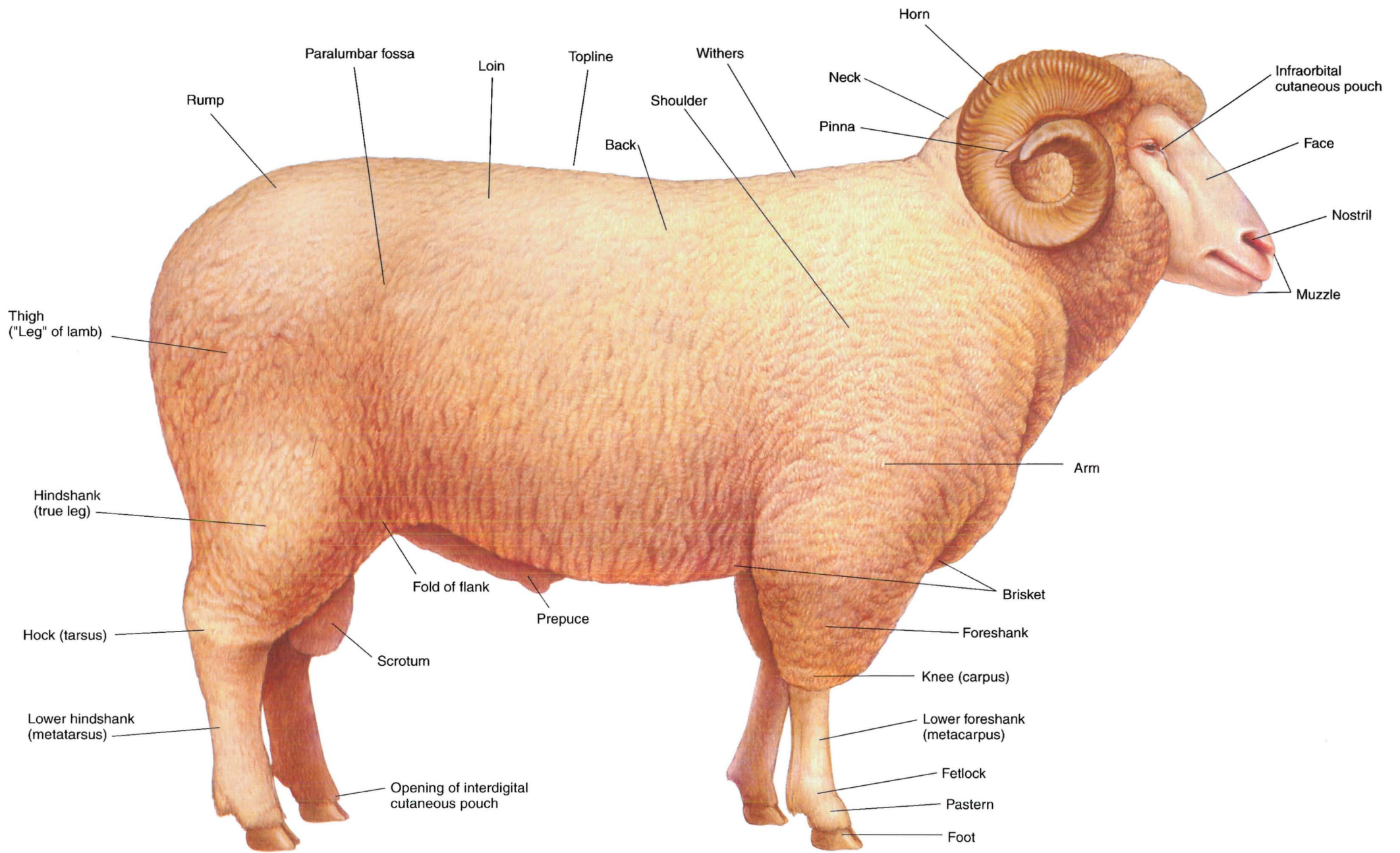


PLATE 3.1 Right lateral view of a ram.



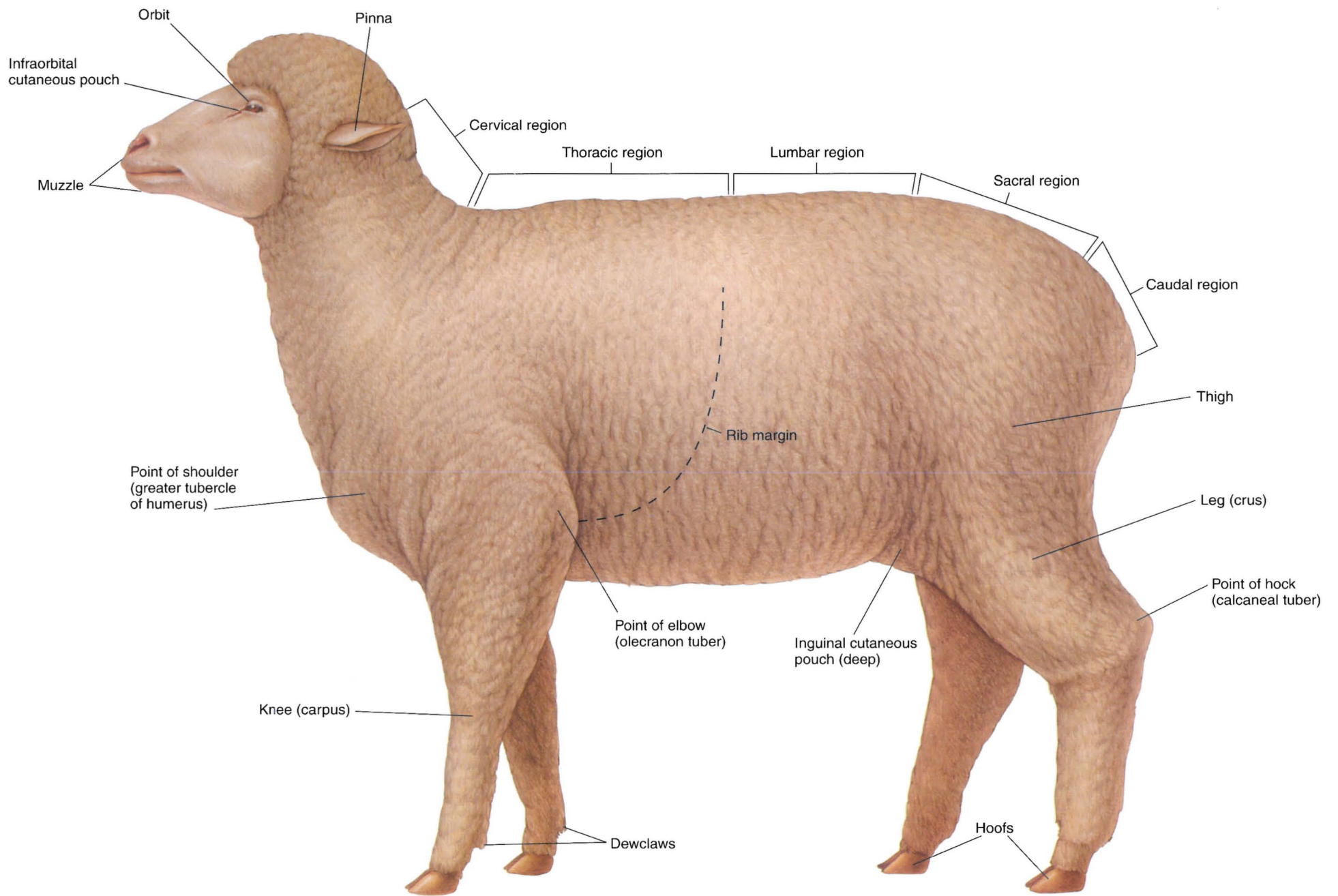


PLATE 3.2 Left lateral view of an ewe.

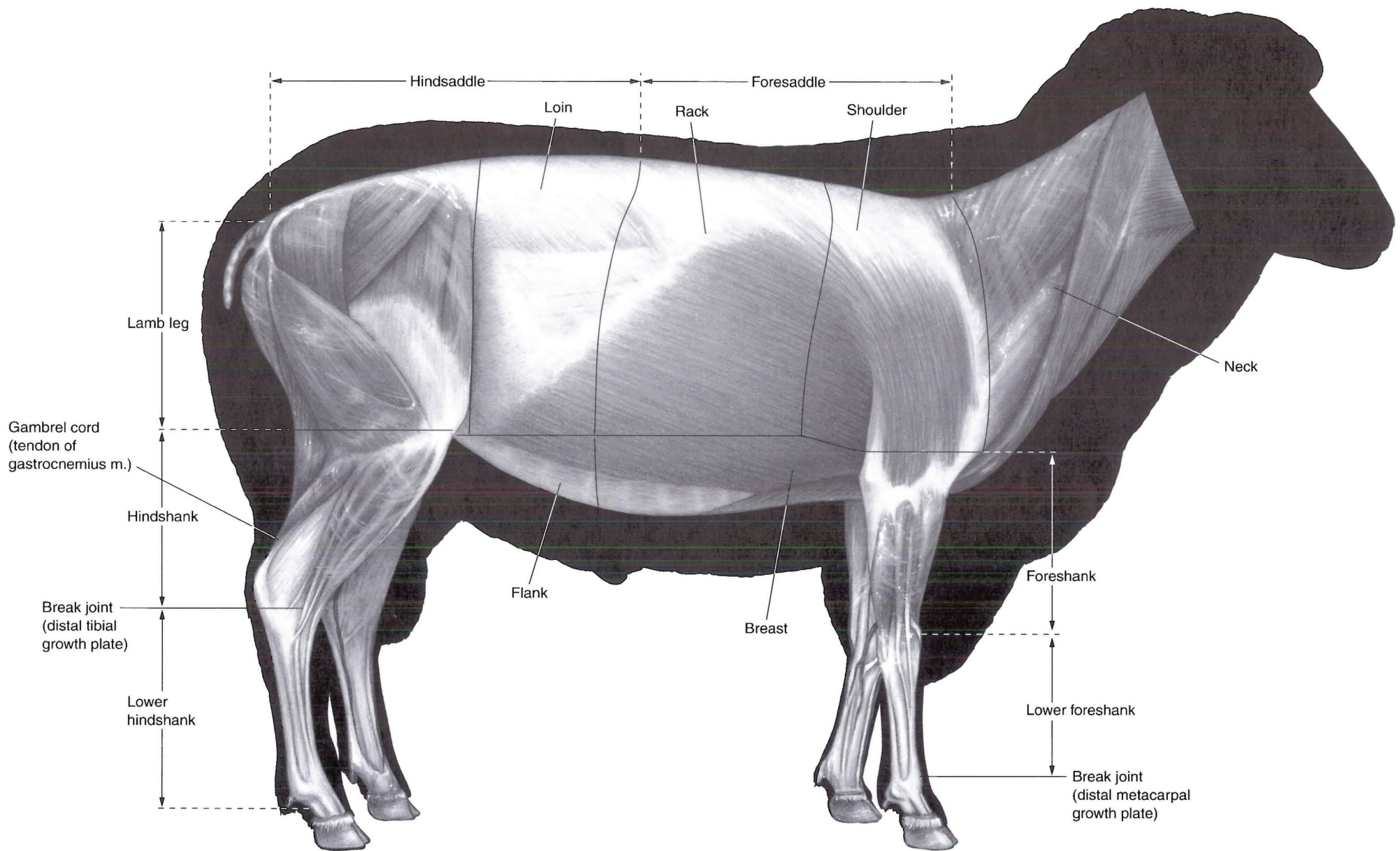
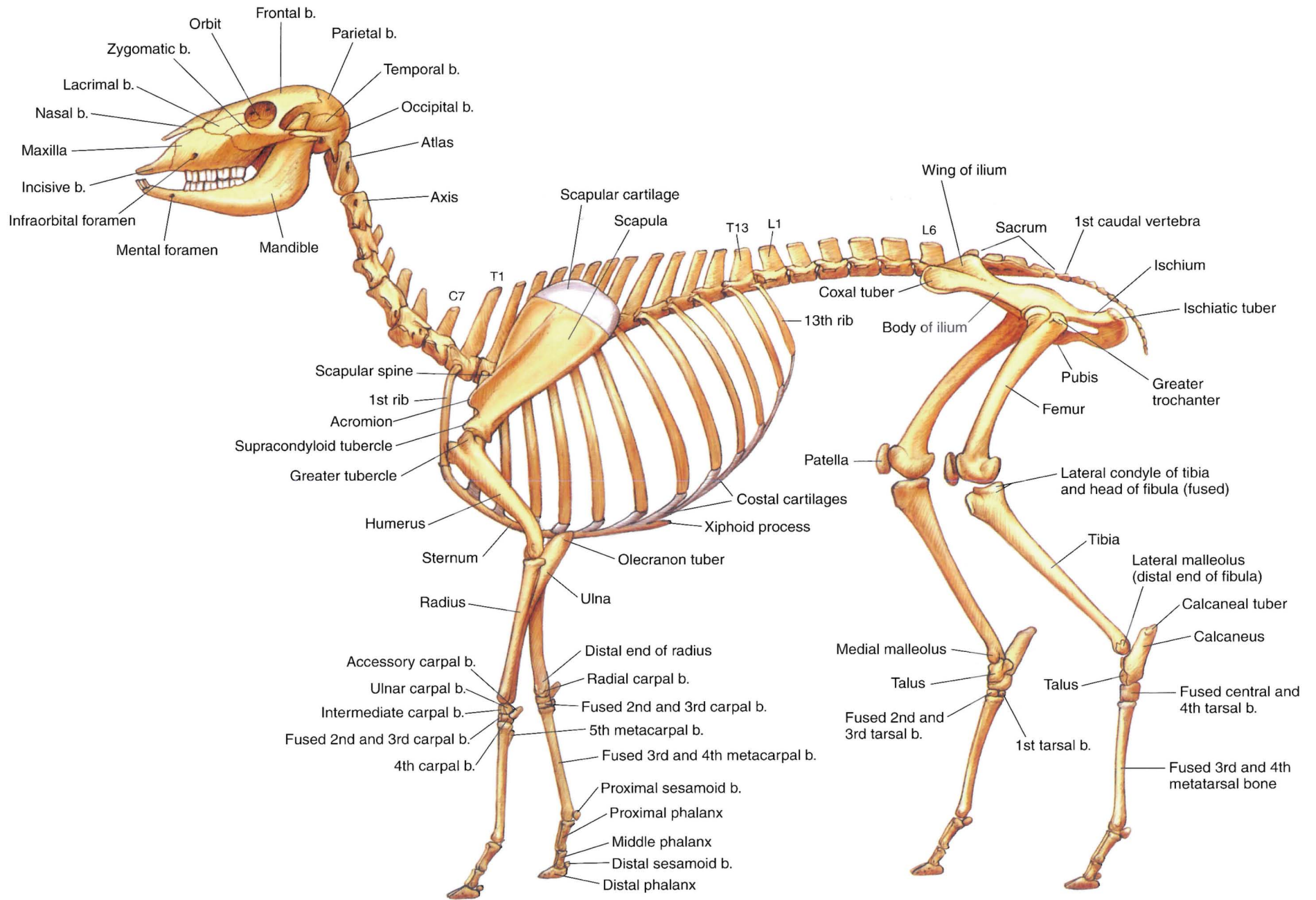
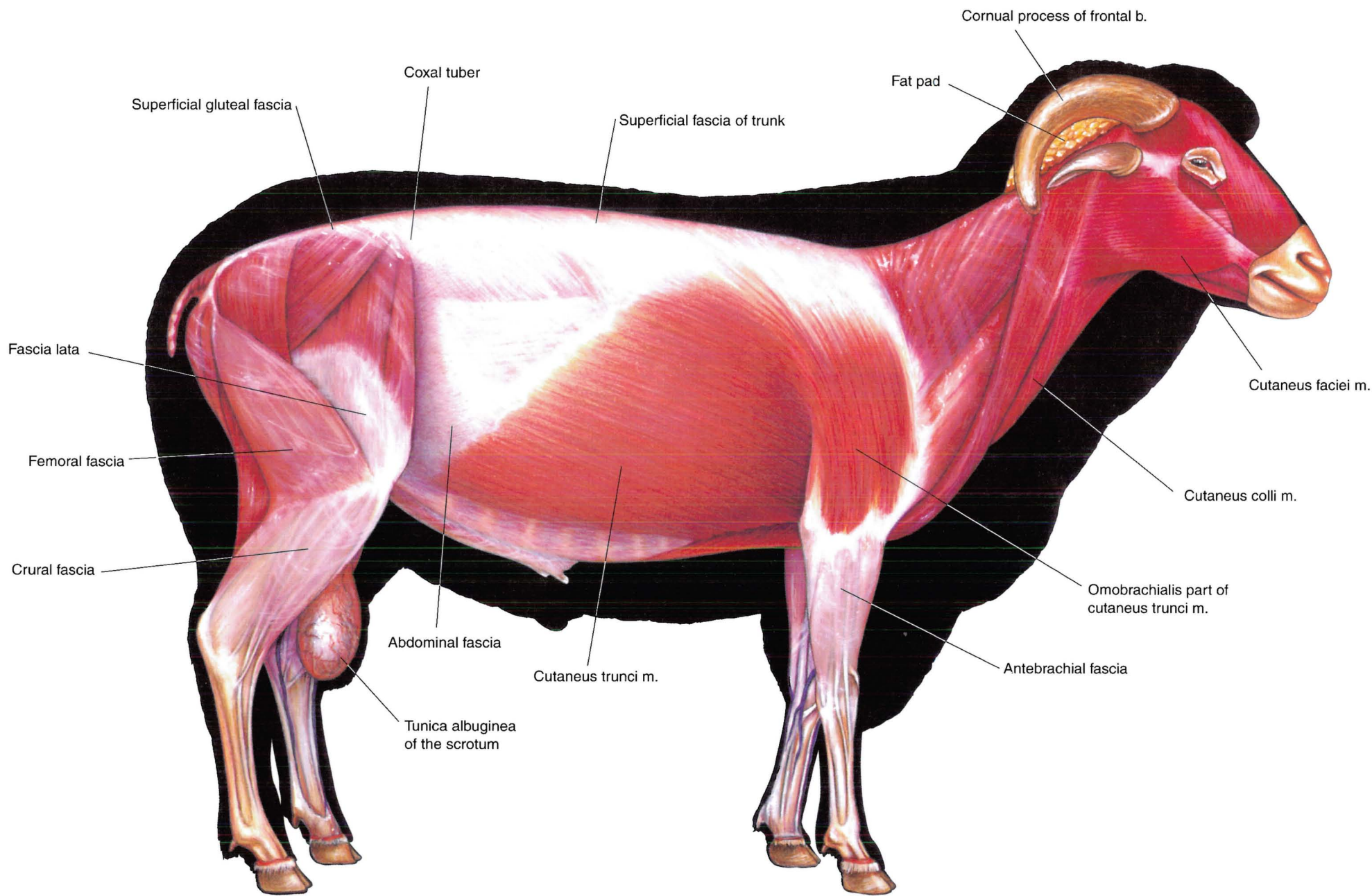


PLATE 3.3 Carcass cuts of the lamb. m = muscle





**PLATE 3.4** Skeleton of the sheep. b = bone, C = cervical vertebra, T = thoracic vertebra, L = lumbar vertebra



**PLATE 3.5** Cutaneous muscles and major fasciae of the ram. Right lateral view. m = muscle, b = bone



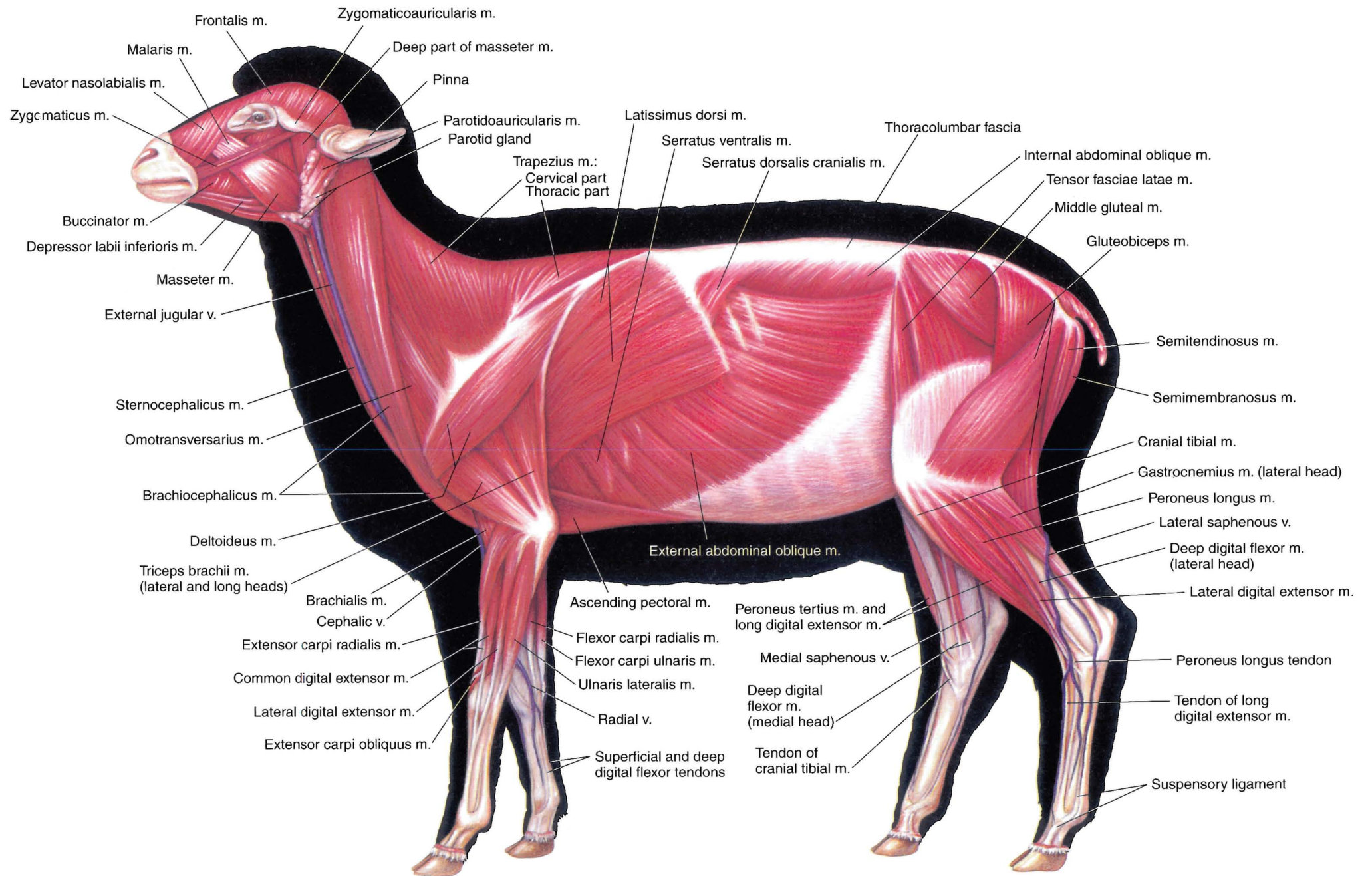


PLATE 3.6 Superficial muscles and veins of the ewe. Left lateral view. m = muscle, v = vein



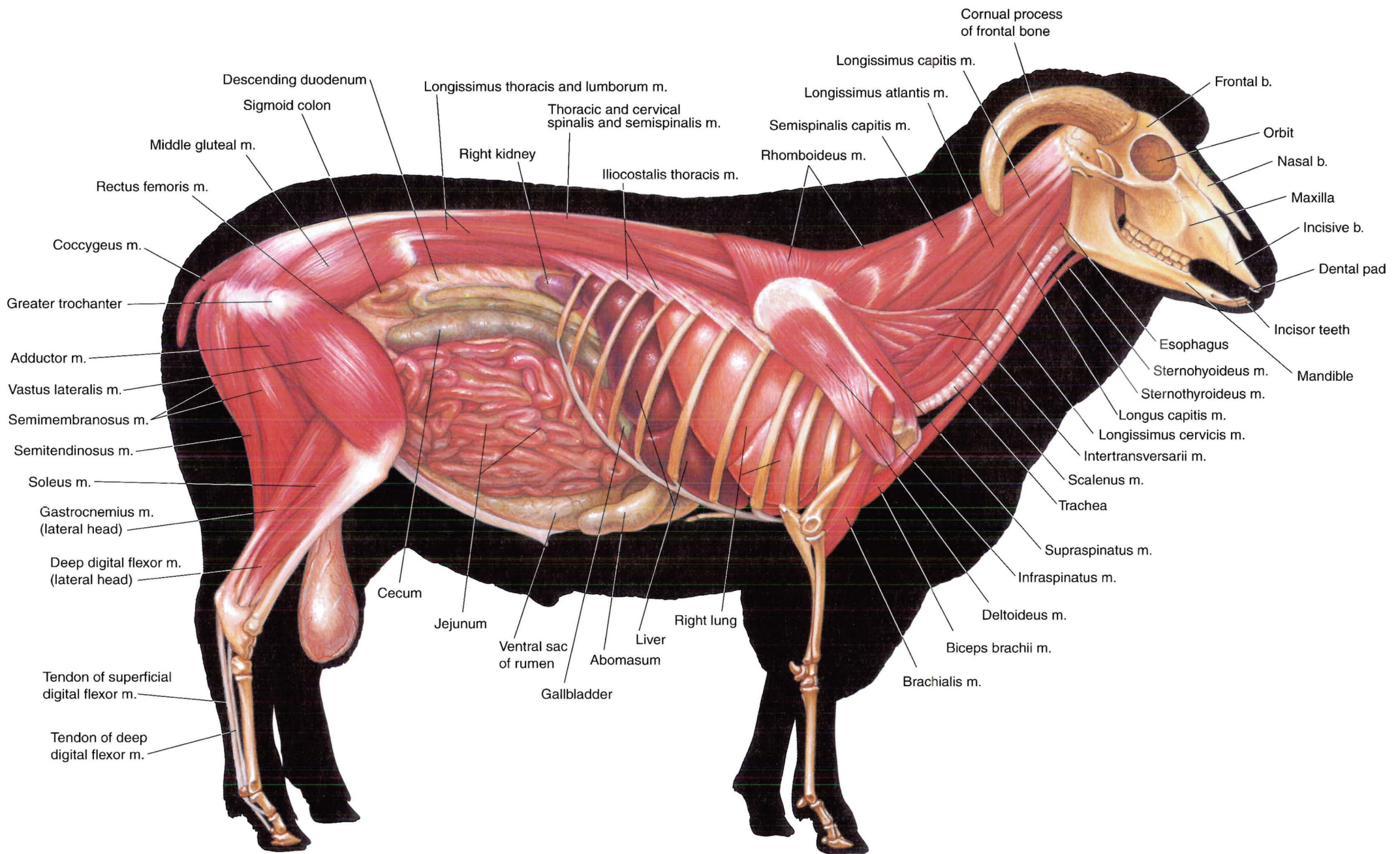
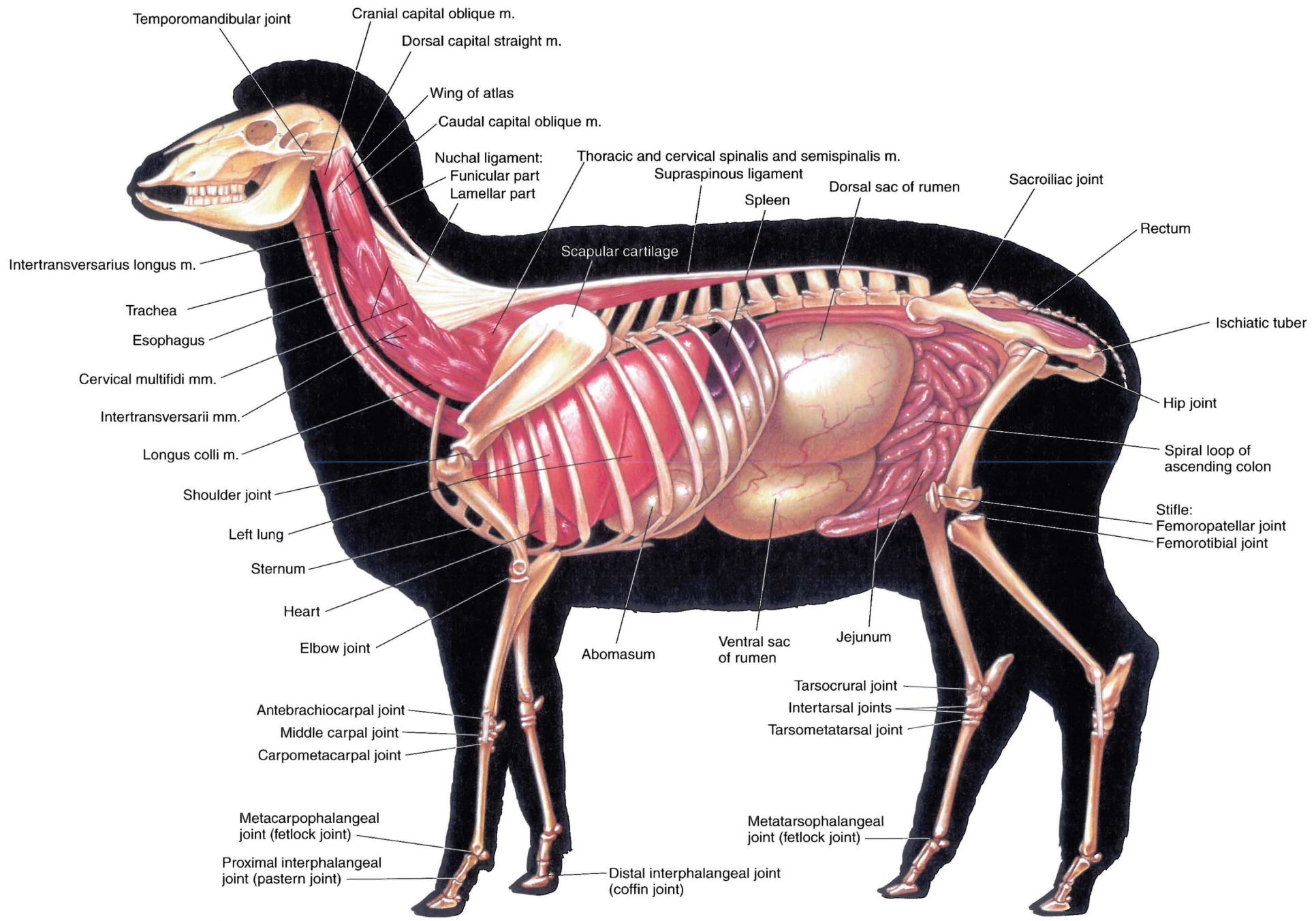
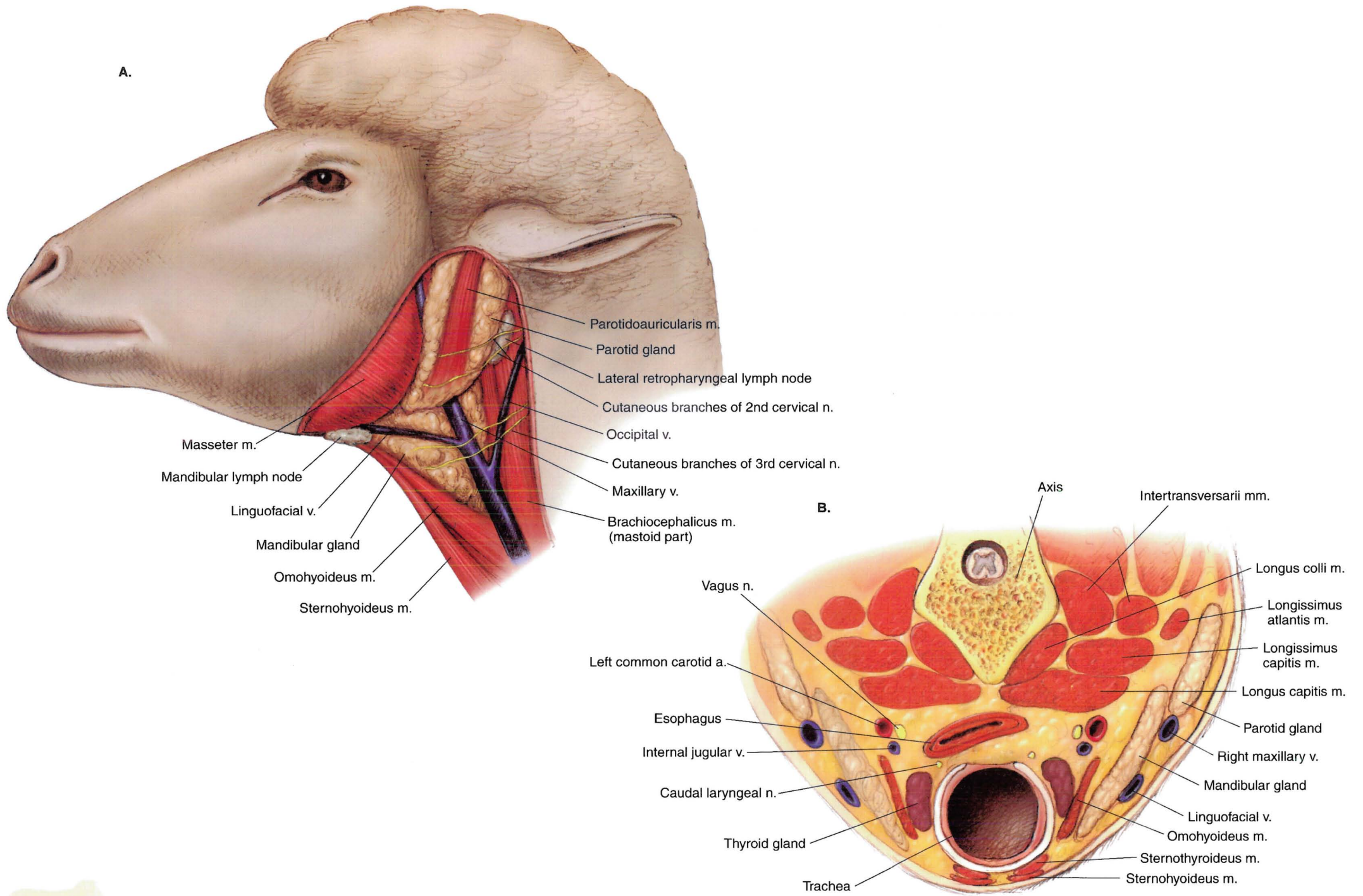


PLATE 3.7 Deep cervical muscles and *in situ* viscera of the ram. Omentum removed.  
Right lateral view. m = muscle, b = bone

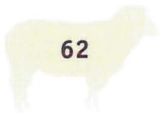



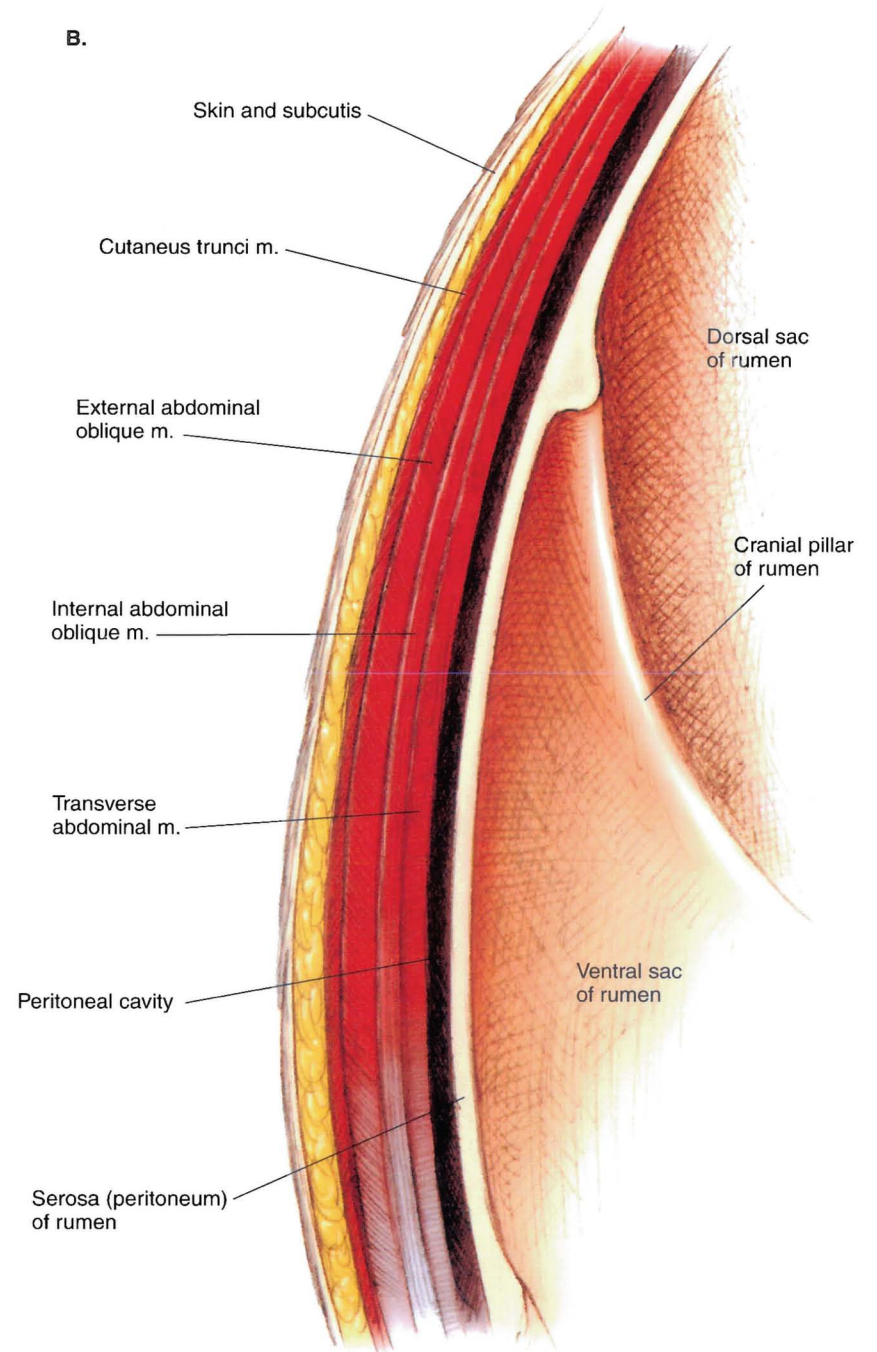
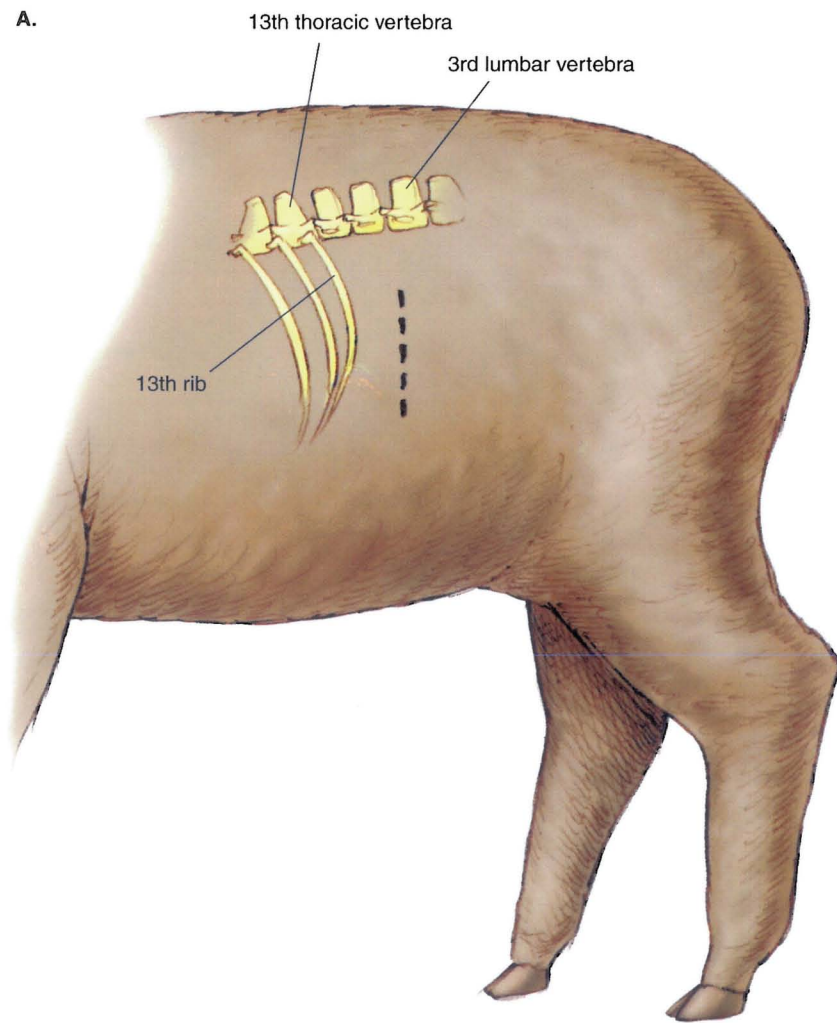
**PLATE 3.8** Deep cervical muscles, *in situ* viscera, skeleton, and major joints of the ewe. Left lateral view. m = muscle



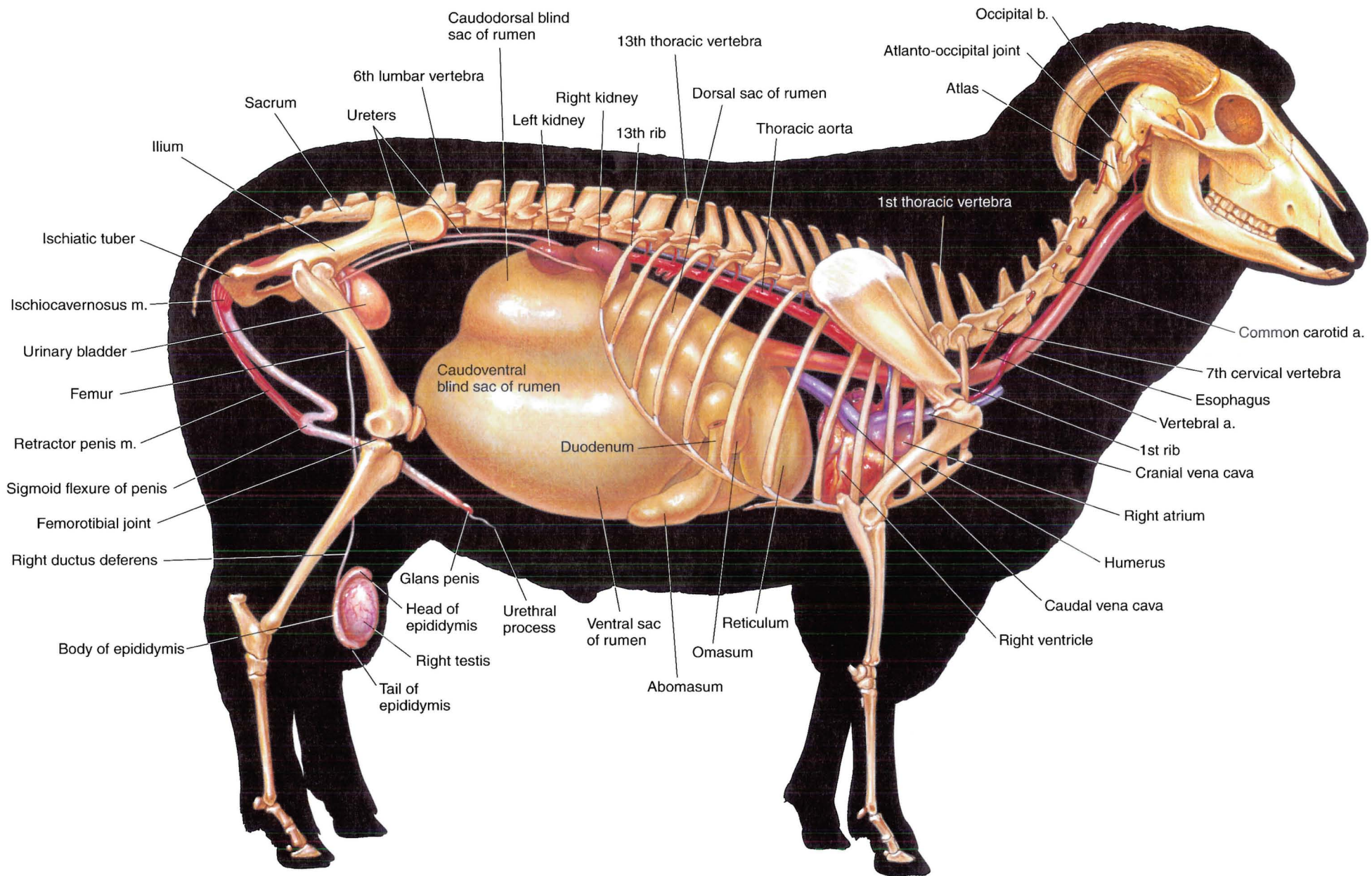
**PLATE 3.9** A. Dissection of the parotid region of a sheep. Skin, cutaneous muscles, and fascia are removed. Left lateral view. B. Cross-section of the neck at the level of the thyroid gland. Caudocranial view. m = muscle, v = vein, a = artery, n = nerve





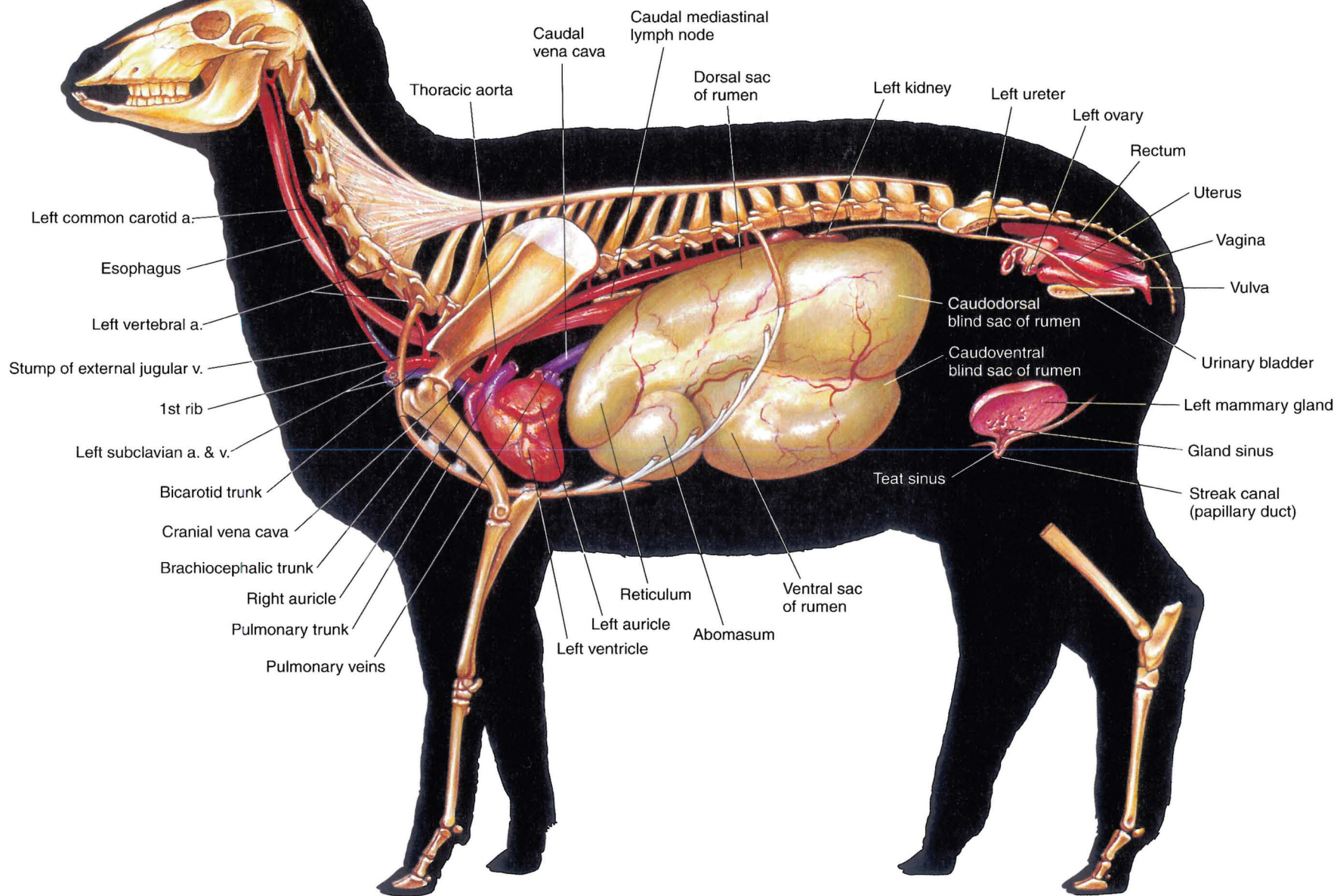


**PLATE 3.10** A. Location of the left flank incision: *dashed line*. B. Cross-section through the left abdominal wall and subjacent ruminal wall. Caudocranial view. m = muscle

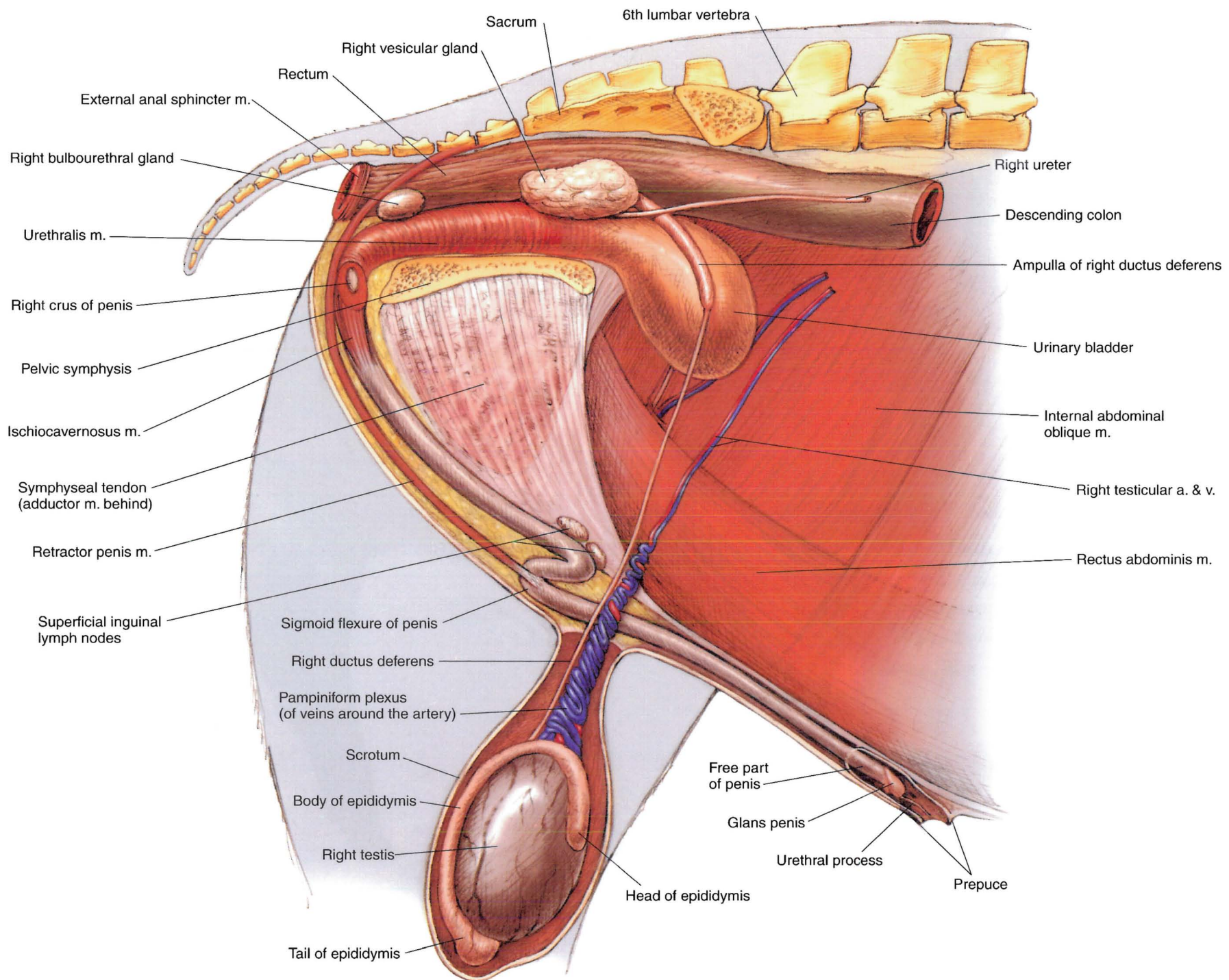


**PLATE 3.11** Reproductive organs, urinary organs, esophagus and stomach, heart, and adjacent major vessels related to the skeleton of the ram. Right lateral view.  
 b = bone, m = muscle, a = artery



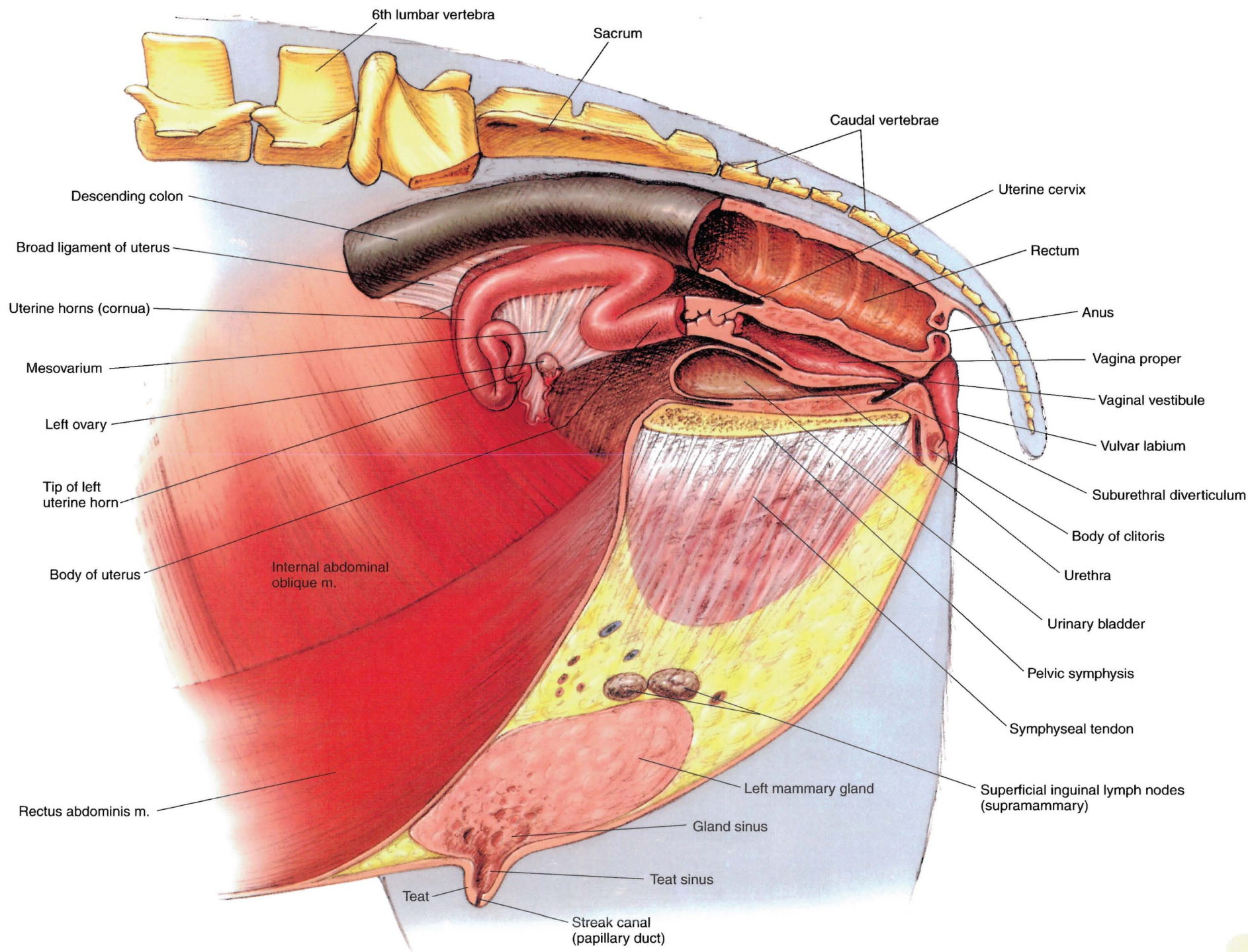


**PLATE 3.12** Reproductive organs, urinary organs, heart, and adjacent major vessels, esophagus and stomach of the ewe. Left lateral view. a = artery, v = vein



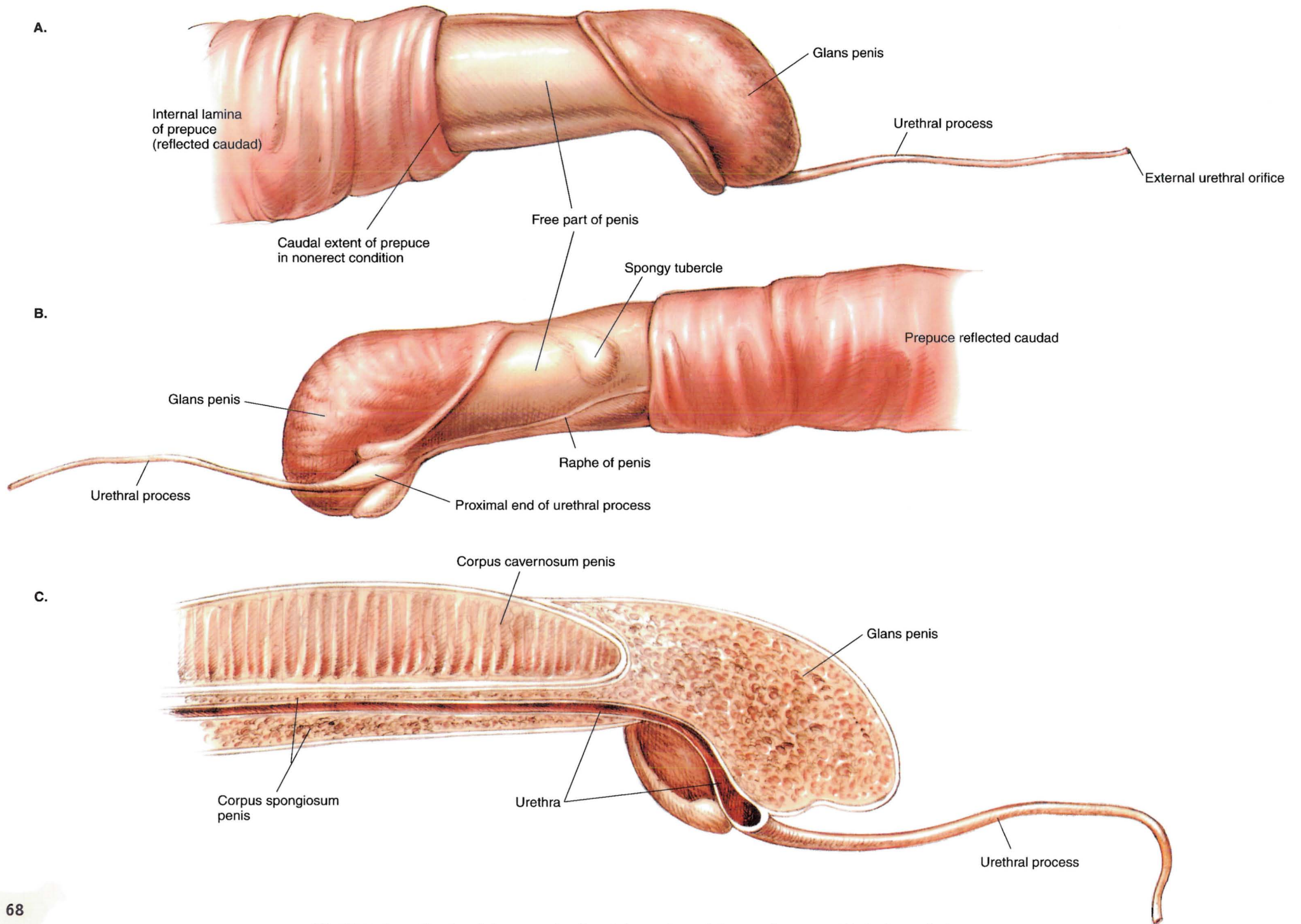
**PLATE 3.13** Relations of the reproductive organs of the ram. Right lateral view. Right pelvic limb and body wall are removed. The ram's prostate gland is entirely disseminate; it lies deep to the urethralis muscle. m = muscle, a = artery, v = vein





**PLATE 3.14** Relations of the reproductive organs of the ewe. Left lateral view with partial median sections of the vagina, uterine cervix, rectum, urinary bladder, and urethra. m = muscle

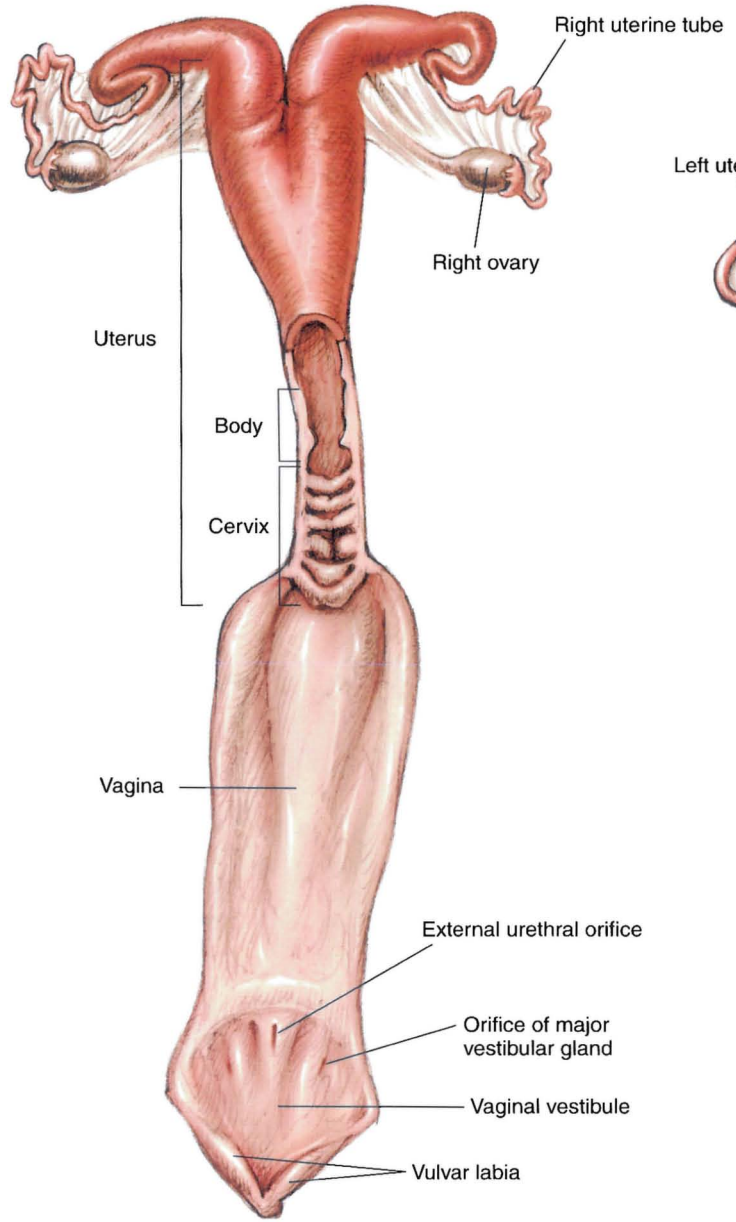




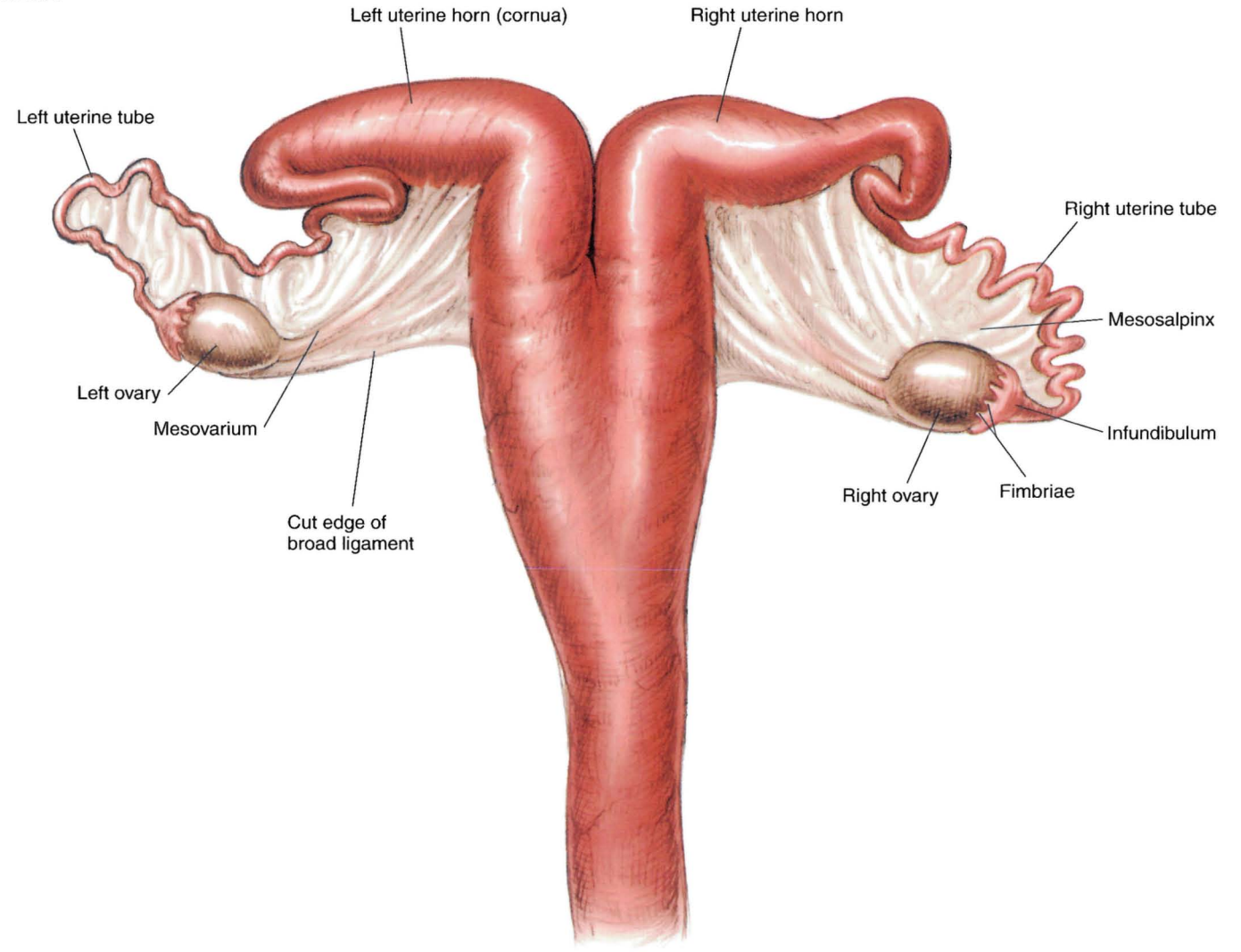
**PLATE 3.15** Penis of the ram. **A.** Cranial portion of the ram's penis. Right lateral view. **B.** Left lateral view. **C.** Median section. Right lateral view.



A.



B.



**PLATE 3.16** A. Isolated reproductive organs of the ewe. Vagina and a portion of the uterus opened dorsally. B. Isolated uterus, uterine tubes, and ovaries of the ewe. Dorsal view.





# SECTION 4 THE GOAT (*Capra hircus*)

## P L A T E S

- 4.1 Right lateral view of an Angora buck (billy).
- 4.2 Left lateral view of a Toggenberg doe (nanny).
- 4.3 Body regions of the goat.
- 4.4 Skeleton of the goat.
- 4.5 Cutaneous muscles and major fasciae of the buck.
- 4.6 Superficial muscles and veins of the doe.
- 4.7 Major structures of the caprine left distal metacarpus and digits.
- 4.8 A. Untrimmed hoofs of the goat.  
B. Trimmed hoofs of the goat.  
C. Parasagittal section through the fetlock and digit.
- 4.9 Deep muscles and *in situ* viscera of the buck.
- 4.10 Deep cervical muscles, *in situ* viscera, skeleton, and major joints of the doe.
- 4.11 Superficial structures of the goat's head.
- 4.12 Median section of the caprine head.
- 4.13 Reproductive organs, abdominal viscera, heart, and adjacent major vessels related to the skeleton of the buck.
- 4.14 Reproductive organs, abdominal viscera, heart, and adjacent major vessels of the doe.
- 4.15 Relations of the reproductive organs of the buck.
- 4.16 Relations of the reproductive organs of the doe.






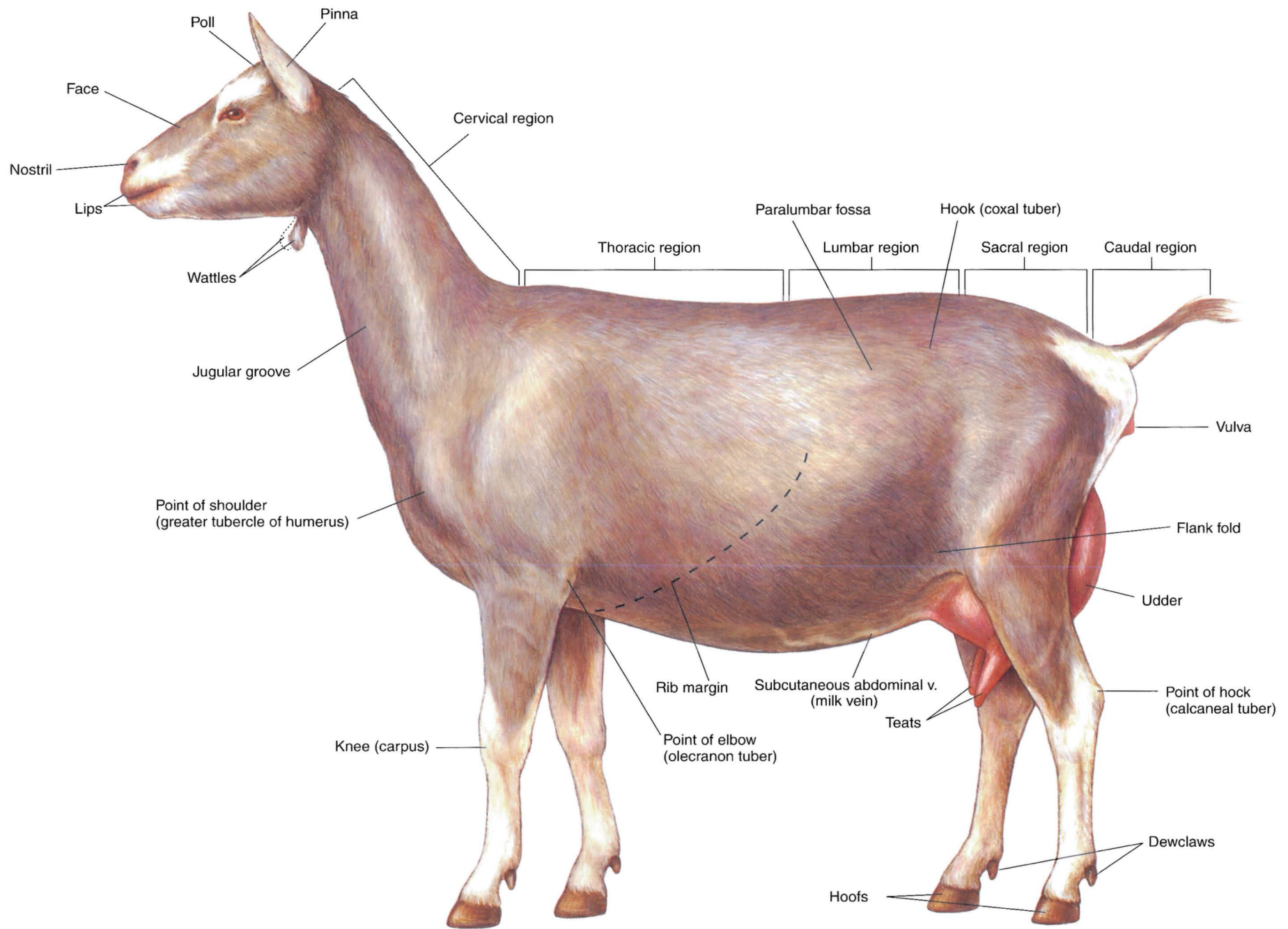


PLATE 4.1 Right lateral view of an Angora buck (billy).





**PLATE 4.2** Left lateral view of a Toggenberg doe (nanny).  
Dorsal vertebral regions are indicated. v = vein

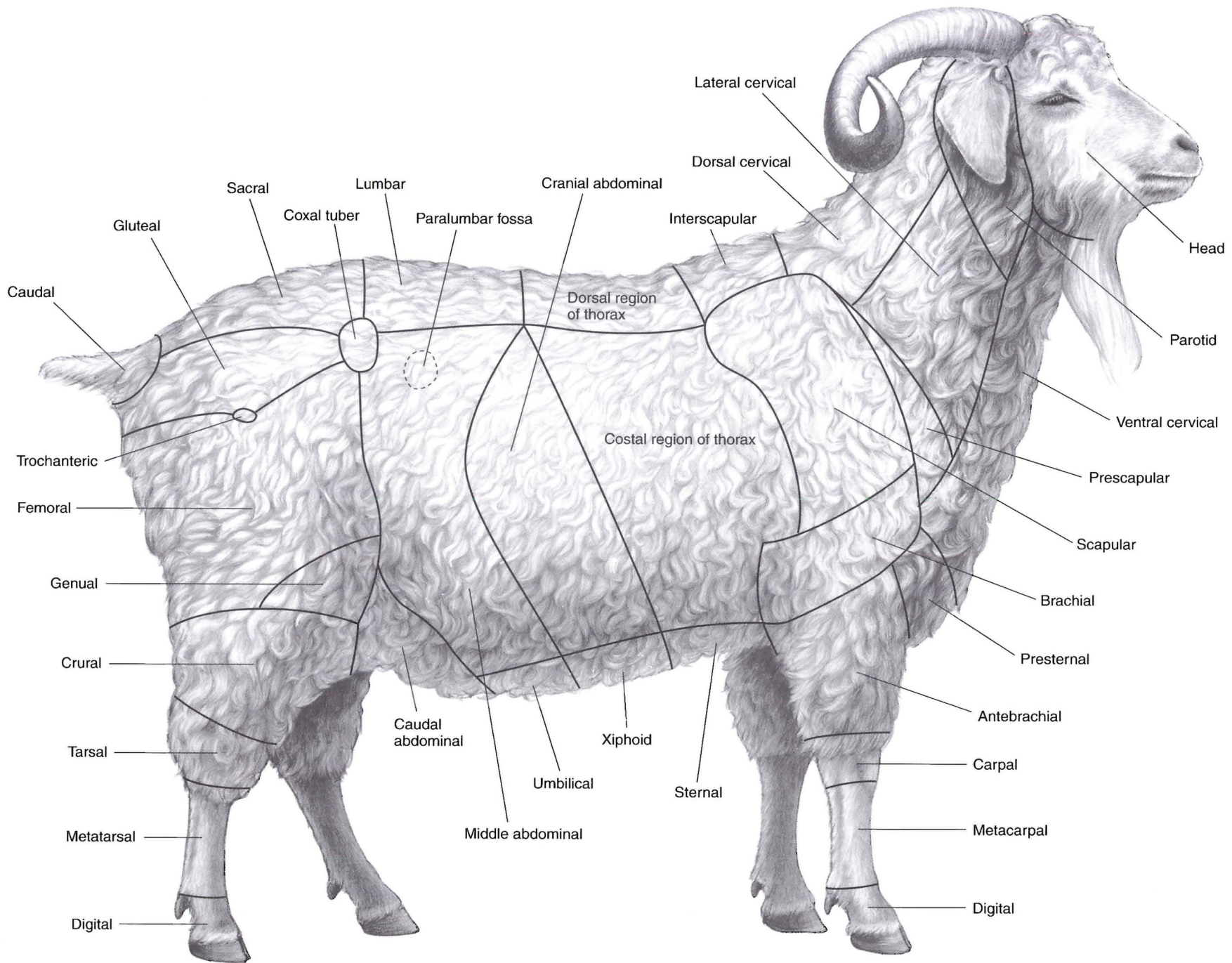
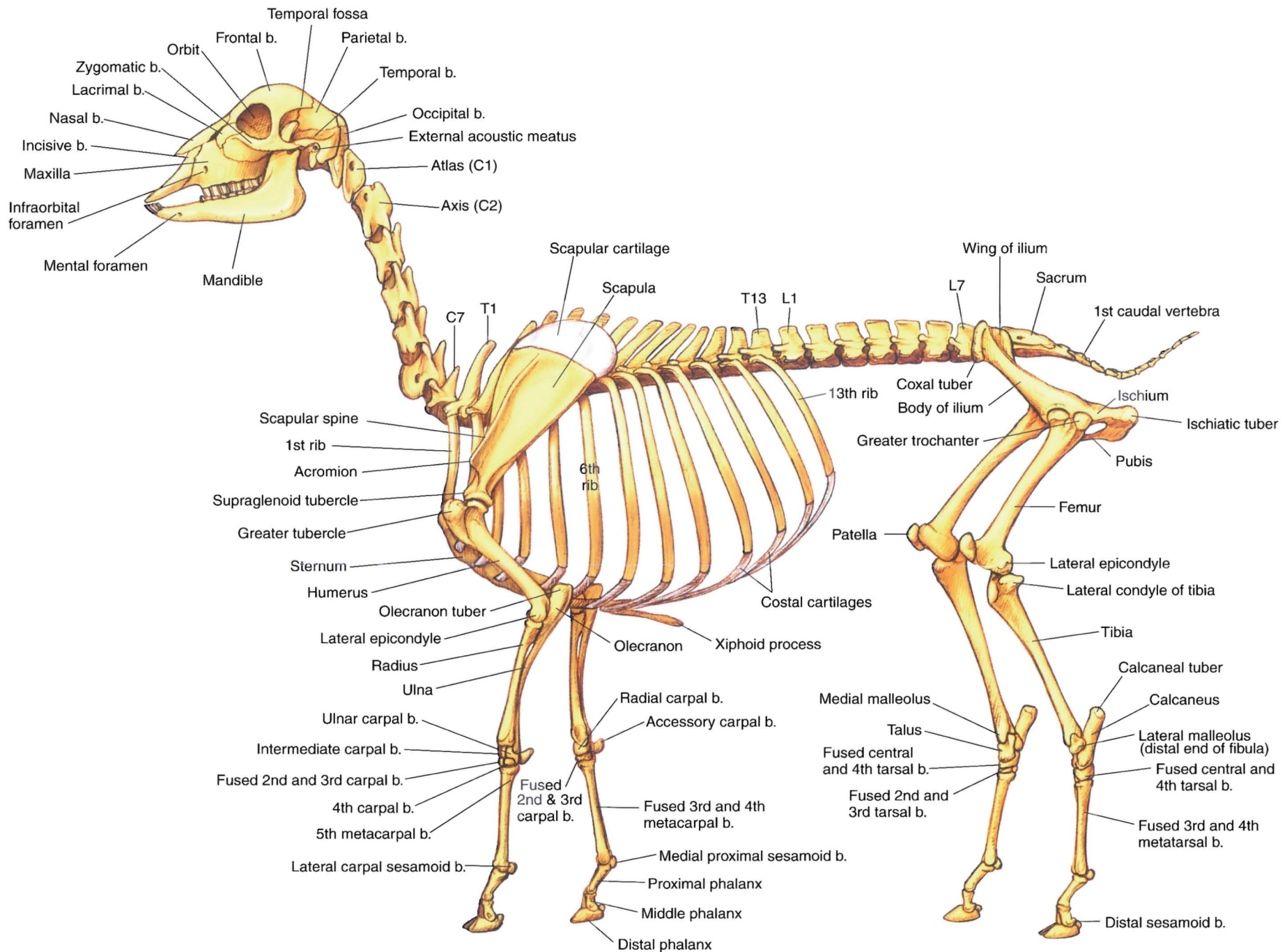


PLATE 4.3 Body regions of the goat. Right lateral view.





**PLATE 4.4** Skeleton of the goat. Left lateral view. b = bone, C = cervical vertebra, T = thoracic vertebra, L = lumbar vertebra

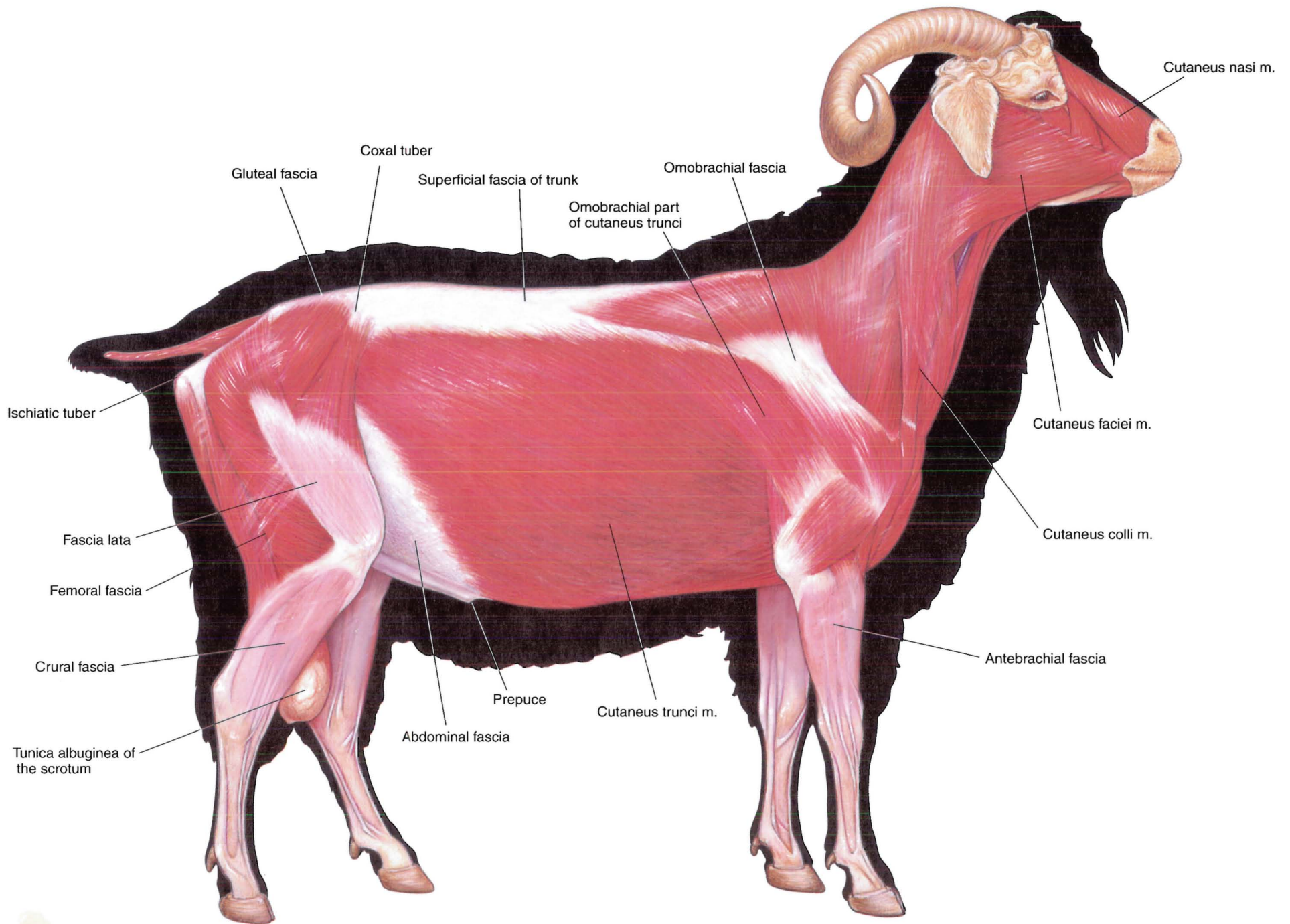


PLATE 4.5 Cutaneous muscles and major fasciae of the buck. Right lateral view. m = muscle



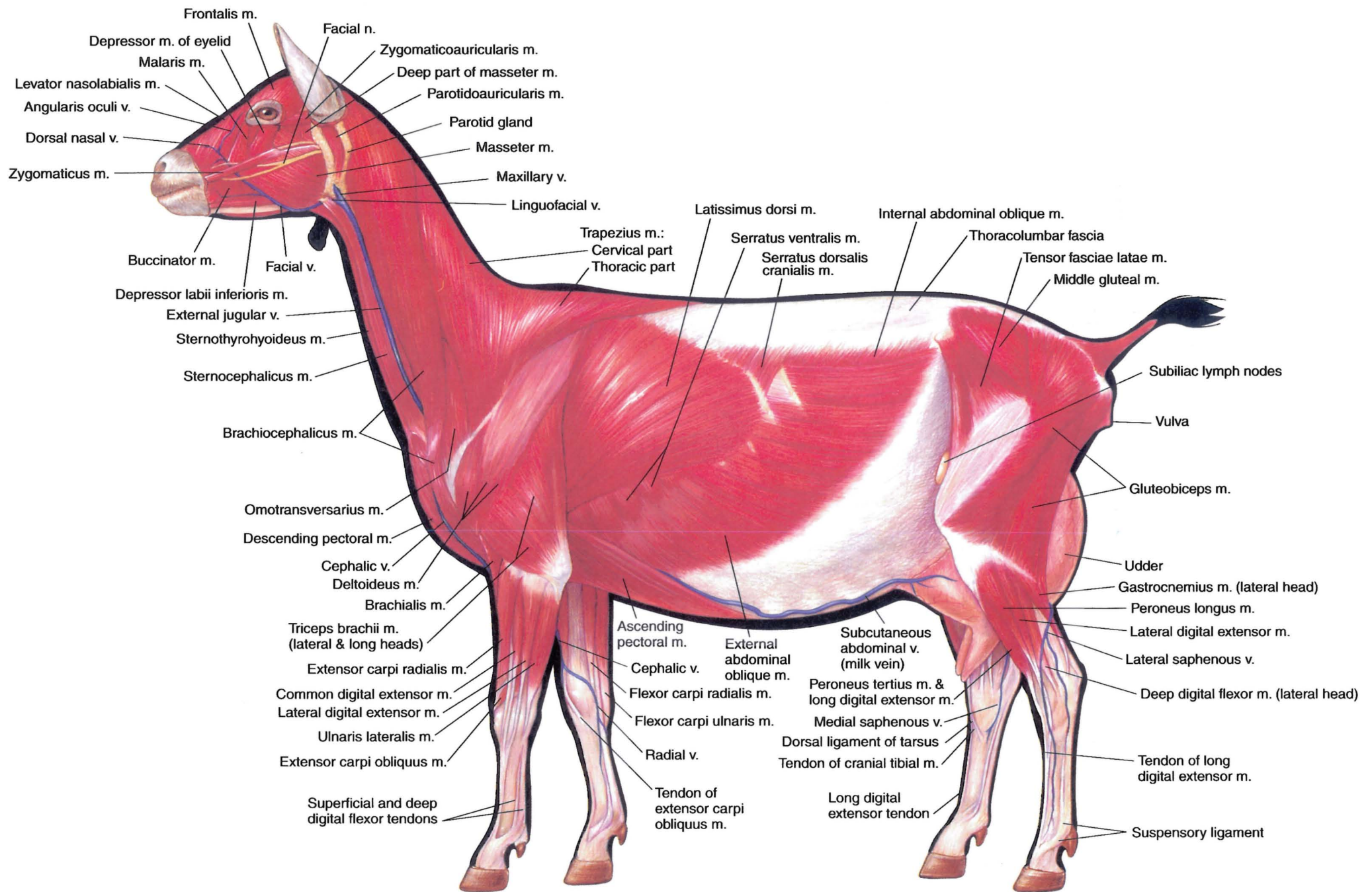
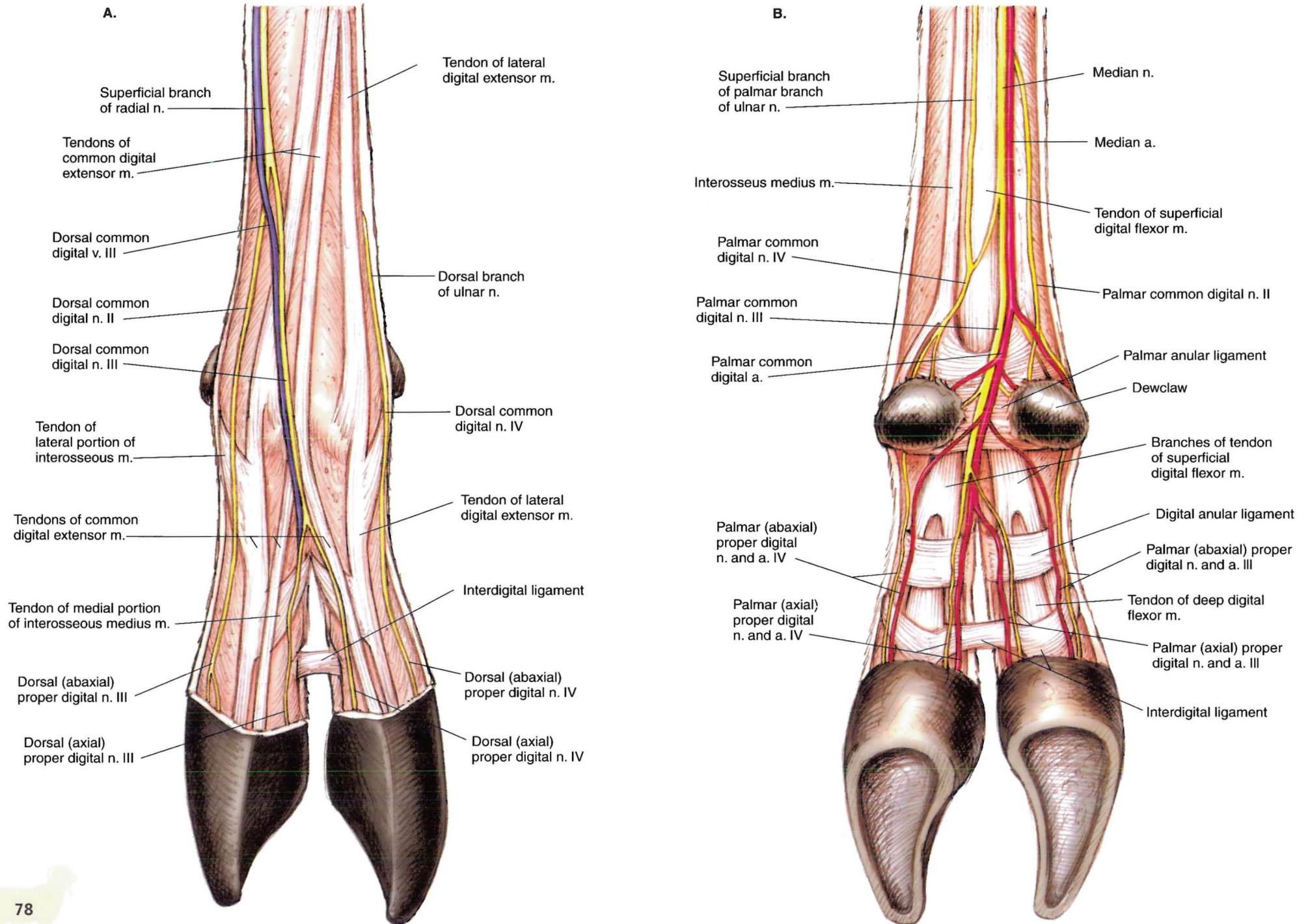
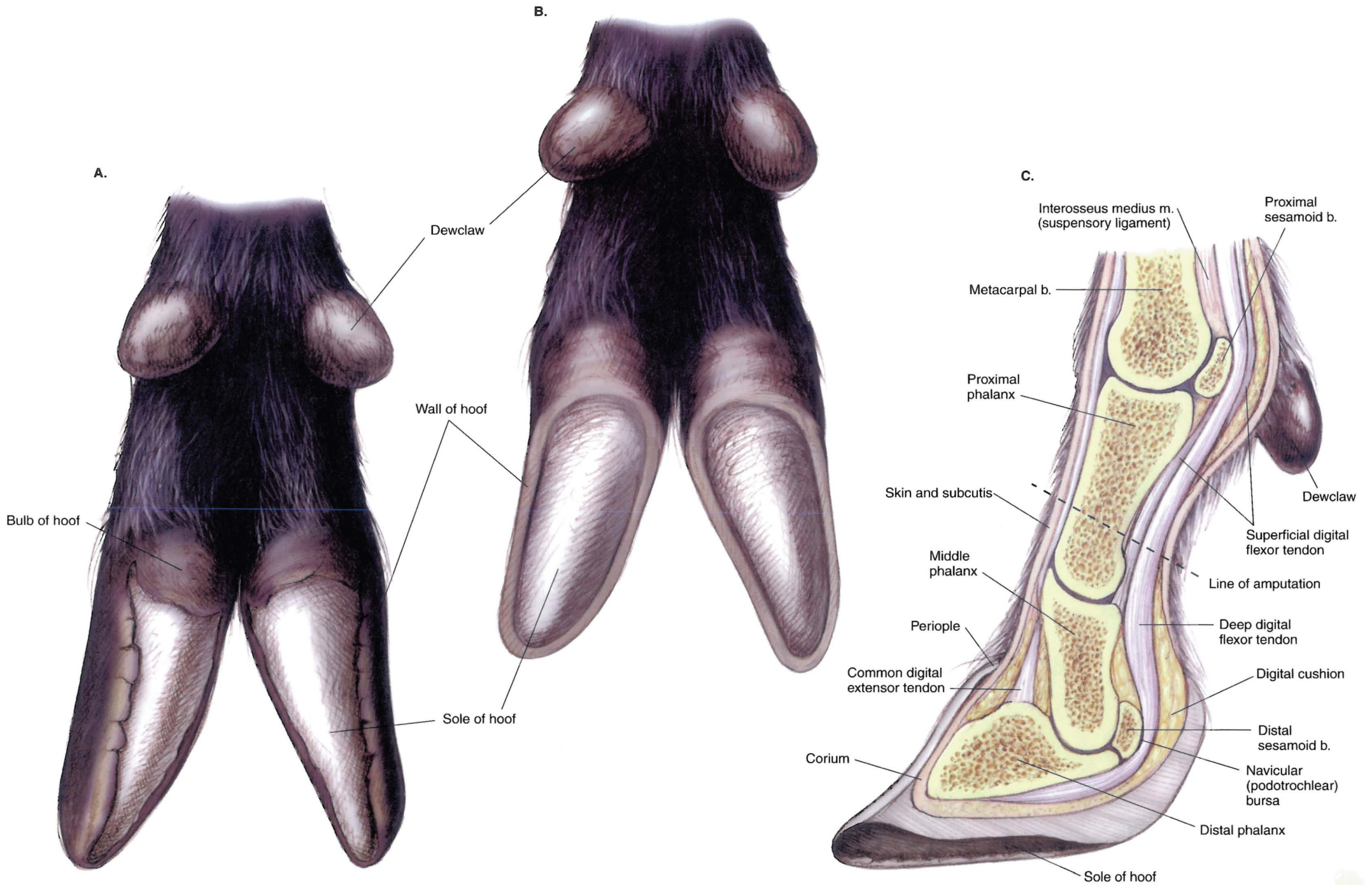


PLATE 4.6 Superficial muscles and veins of the doe. Left lateral view. m = muscle, v = vein



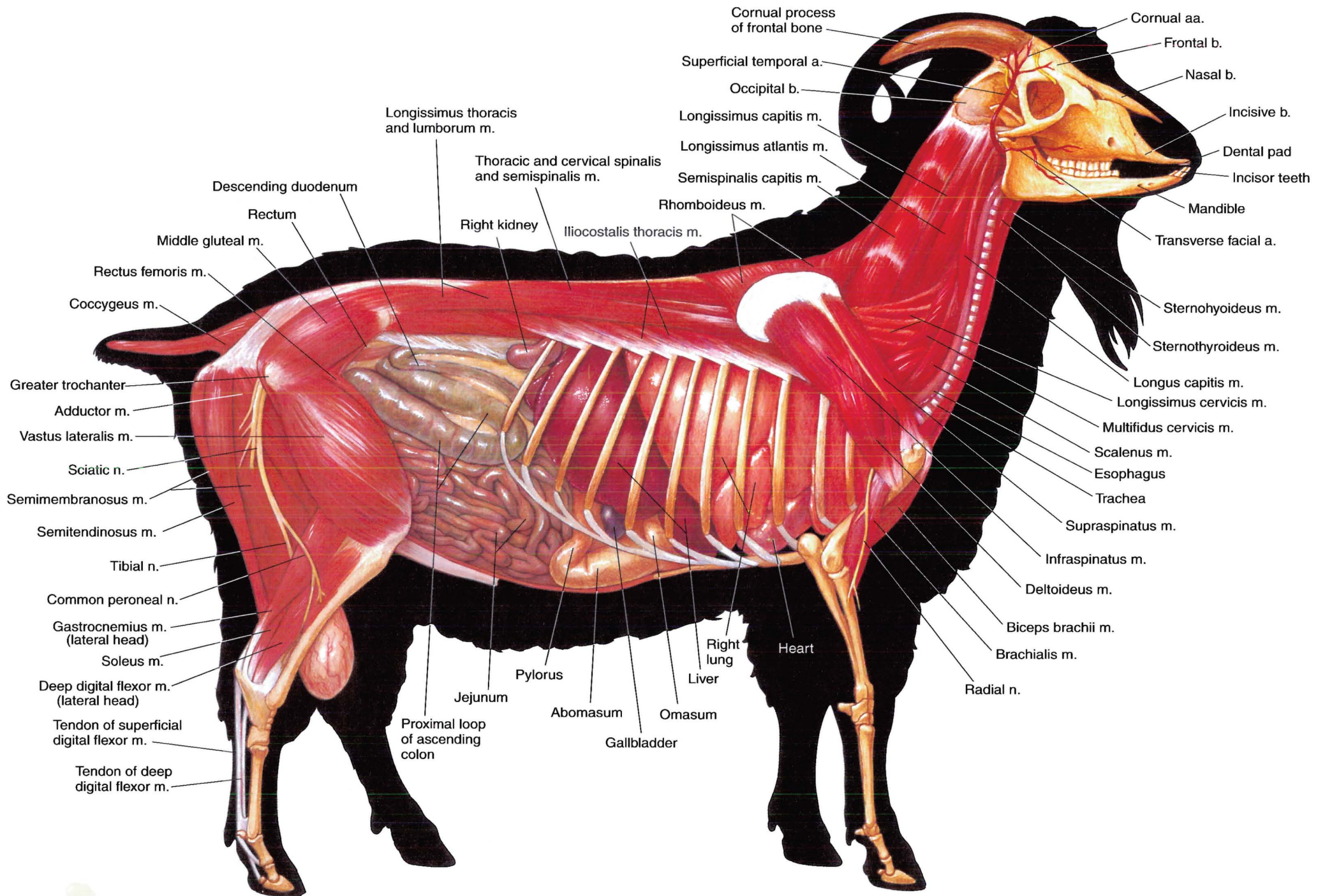
**PLATE 4.7** Major structures of the caprine left distal metacarpus and digits. **A.** Dorsal view, arteries excluded. **B.** Palmar view, veins excluded. n = nerve, m = muscle, a = artery





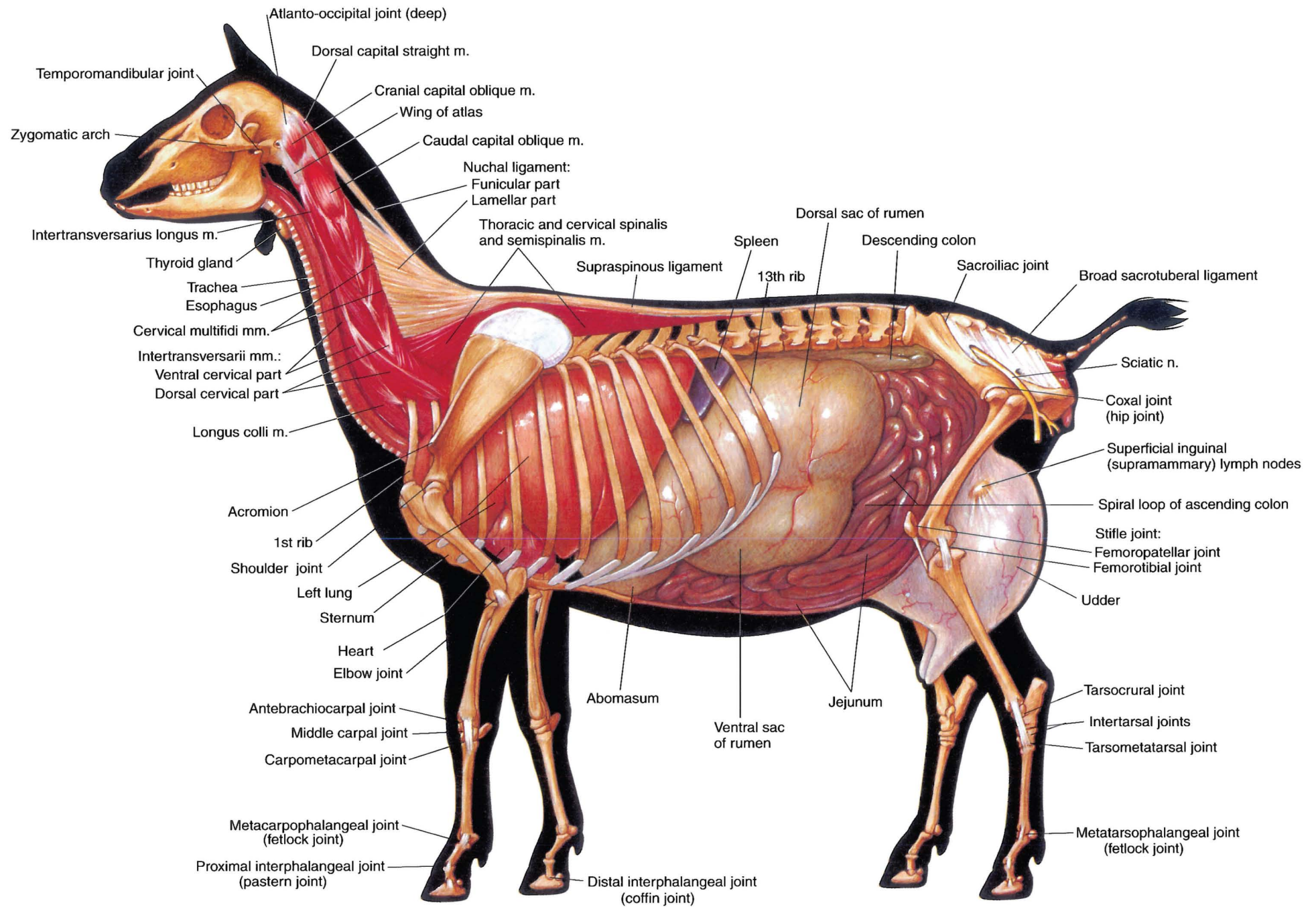
**PLATE 4.8** A. Untrimmed hooves of the goat. B. Trimmed hooves of the goat. C. Parasagittal section through the fetlock and digit. For artiodactyls, claw is synonymous with hoof. When kept on soft ground, a mature goat's hooves should be trimmed every 4–5 months. b = bone





**PLATE 4.9** Deep muscles and *in situ* viscera of the buck. Greater omentum is removed. Right lateral view. m = muscle, n = nerve, a = artery, b = bone





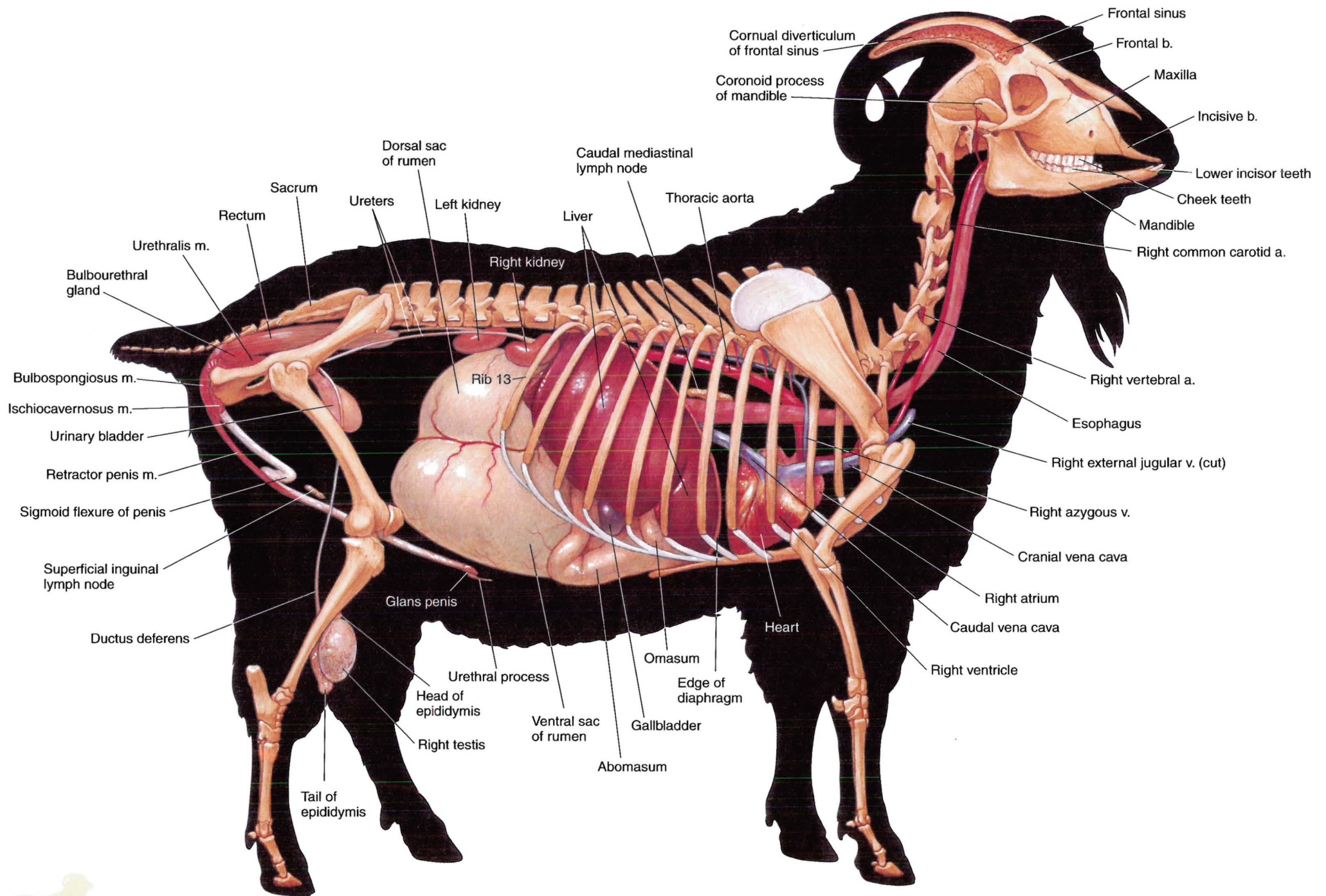
**PLATE 4.10** Deep cervical muscles, *in situ* viscera, skeleton, and major joints of the doe.  
 Left lateral view. m = muscle, n = nerve





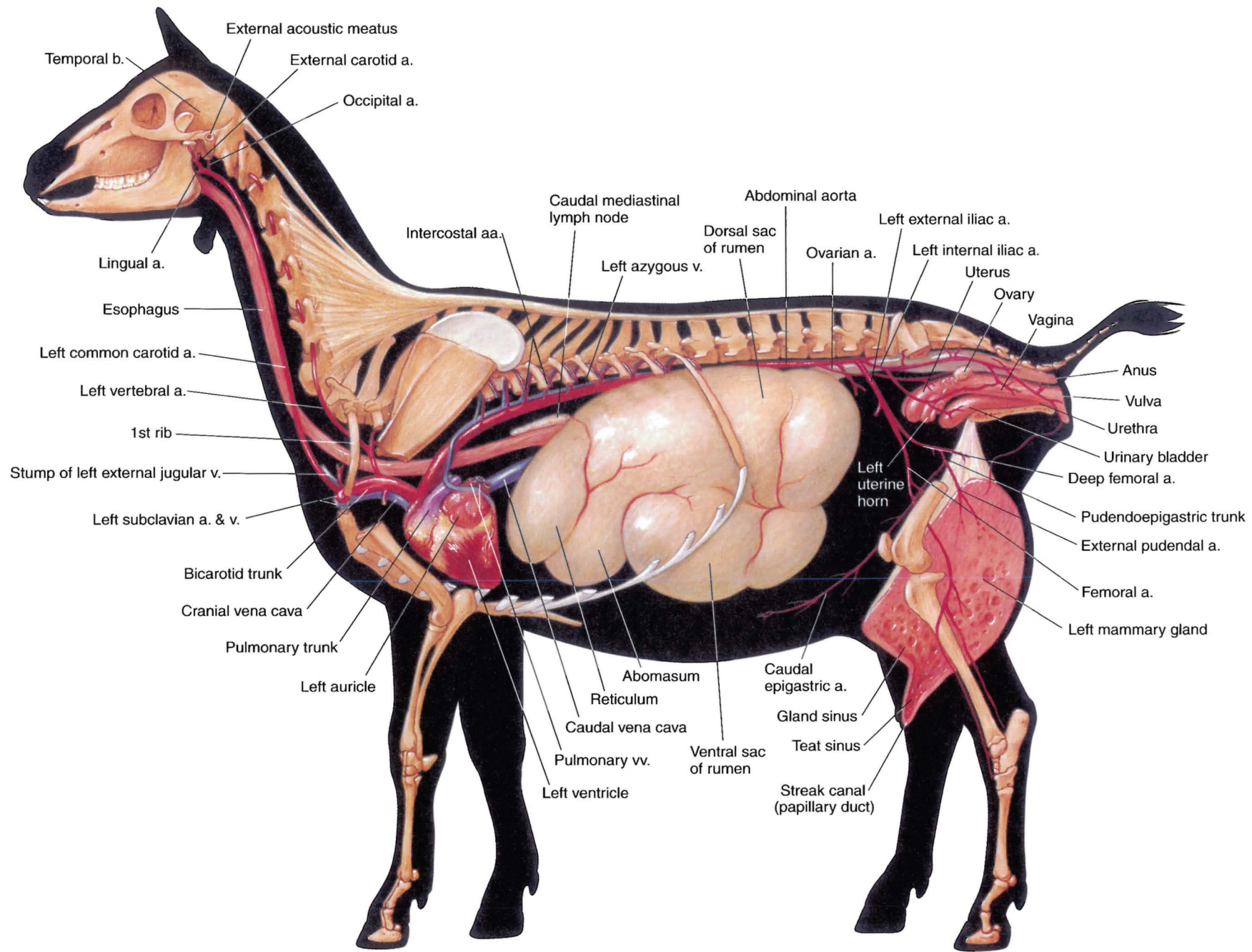




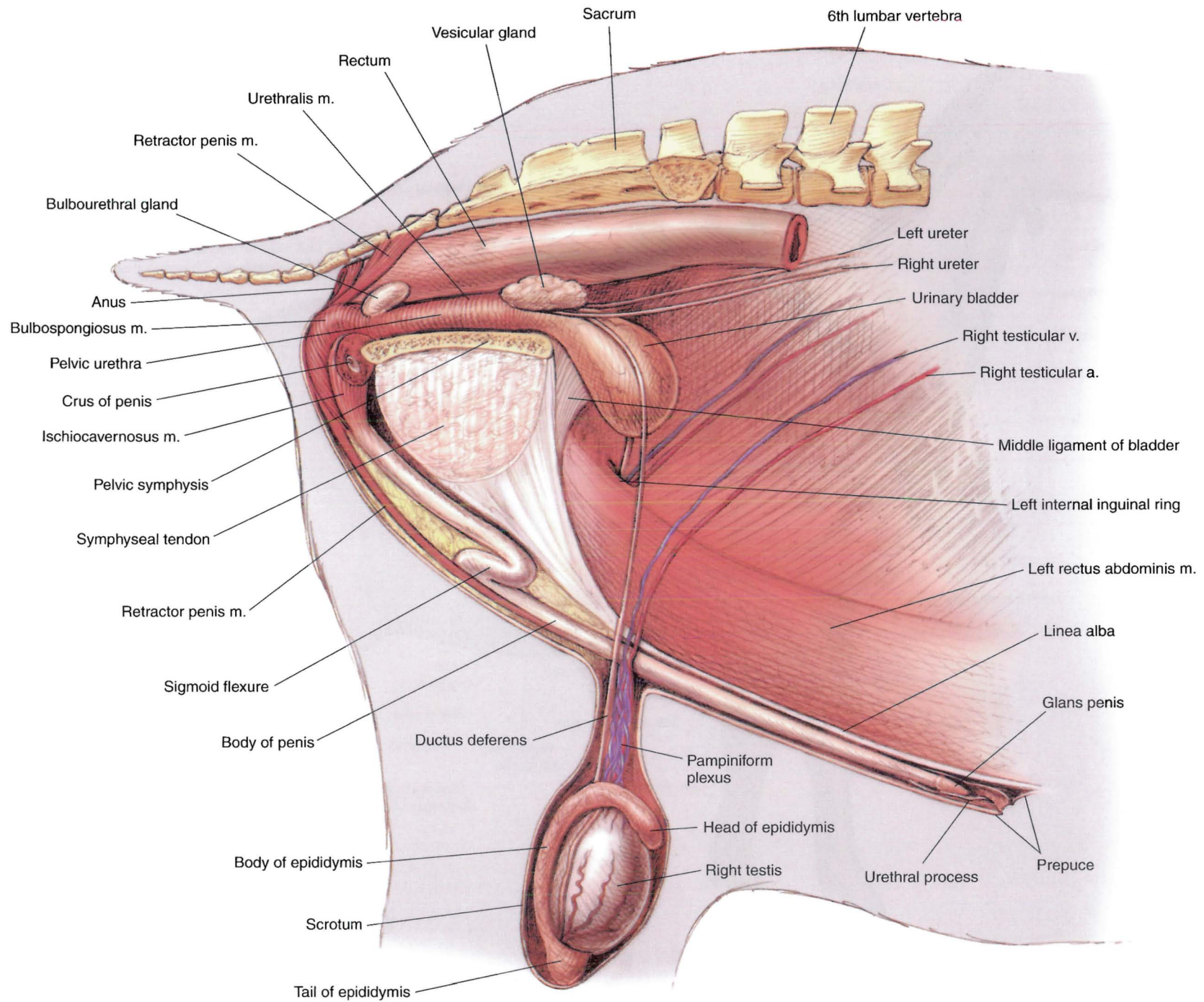


**PLATE 4.13** Reproductive organs, abdominal viscera, heart, and adjacent major vessels related to the skeleton of the buck. Intestines and lungs removed. Right lateral view.  
 m = muscle, v = vein, a = artery, b = bone





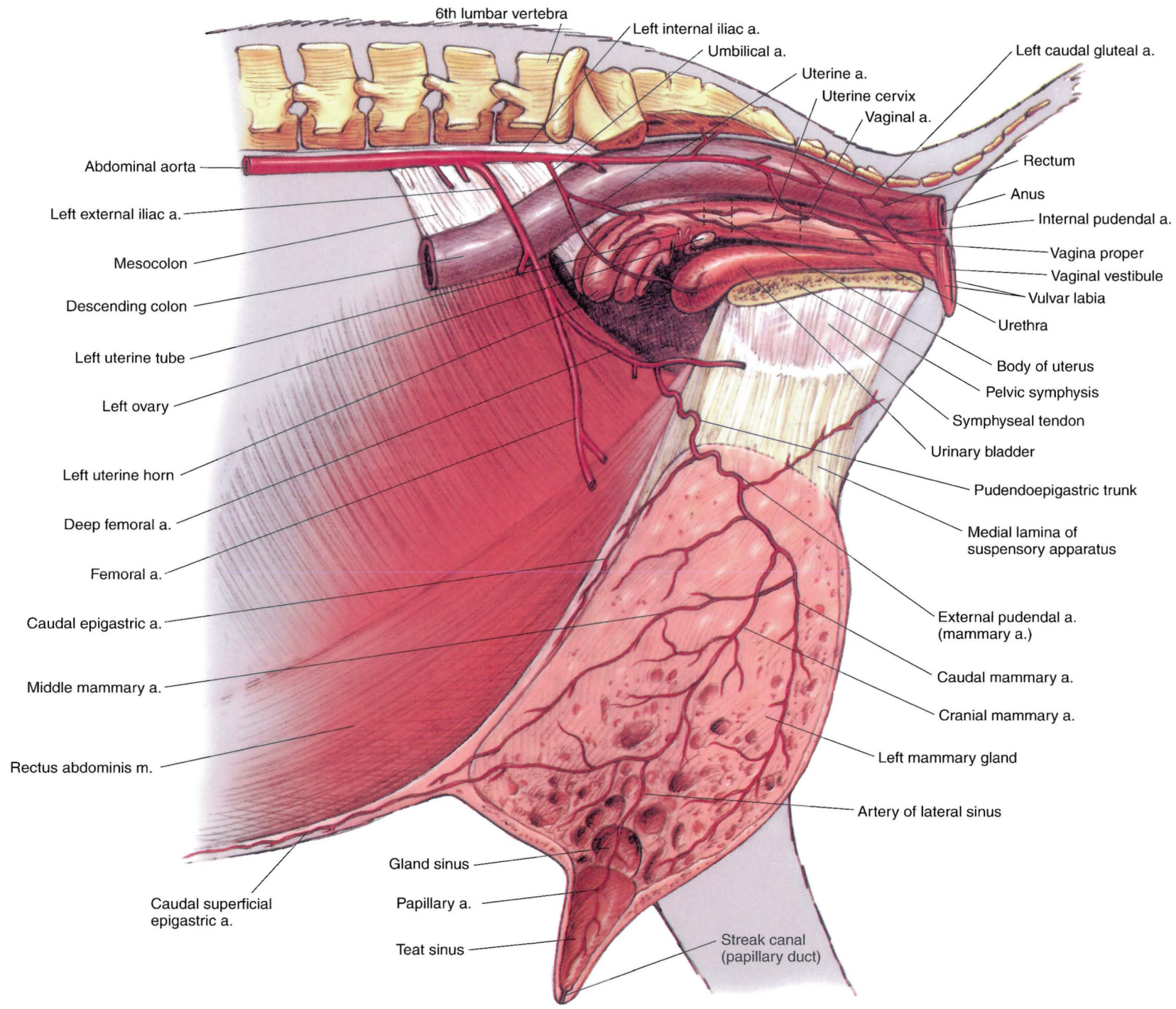
**PLATE 4.14** Reproductive organs, abdominal viscera, heart, and adjacent major vessels of the doe. Ribs 2 and 12 and the lungs and intestines are removed.  
 Left lateral view. a = artery, b = bone, v = vein



**PLATE 4.15** Relations of the reproductive organs of the buck. Right pelvic limb and body wall are removed. Right lateral view. a = artery, m = muscle, v = vein







**PLATE 4.16** Relations of the reproductive organs of the doe.  
Median section. a = artery, m = muscle





# SECTION 5 THE LLAMA AND ALPACA

(*Lama glama* and *Lama pacos*)



## P L A T E S

- 5.1 Right lateral view of a male llama.
- 5.2 Left lateral view of a female huacaya alpaca.
- 5.3 Body regions of the llama.
- 5.4 Skeleton of the llama.
- 5.5 Cutaneous muscles and major fasciae of the male llama.
- 5.6 Superficial muscles of the female alpaca.
- 5.7 Deep muscles and *in situ* viscera of the male llama.
- 5.8 Deep cervical muscles, *in situ* viscera, and major joints of the female alpaca.
- 5.9 Major structures of the lamoid left distal metacarpus and digits.
- 5.10 Median section of the llama's head.
- 5.11 Proper and improper placement of a halter on a llama's head.
- 5.12 Relations of the llama's common carotid artery and jugular vein.
- 5.13 Dentition of the male llama.
- 5.14 Isolated stomach and intestines of the male llama.
- 5.15 Reproductive and urinary organs, stomach, liver, heart, and adjacent major vessels related to the skeleton of the male llama.
- 5.16 Reproductive and urinary organs, stomach, heart, and adjacent major vessels of the female alpaca.
- 5.17 Relations of the reproductive organs of the male llama.
- 5.18 Relations of the reproductive organs of the female alpaca.

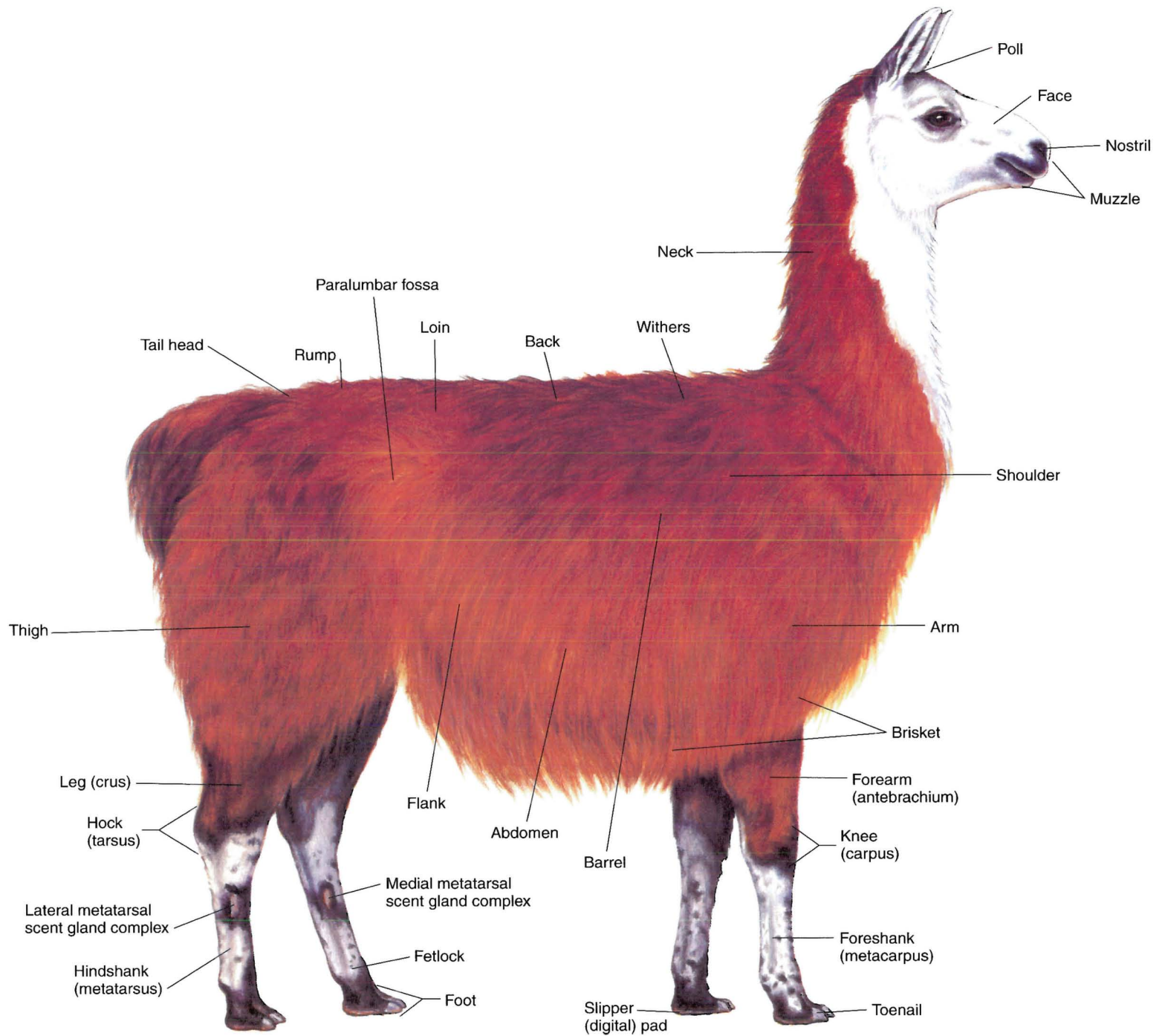


PLATE 5.1 Right lateral view of a male llama.



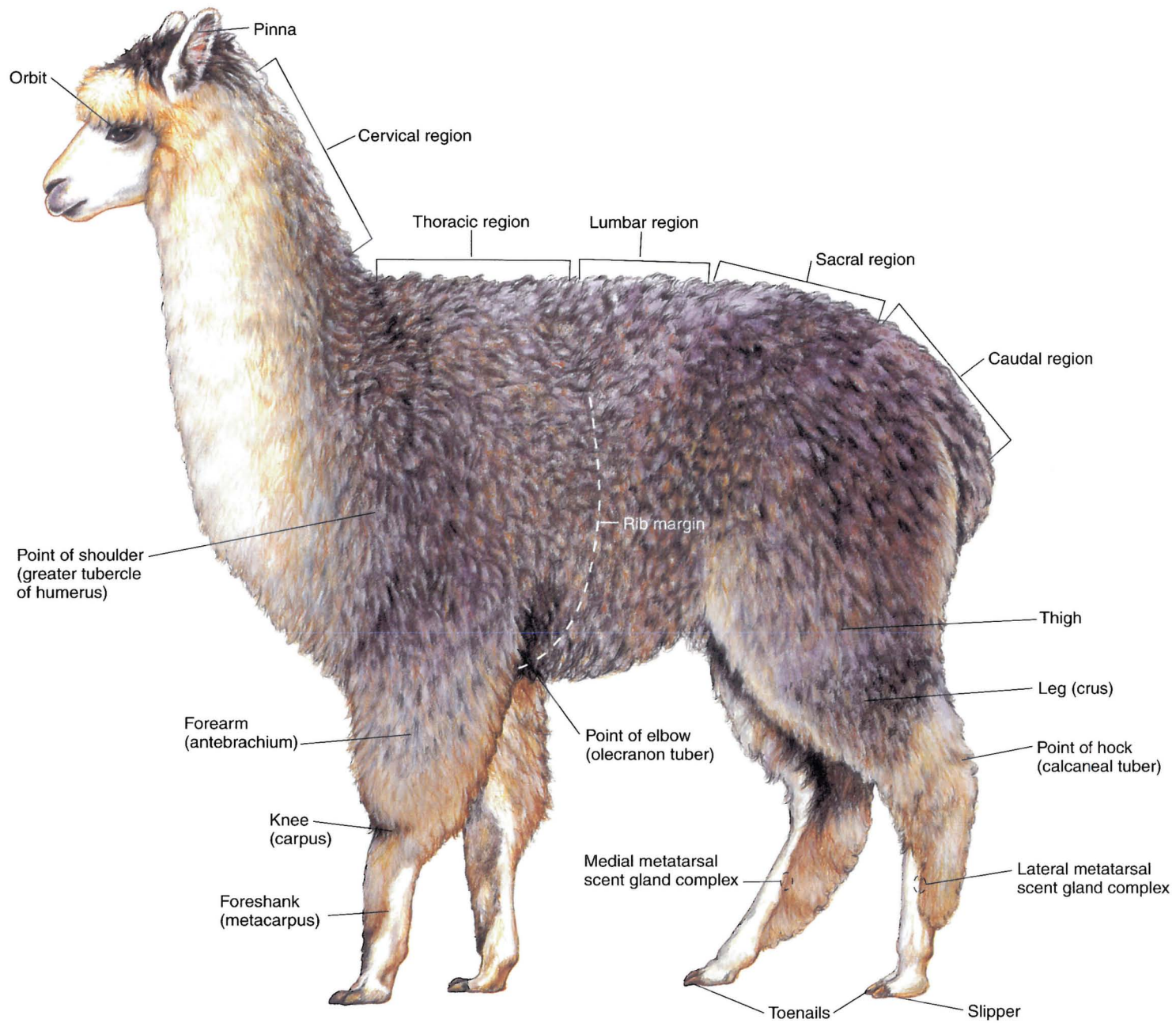


PLATE 5.2 Left lateral view of a female huacaya alpaca. Dorsal vertebral regions are indicated.

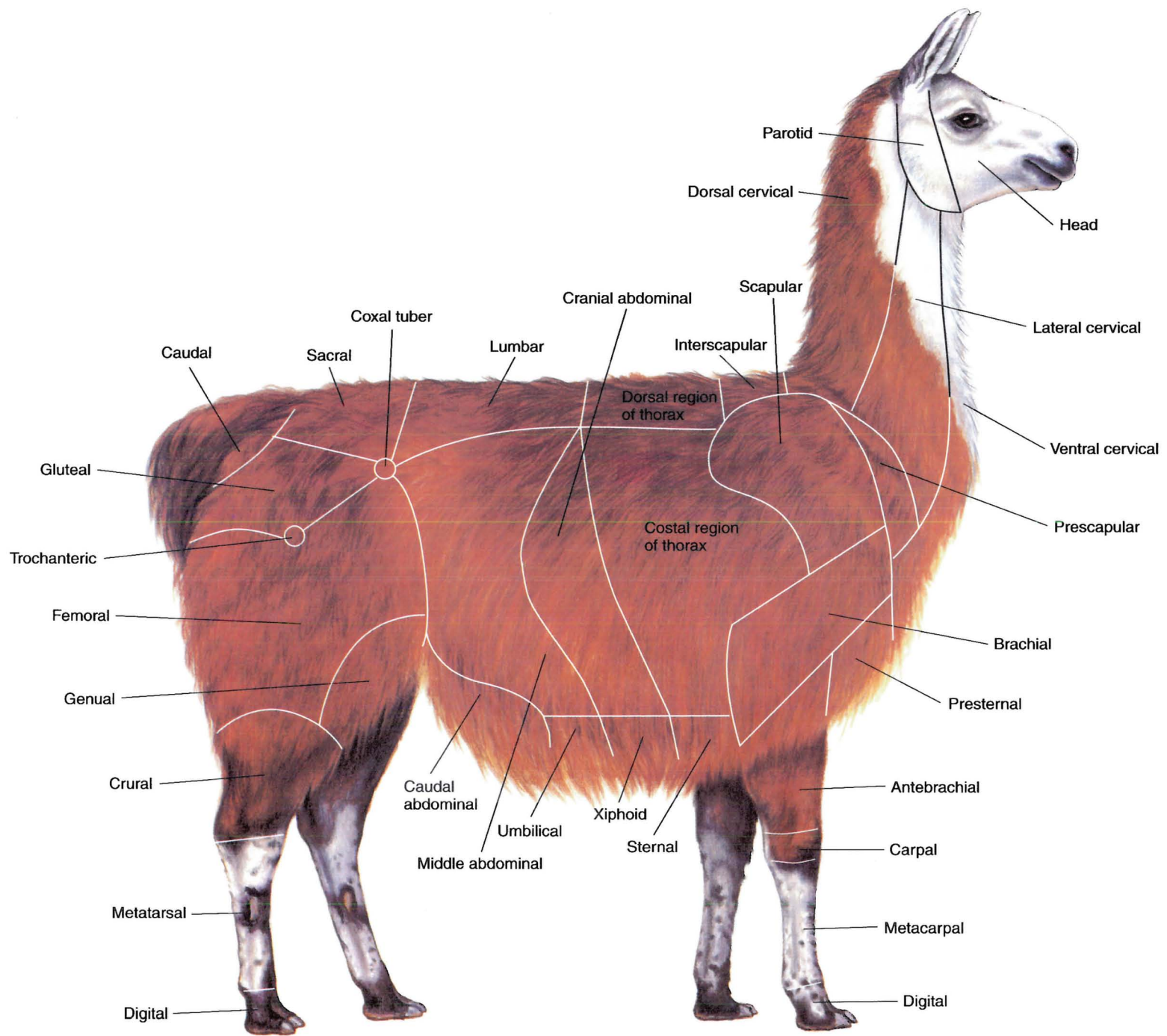
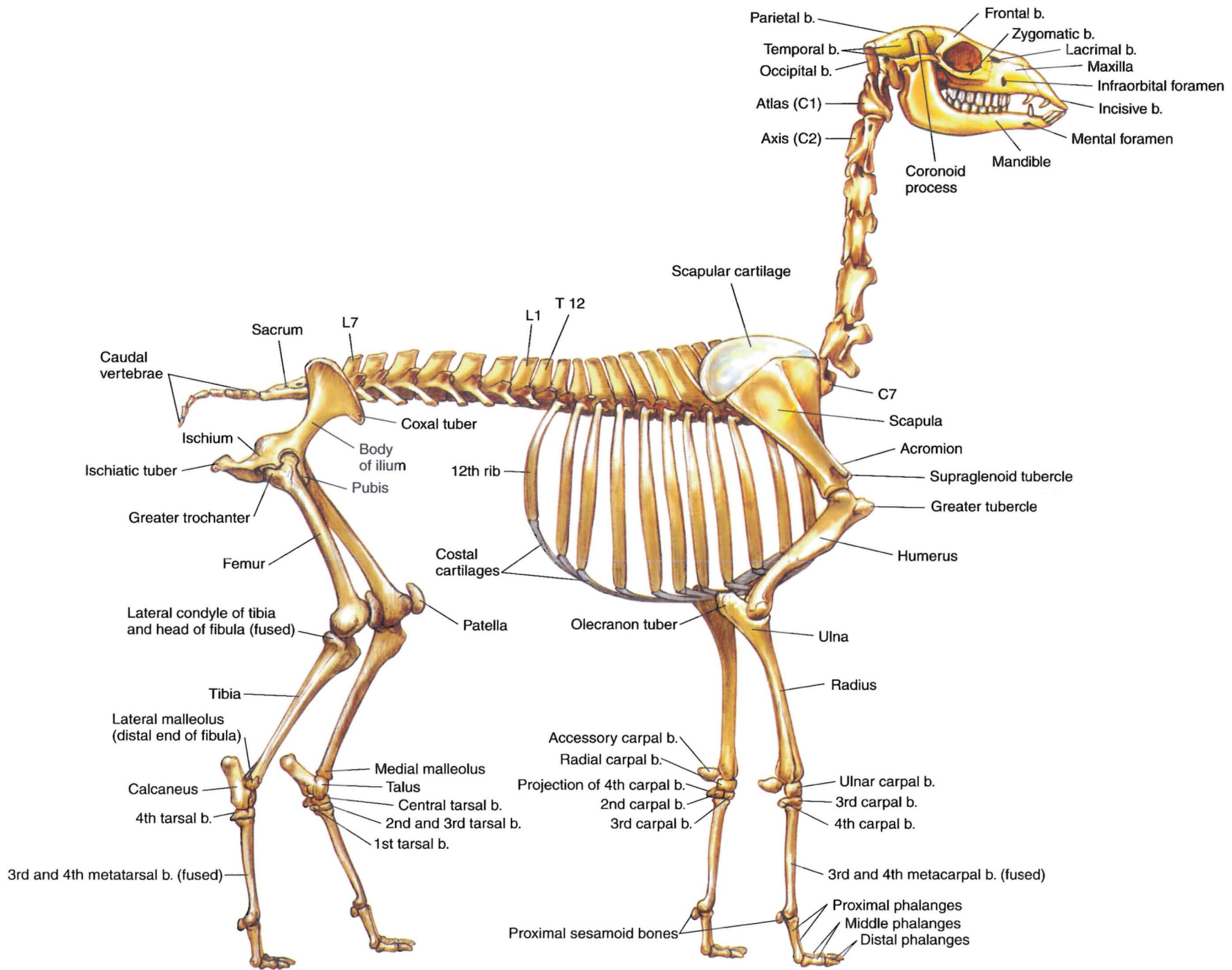


PLATE 5.3 Body regions of the llama.





**PLATE 5.4** Skeleton of the llama. Right lateral view. C = cervical vertebra, T = thoracic vertebra, L = lumbar vertebra, b = bone

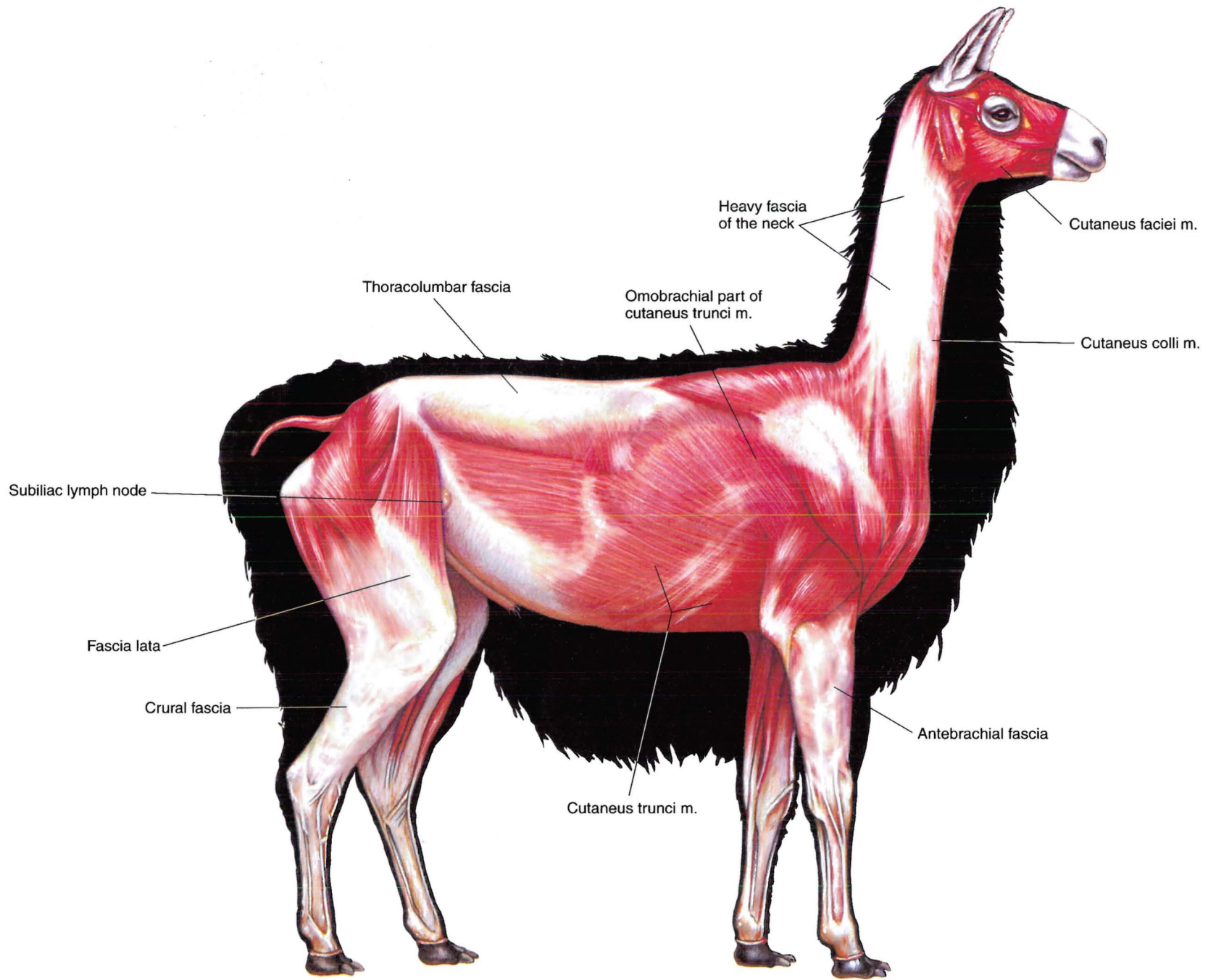


PLATE 5.5 Cutaneous muscles and major fasciae of the male llama.  
Right lateral view. m = muscle



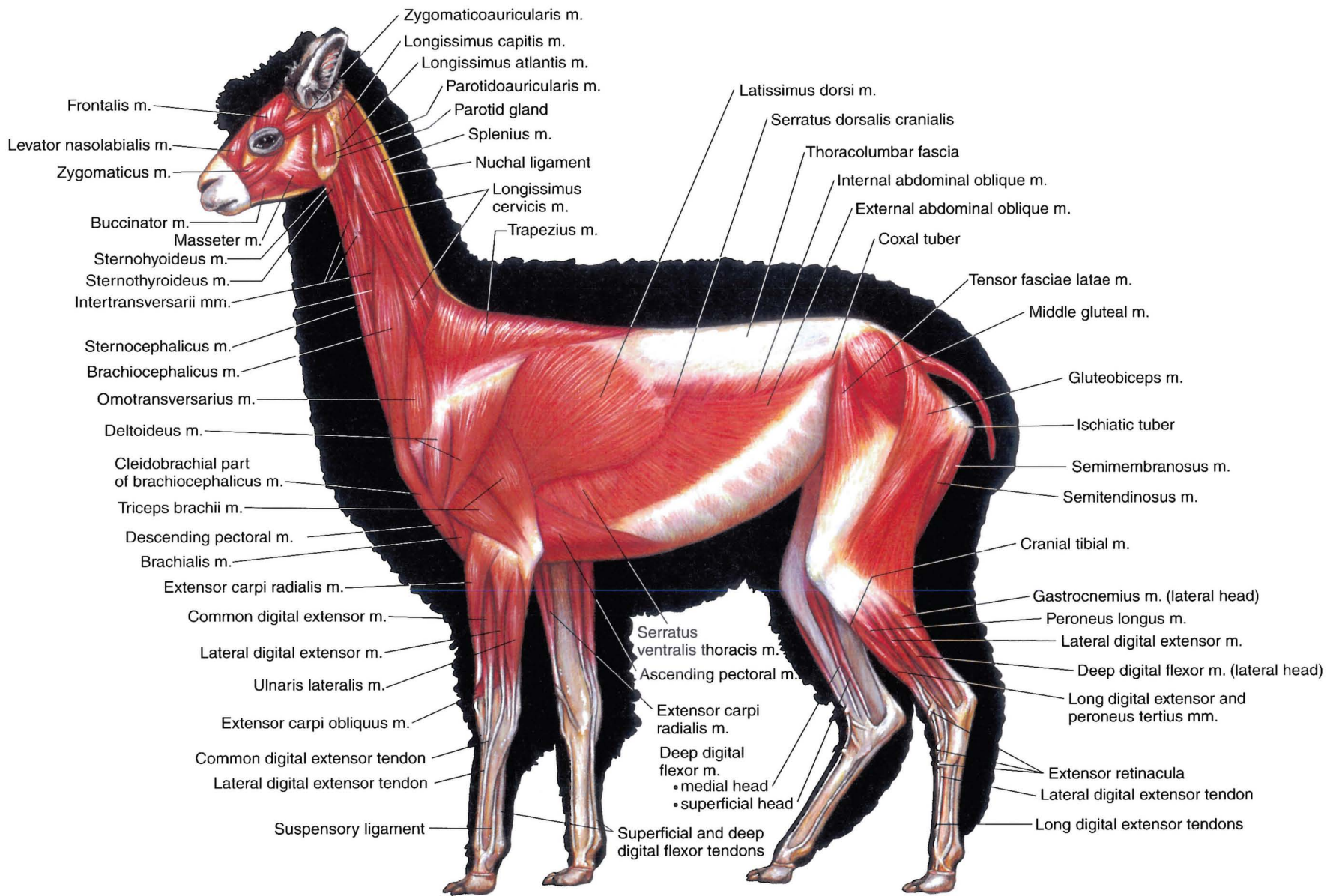


PLATE 5.6 Superficial muscles of the female alpaca. Left lateral view. m = muscle

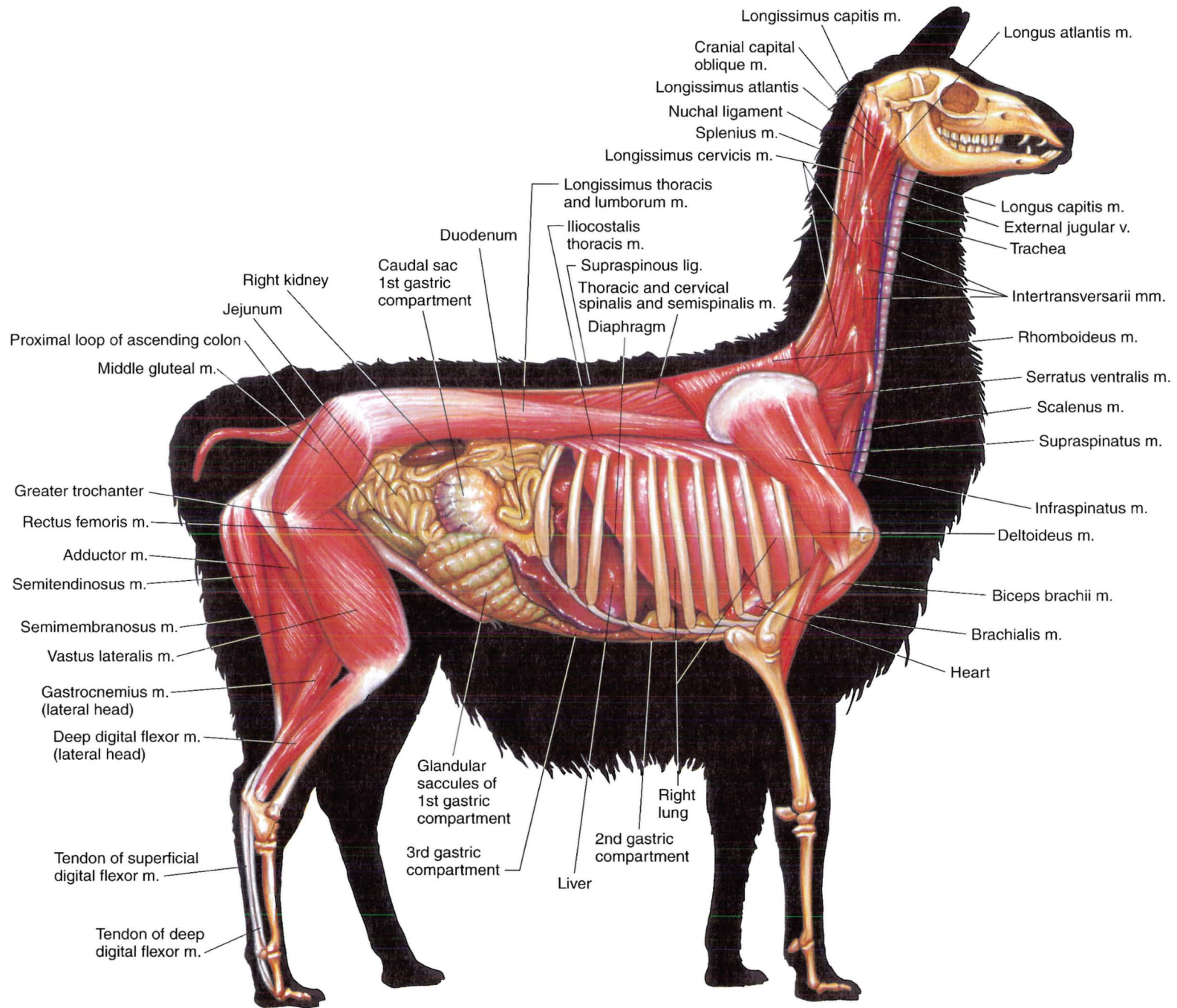
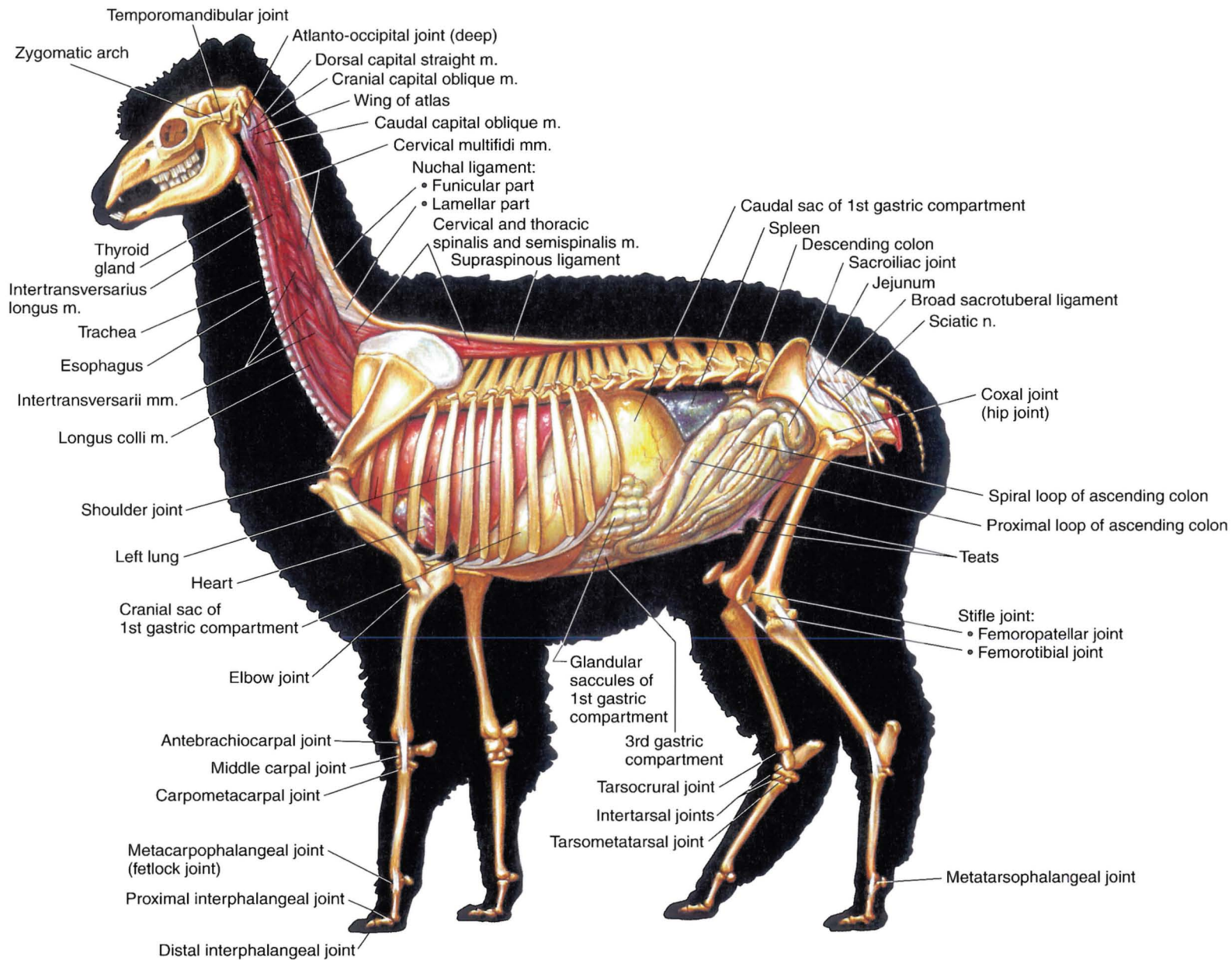
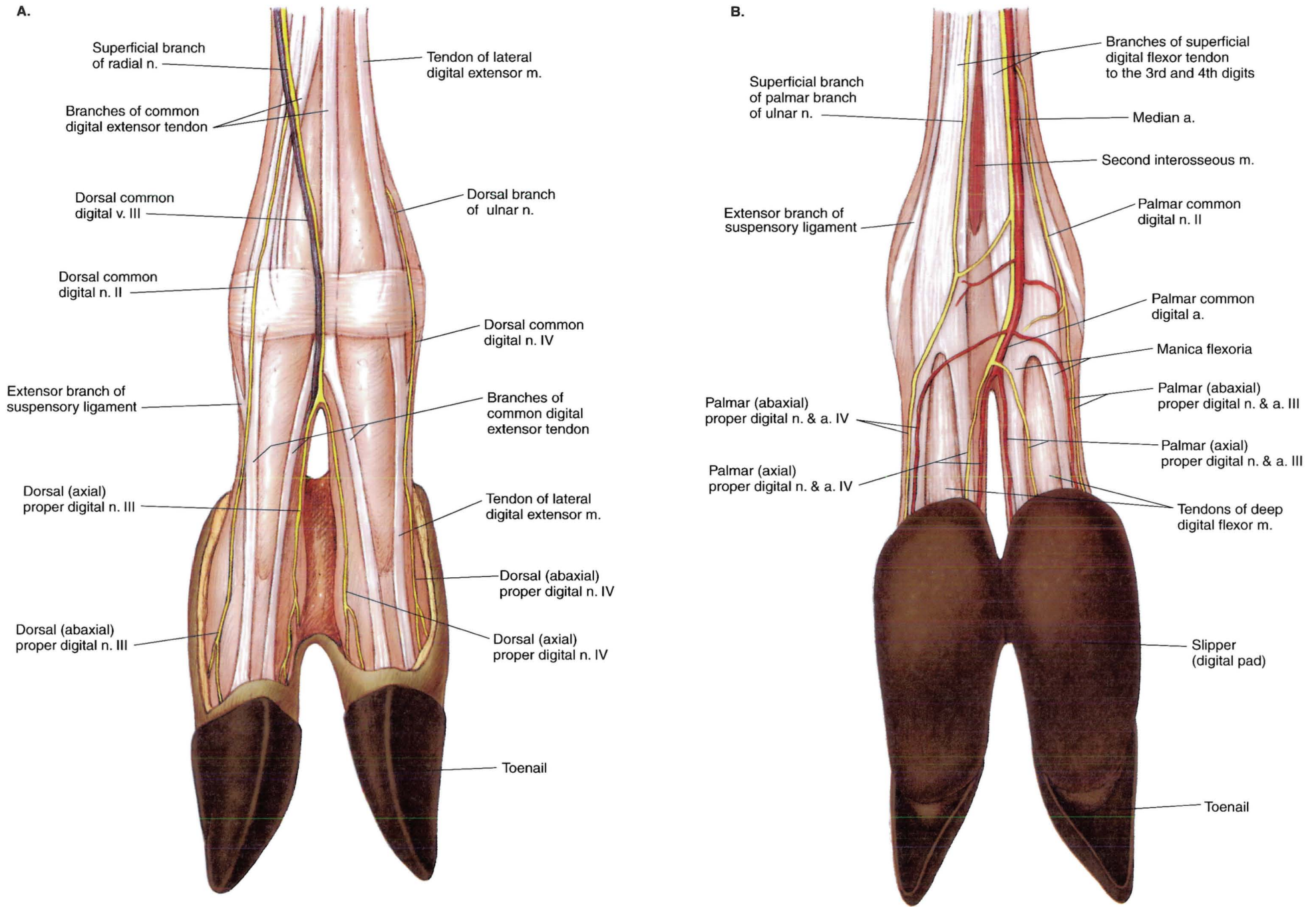


PLATE 5.7 Deep muscles and *in situ* viscera of the male llama. Omentum is removed. Right lateral view. m = muscle, v = vein, lig = ligament



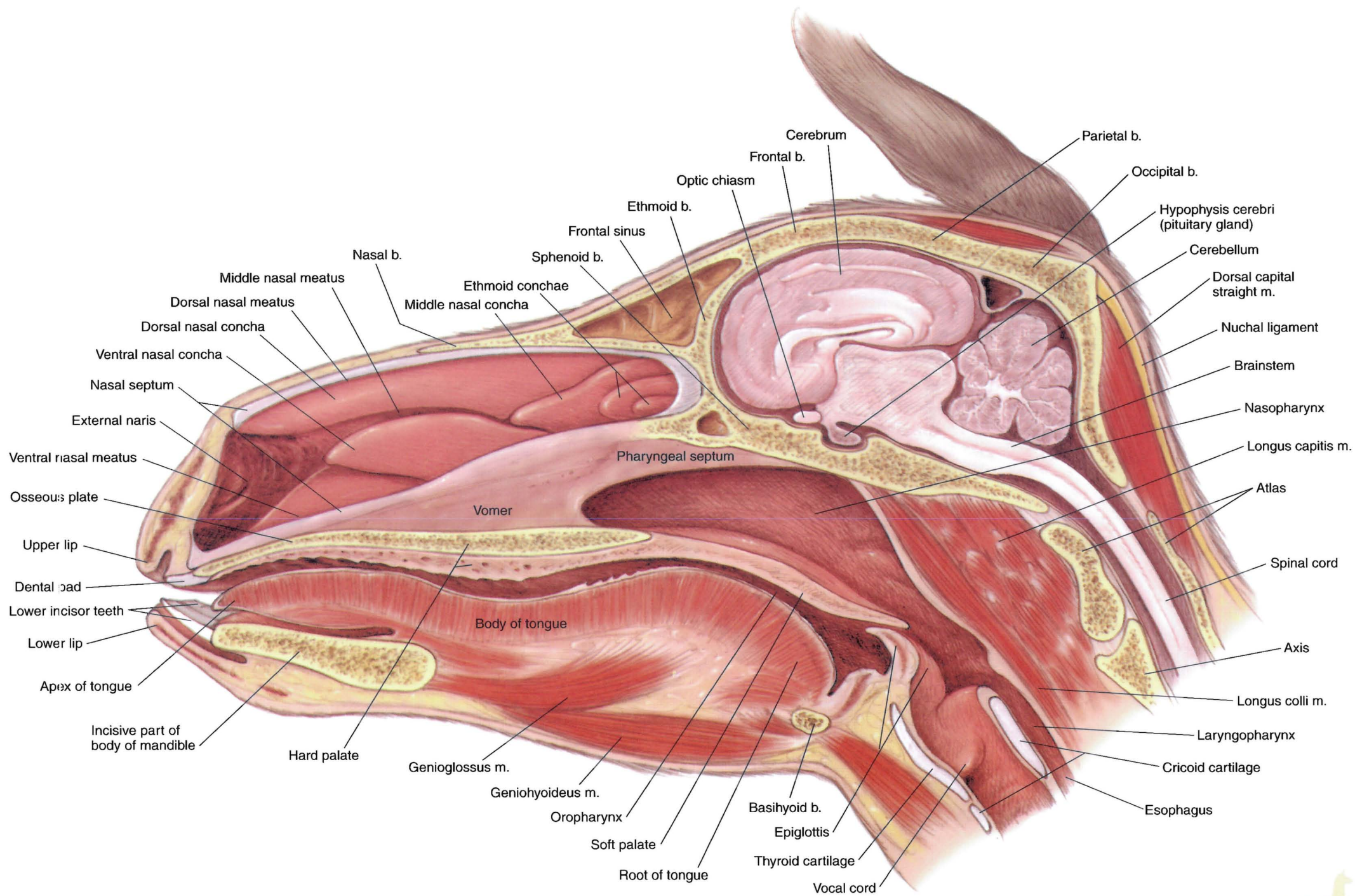


**PLATE 5.8** Deep cervical muscles, *in situ* viscera, and major joints of the female alpaca. The omentum is removed. Left lateral view. m = muscle




**PLATE 5.9** Major structures of the lamoid left distal metacarpus and digits. **A.** Dorsal view. **B.** Palmar view. n = nerve, v = vein, m = muscle, a = artery



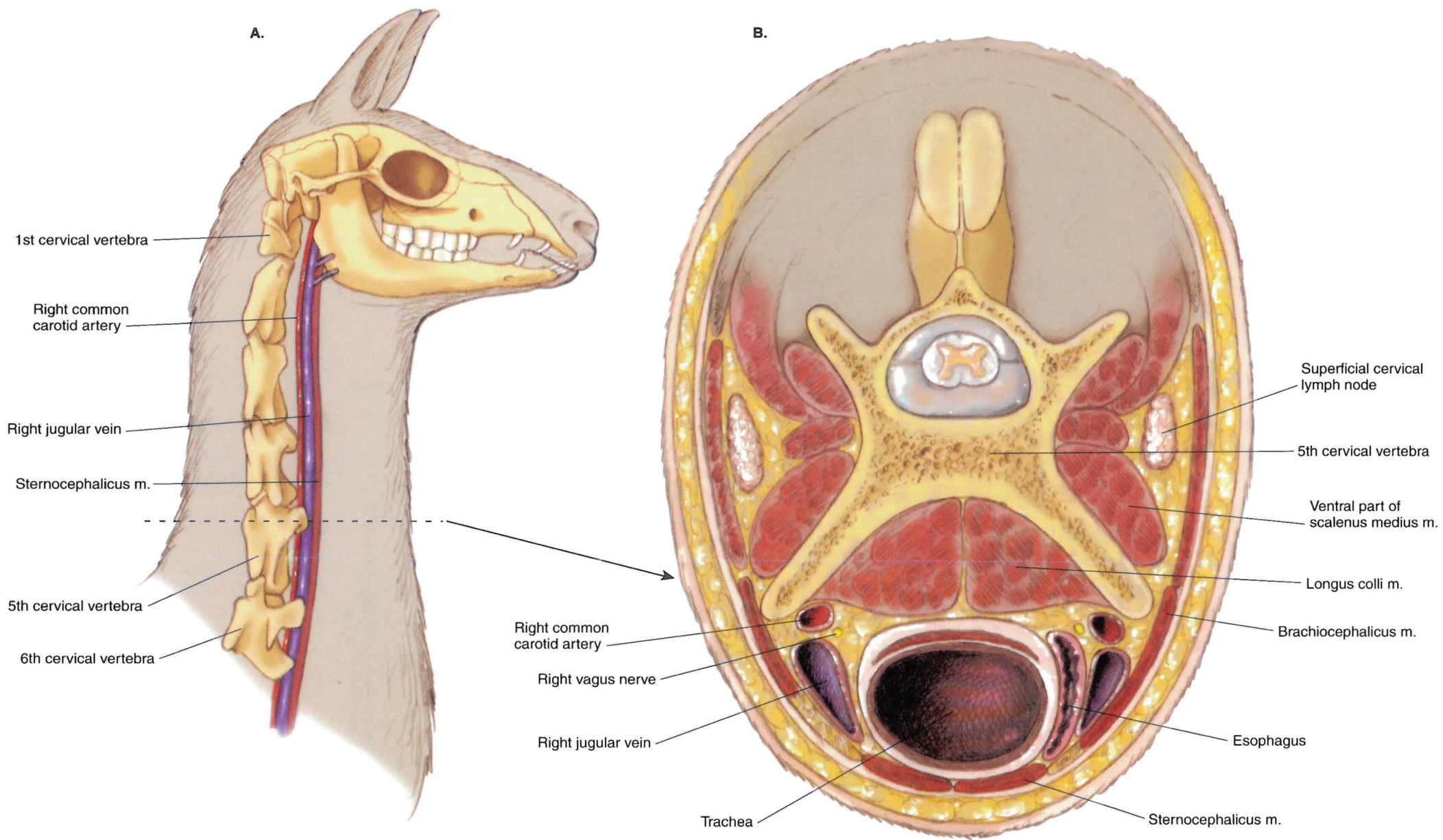


**PLATE 5.10** Median section of the llama's head. Most of the nasal septum is removed. b = bone, m = muscle

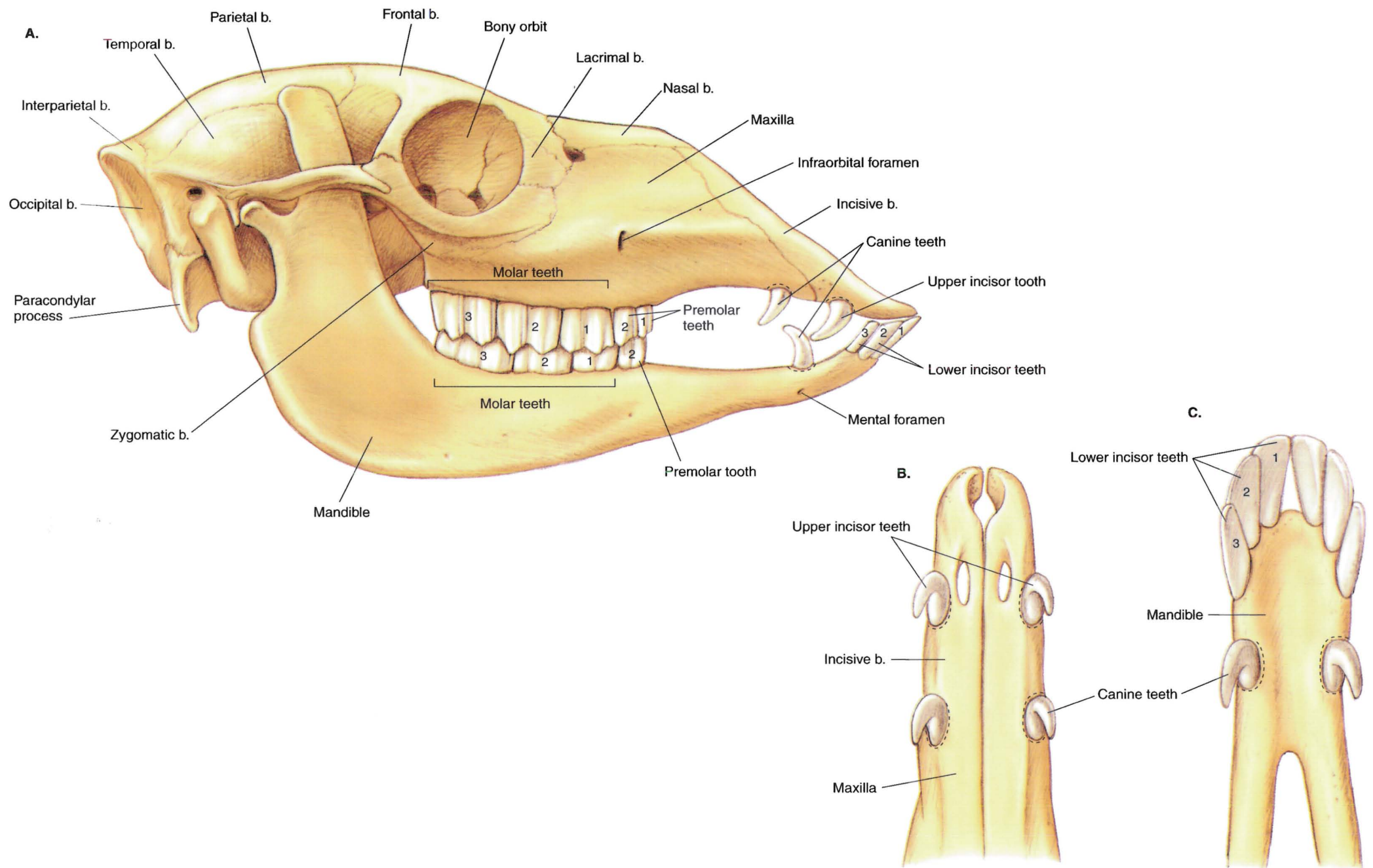


**PLATE 5.11** A. Proper placement of a halter on a llama's head. B. Improper placement of a halter. Pressure on the nostrils interferes with breathing.





**PLATE 5.12** Relations of the llama's common carotid artery and jugular vein. **A.** Right lateral view of the head and neck. **B.** Cross-section through the neck at the level of the 5th cervical vertebra. m = muscle



**PLATE 5.13** Dentition of the male llama. **A.** Right lateral view of the skull and crowns of permanent teeth *in situ*. **B.** Ventral view of the crowns of the upper incisor and canine teeth. **C.** Dorsal view of the crowns of the lower incisor and canine teeth. *Dashed lines* indicate the plane of sectioning (2–3 mm above the gum [gingival] line) for cutting off the crowns of deciduous or erupting permanent canine and upper incisor teeth. b = bone



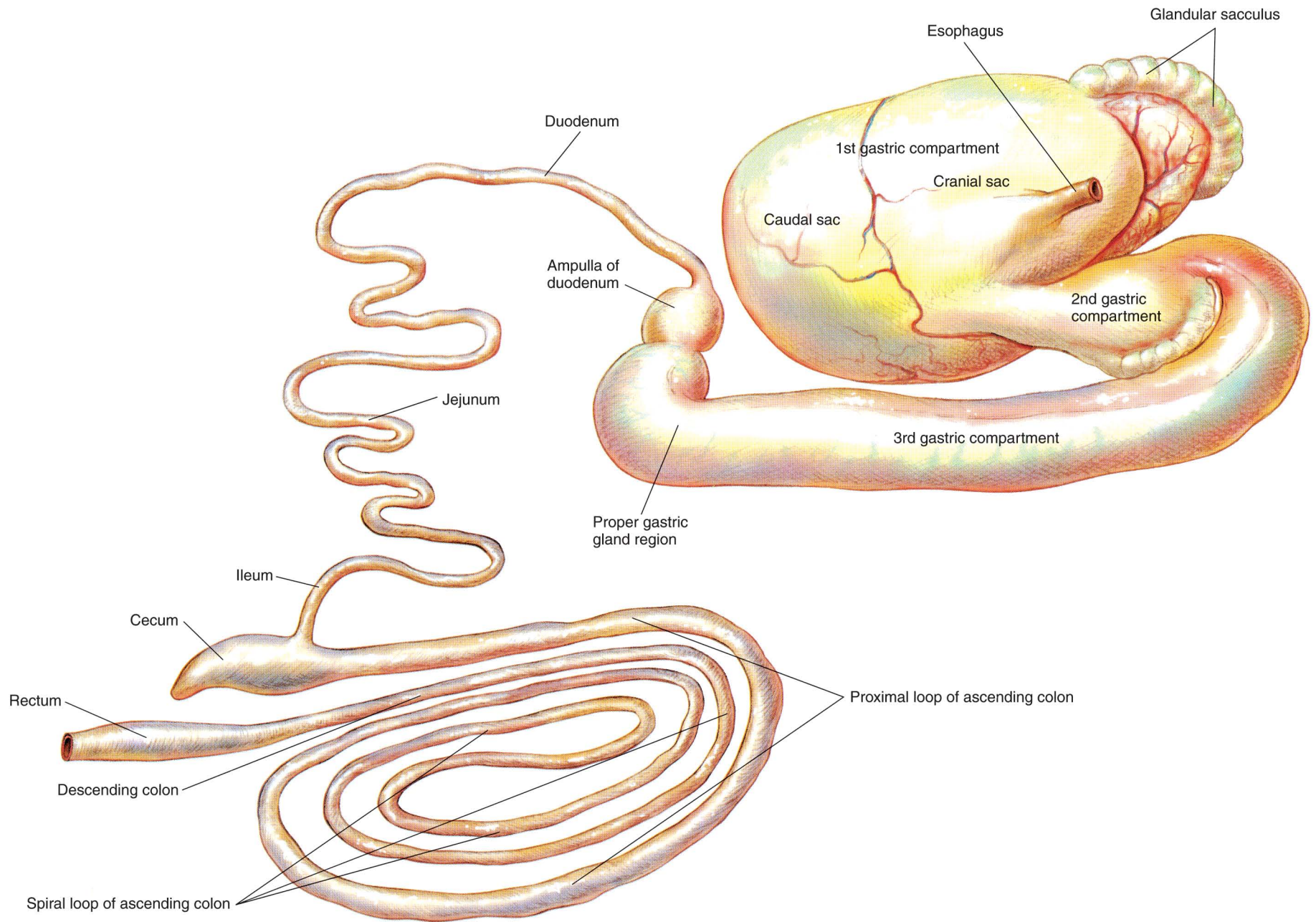
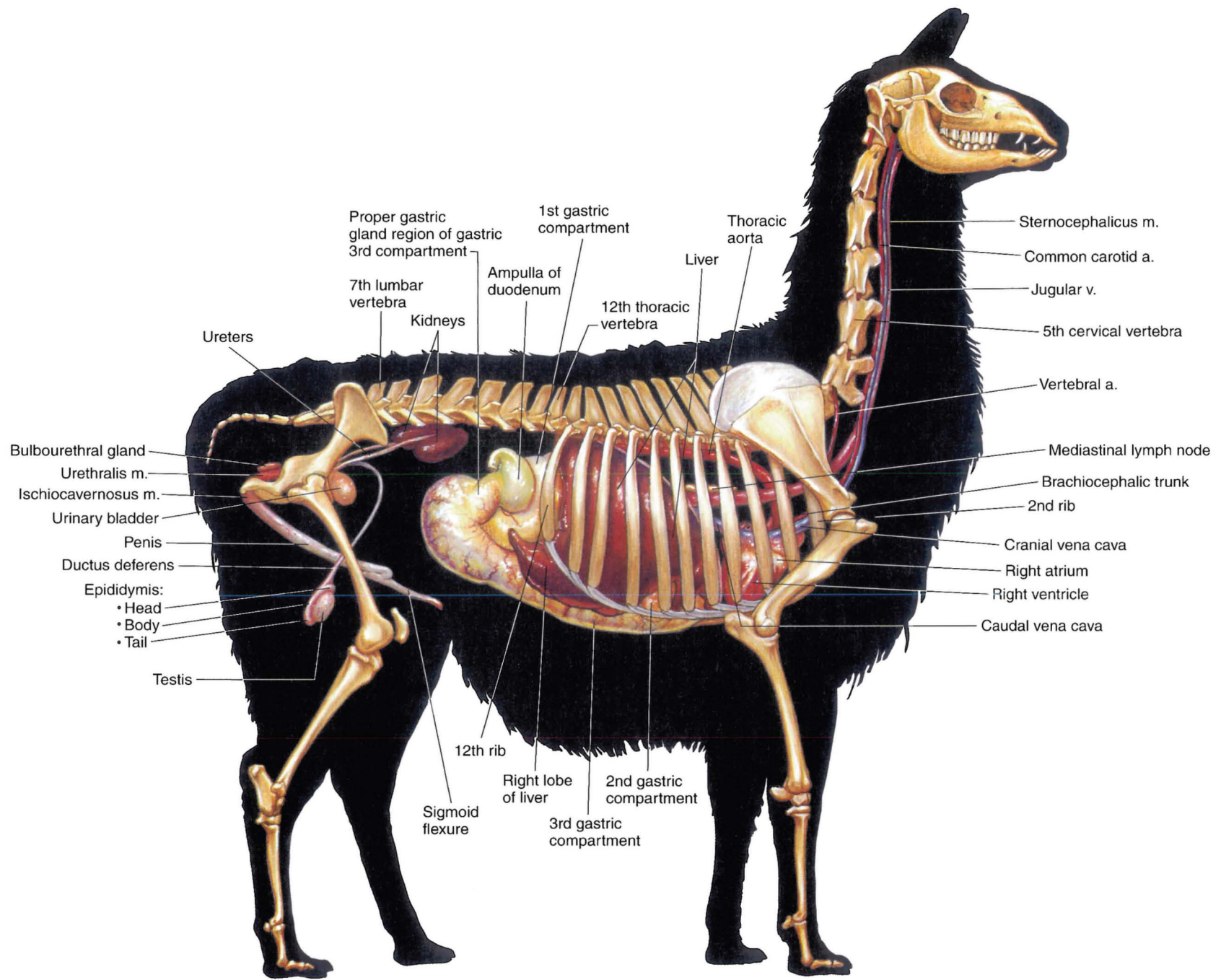
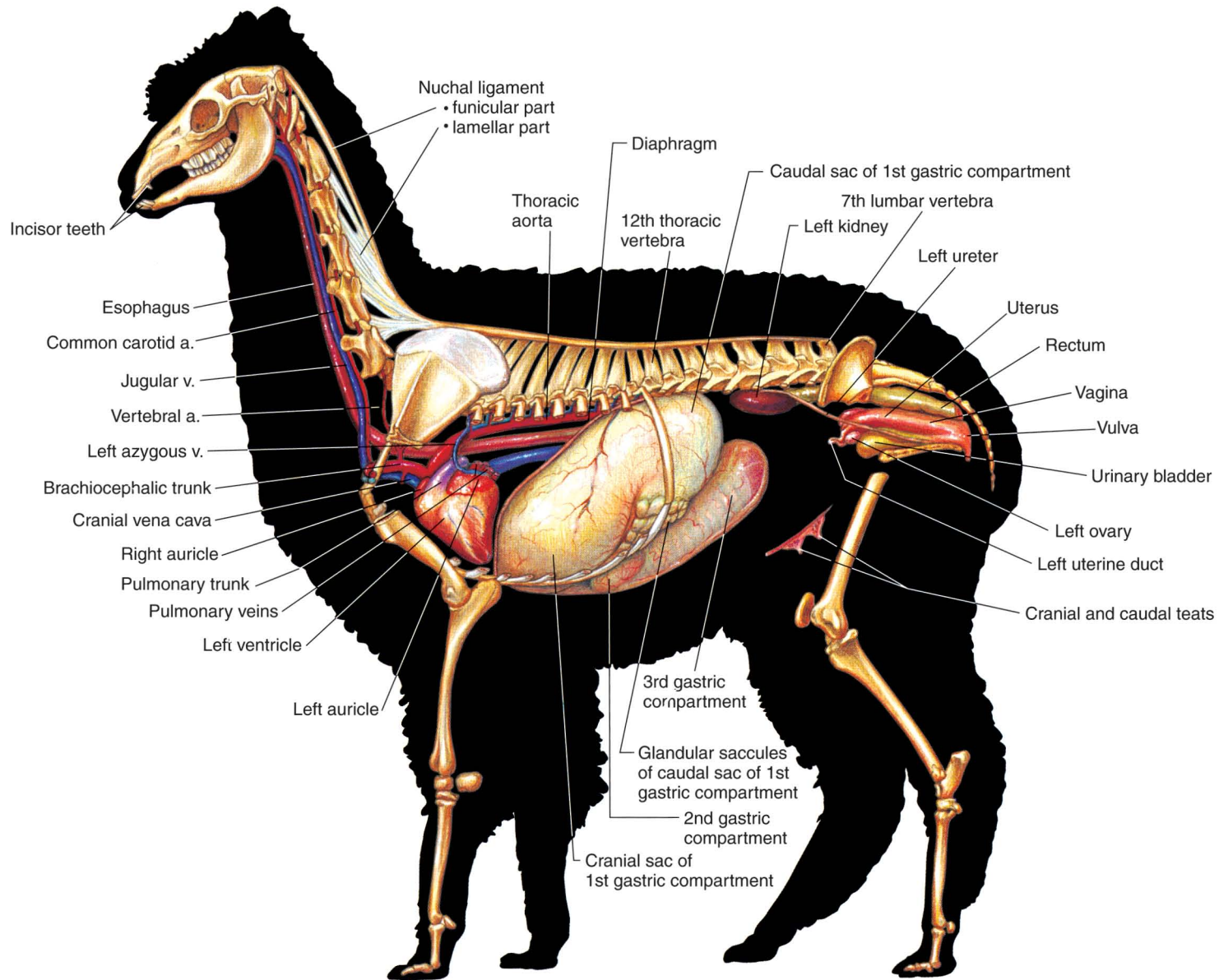


PLATE 5.14 Isolated stomach and intestines of the male llama. Jejunum is shortened.

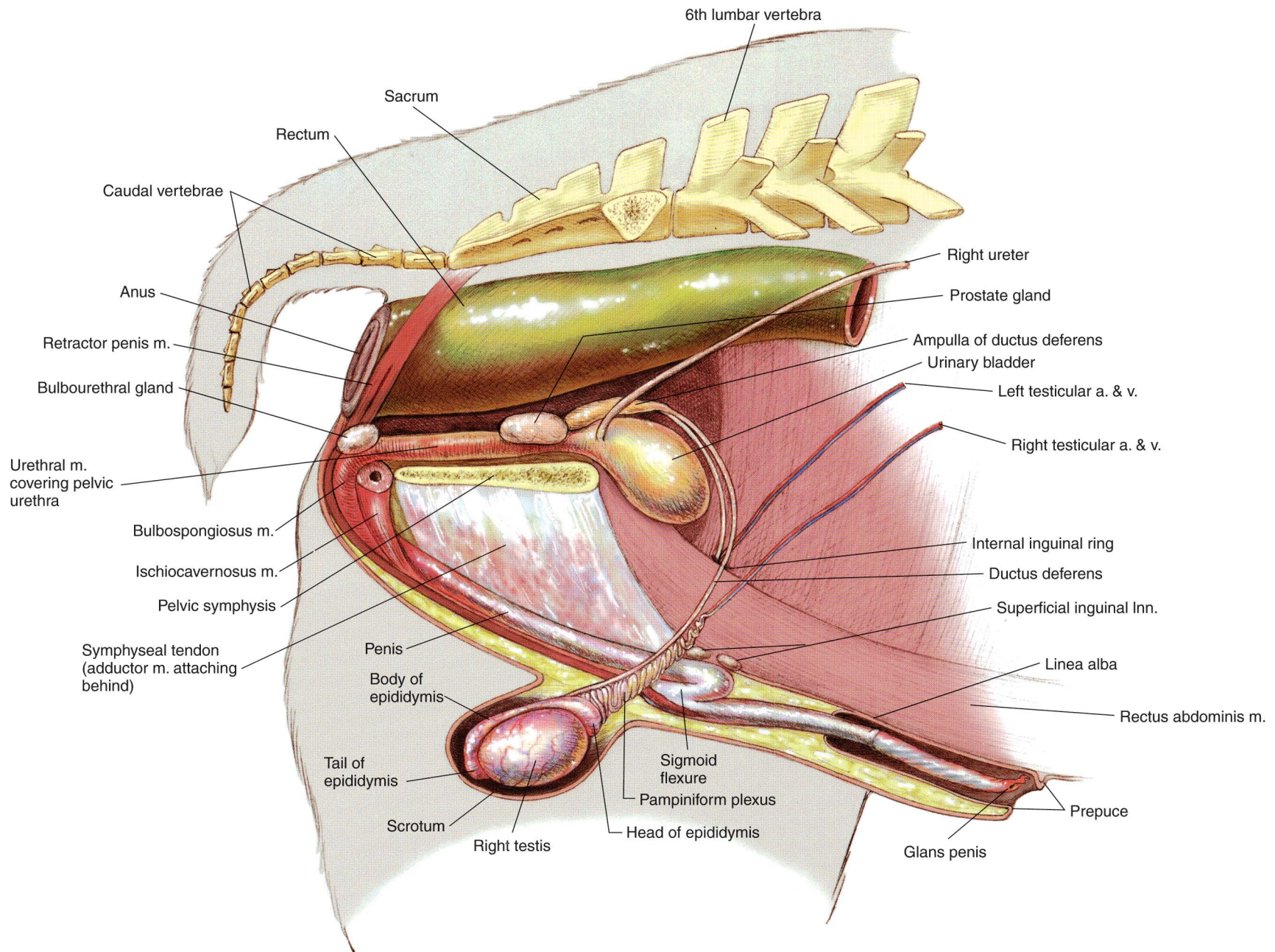


**PLATE 5.15** Reproductive and urinary organs, stomach, liver, heart, and adjacent major vessels related to the skeleton of the male llama. Lungs and intestines are removed.  
 Right lateral view. v = vein, a = artery, m = muscle



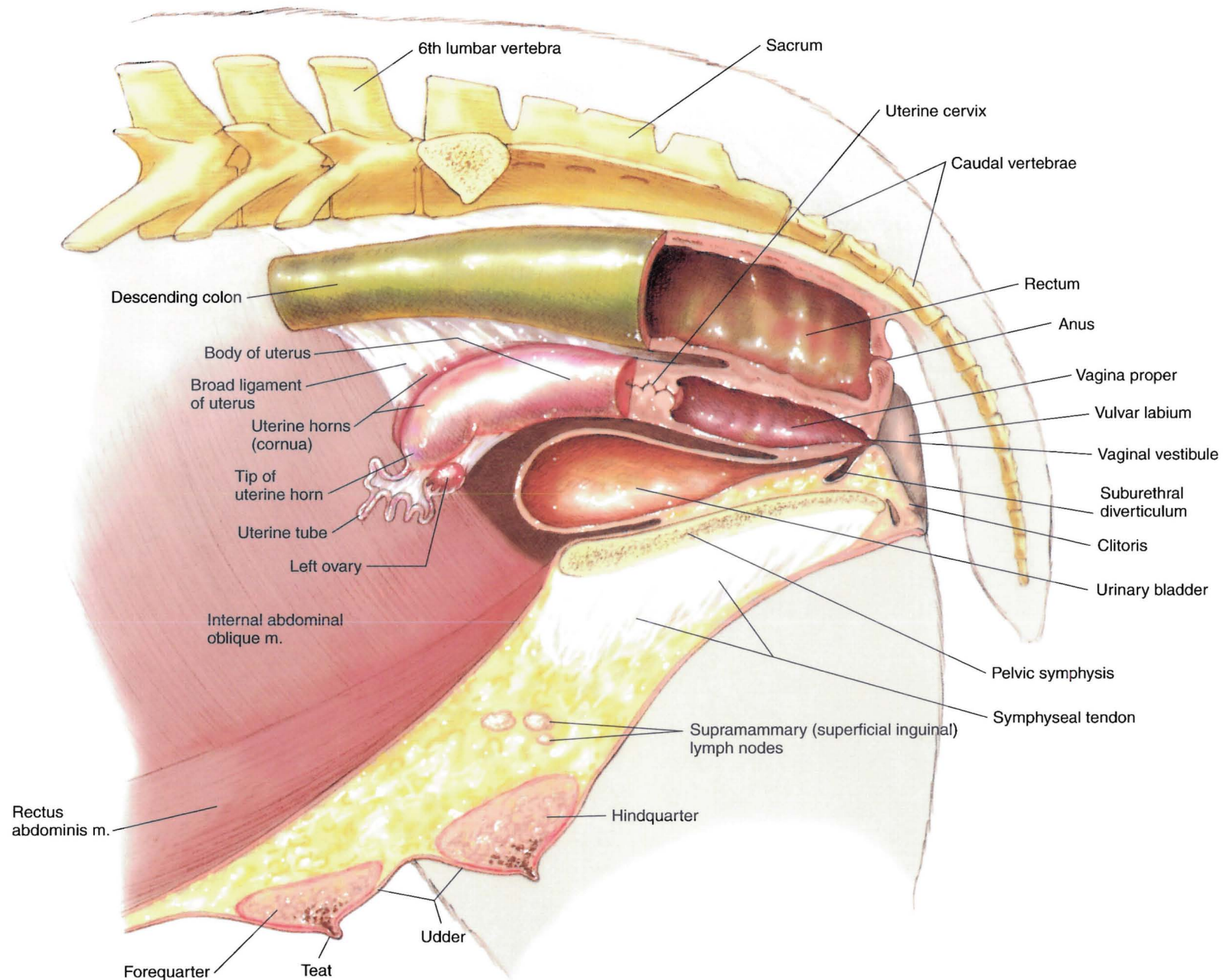


**PLATE 5.16** Reproductive and urinary organs, stomach, heart, and adjacent major vessels of the female alpaca. Lungs and intestines are removed. Left lateral view. a = artery, v = vein



**PLATE 5.17** Relations of the reproductive organs of the male llama. Right lateral view.  
 m = muscle, Inn = lymph nodes, v = vein, a = artery






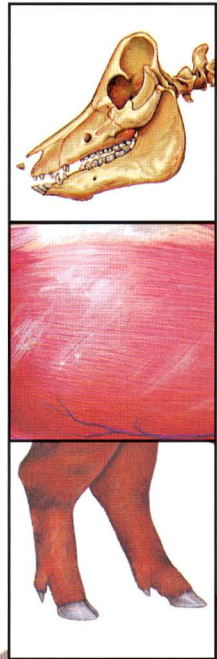
**PLATE 5.18** Relations of the reproductive organs of the female alpaca.  
Partial median section. Left lateral view. m = muscle





# SECTION 6 THE SWINE (*Sus scrofa domestica*)

## P L A T E S



- 6.1 Right lateral view of a boar.
- 6.2 Left lateral view of a sow.
- 6.3 Carcass cuts of the hog.
- 6.4 Skeleton of the swine.
- 6.5 Cutaneous and superficial muscles of the boar.
- 6.6 Superficial muscles of the sow.
- 6.7 Deep muscles and *in situ* viscera of the boar.
- 6.8 Deep cervical muscles, major joints, and *in situ* viscera of the sow.
- 6.9 Median section of the porcine head.
- 6.10 A. Permanent dentition of the boar.  
B. Cutting the deciduous incisor and canine teeth of a piglet.
- 6.11 Isolated stomach and intestines of the swine.
- 6.12 Lymph nodes and vessels of the sow.
- 6.13 Reproductive and urinary organs, stomach, liver, heart, and adjacent major vessels related to the skeleton of the boar.
- 6.14 Reproductive and urinary organs, abdominal viscera, spleen, heart, and adjacent major vessels of the sow.
- 6.15 Relations of the reproductive organs of the boar.
- 6.16 Relations of the reproductive organs of the sow.



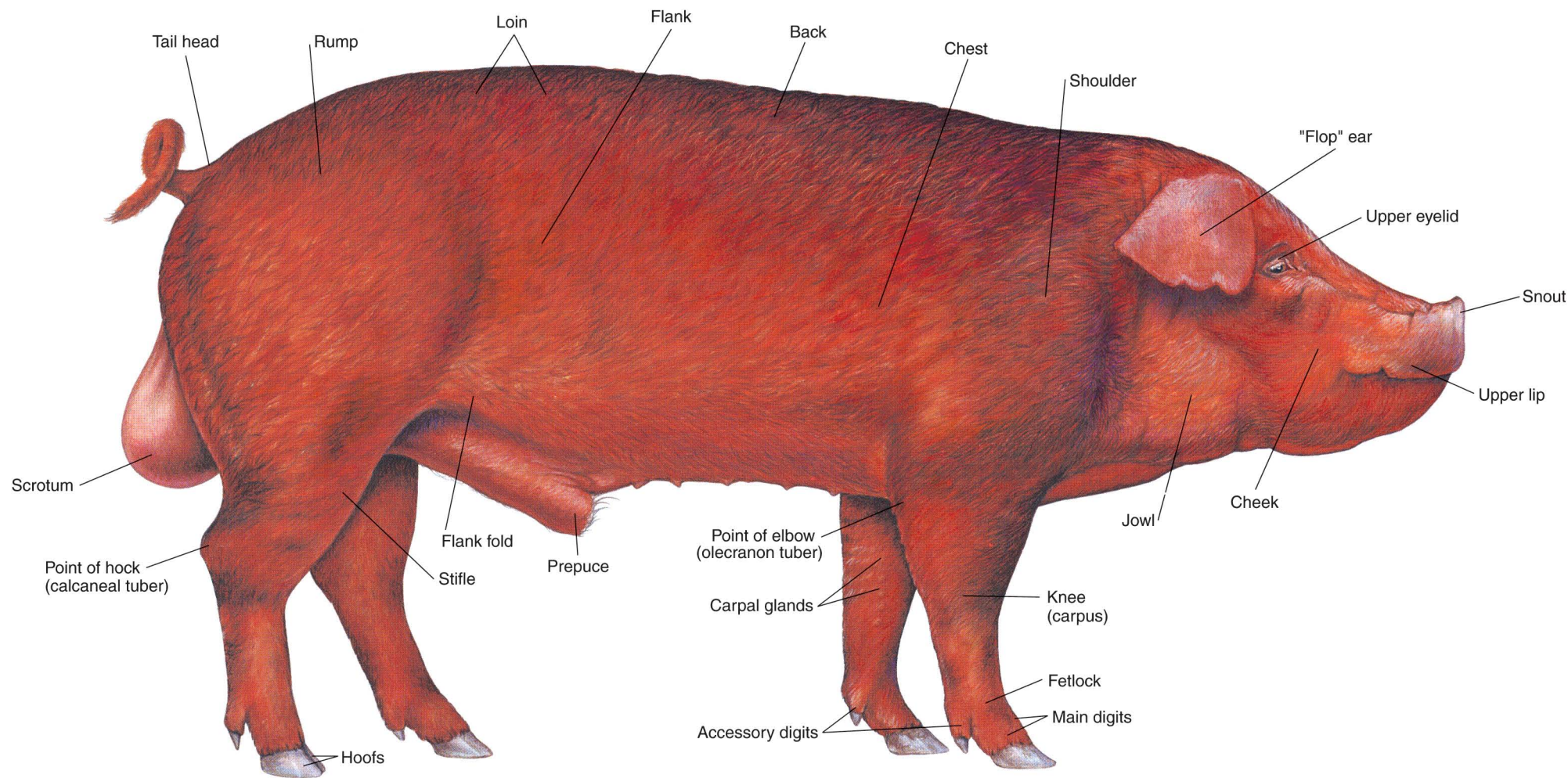


PLATE 6.1 Right lateral view of a boar.



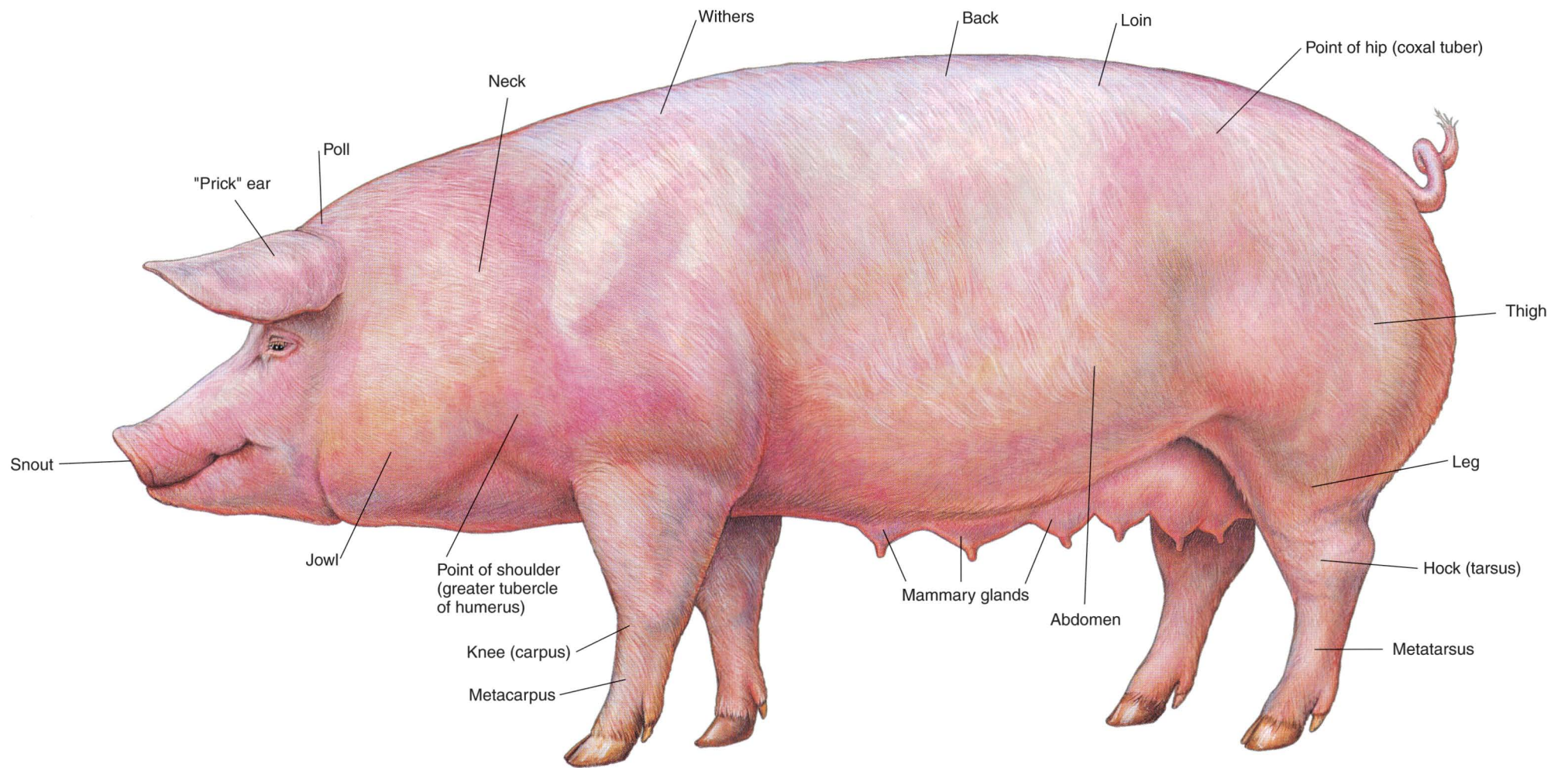


PLATE 6.2 Left lateral view of a sow.

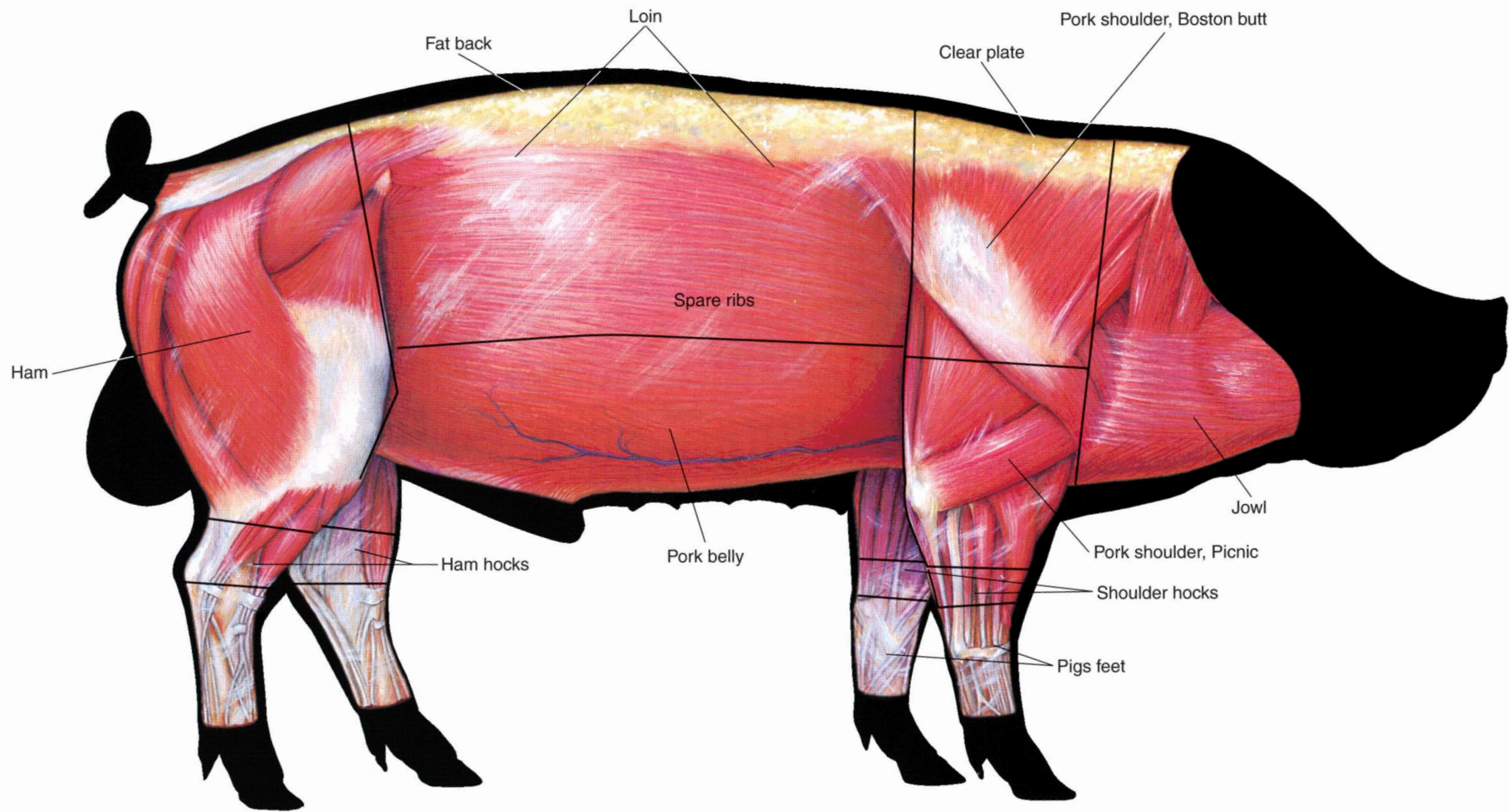


PLATE 6.3 Carcass cuts of the hog.



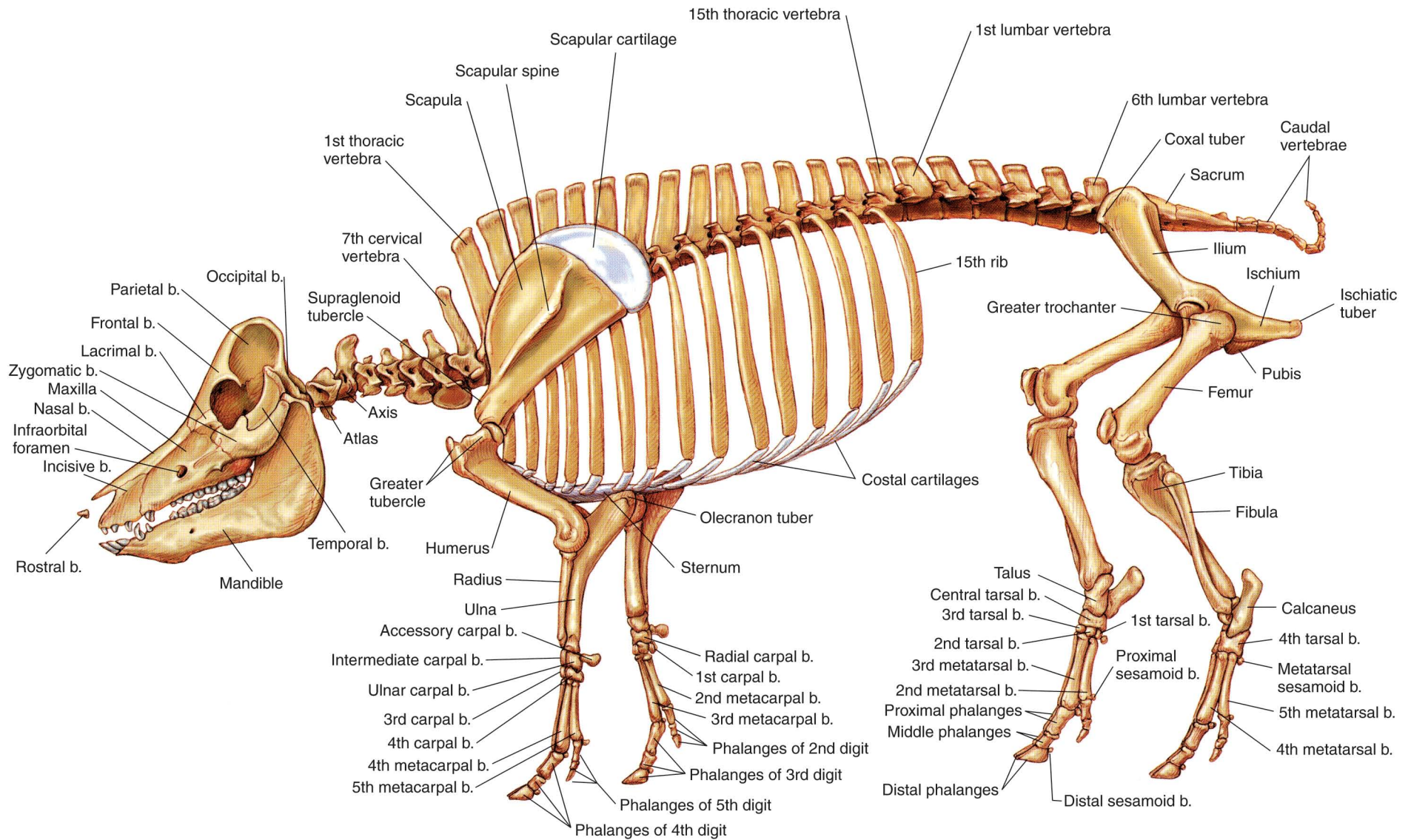
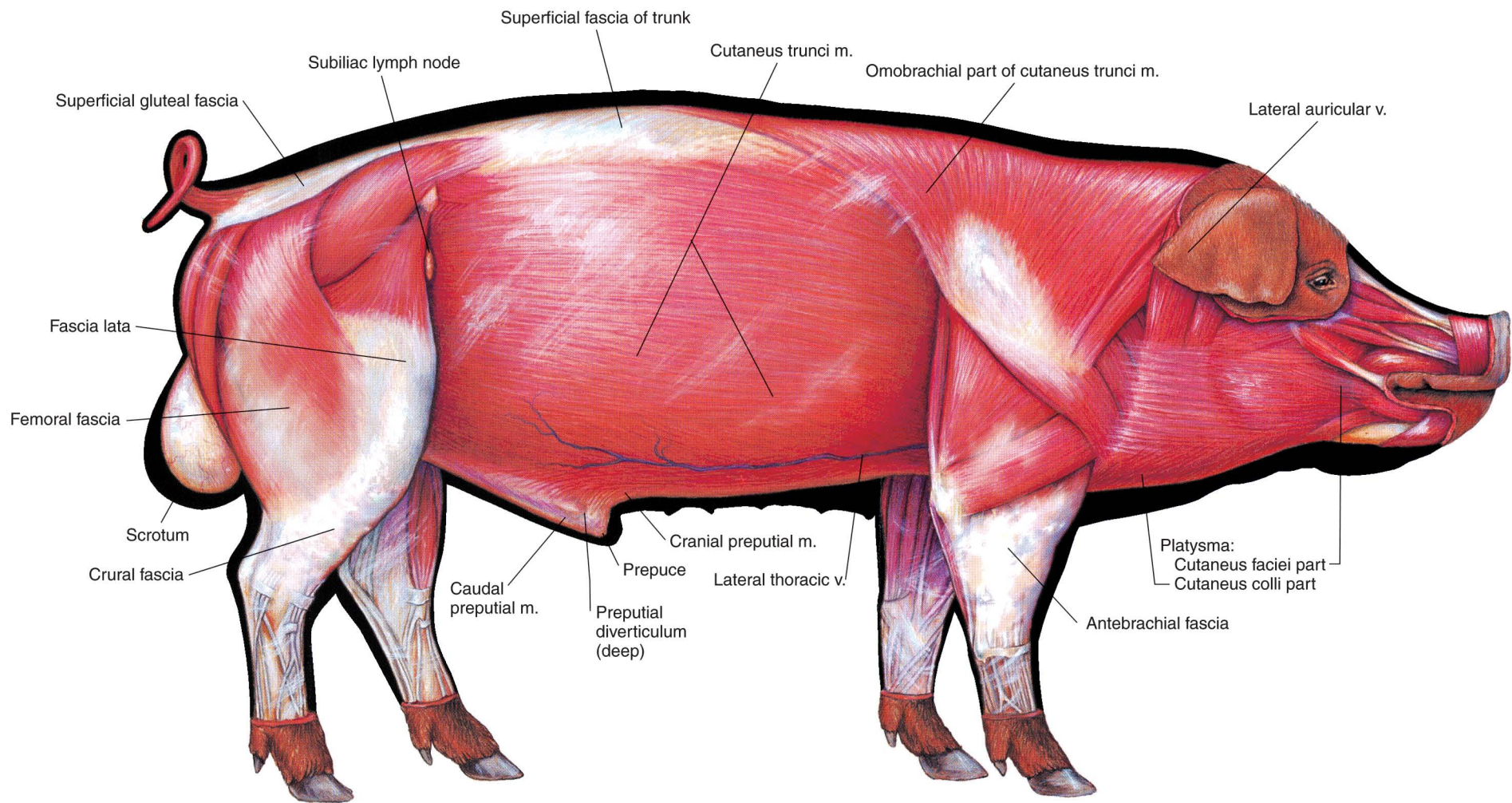
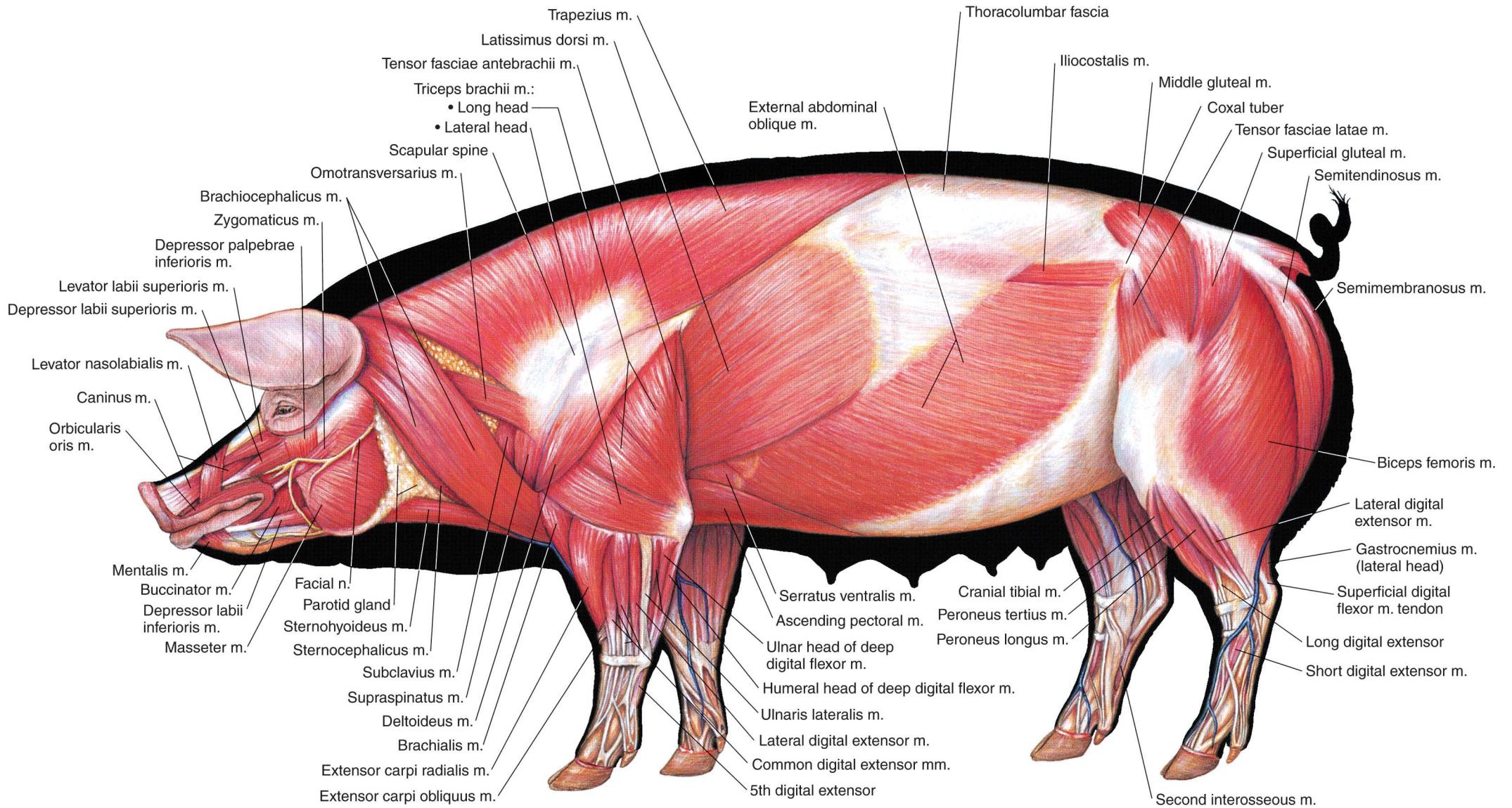


PLATE 6.4 Skeleton of the swine. b = bone



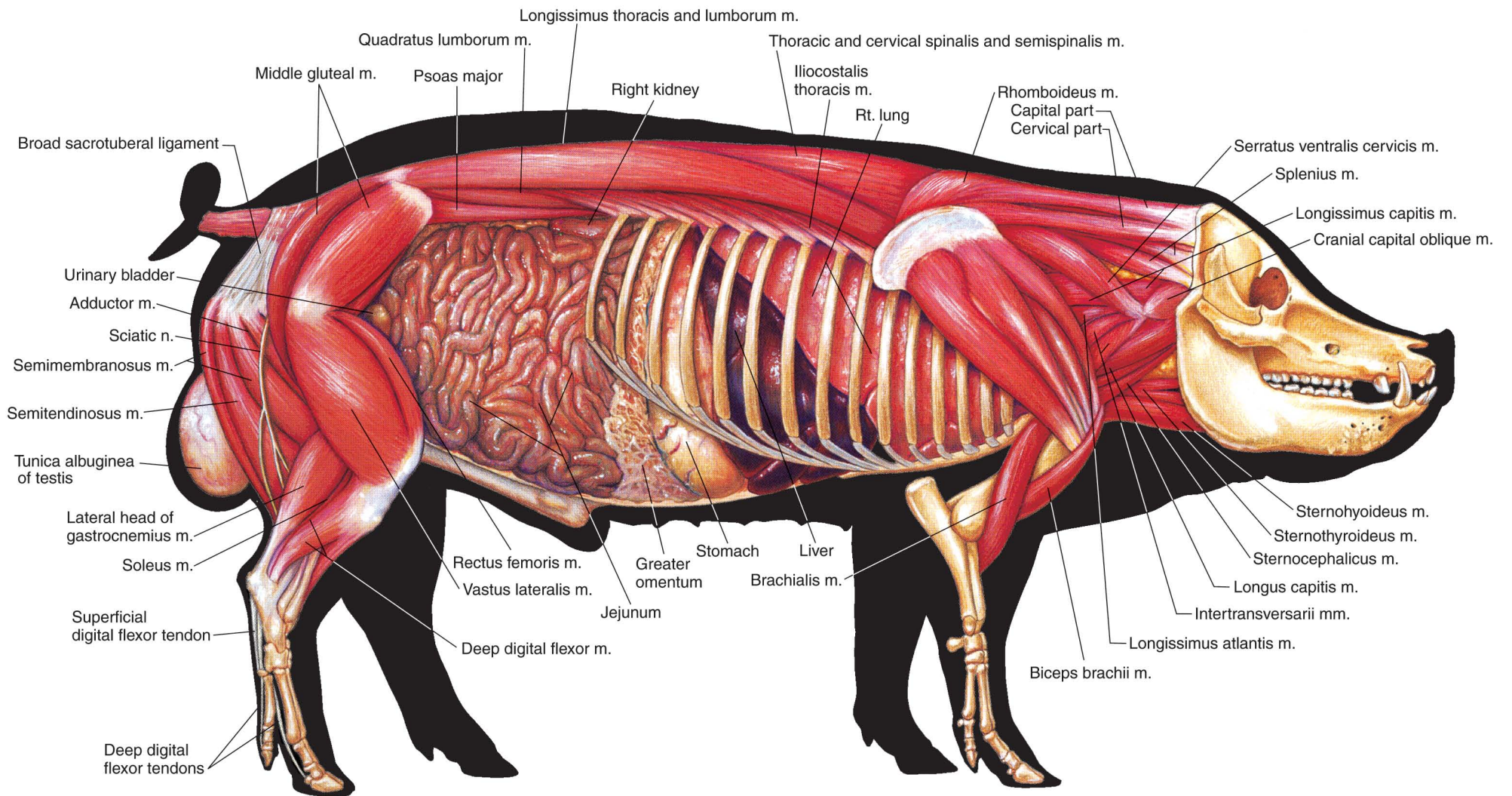
**PLATE 6.5** Cutaneous and superficial muscles of the boar. Panniculus adiposus (fat layer) removed. Right lateral view. v = vein, m = muscle





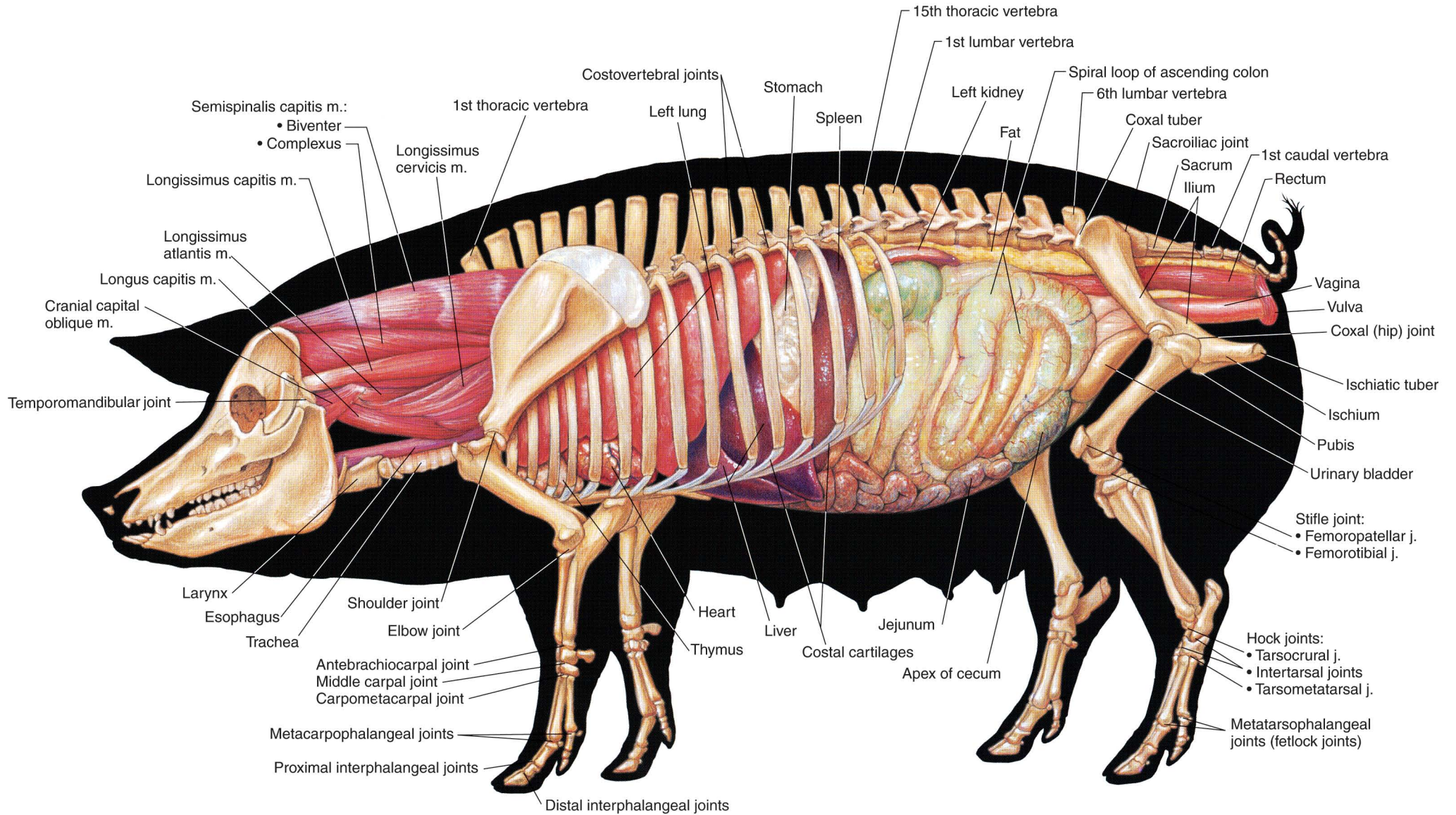
**PLATE 6.6** Superficial muscles of the sow. Left lateral view. m = muscle, n = nerve





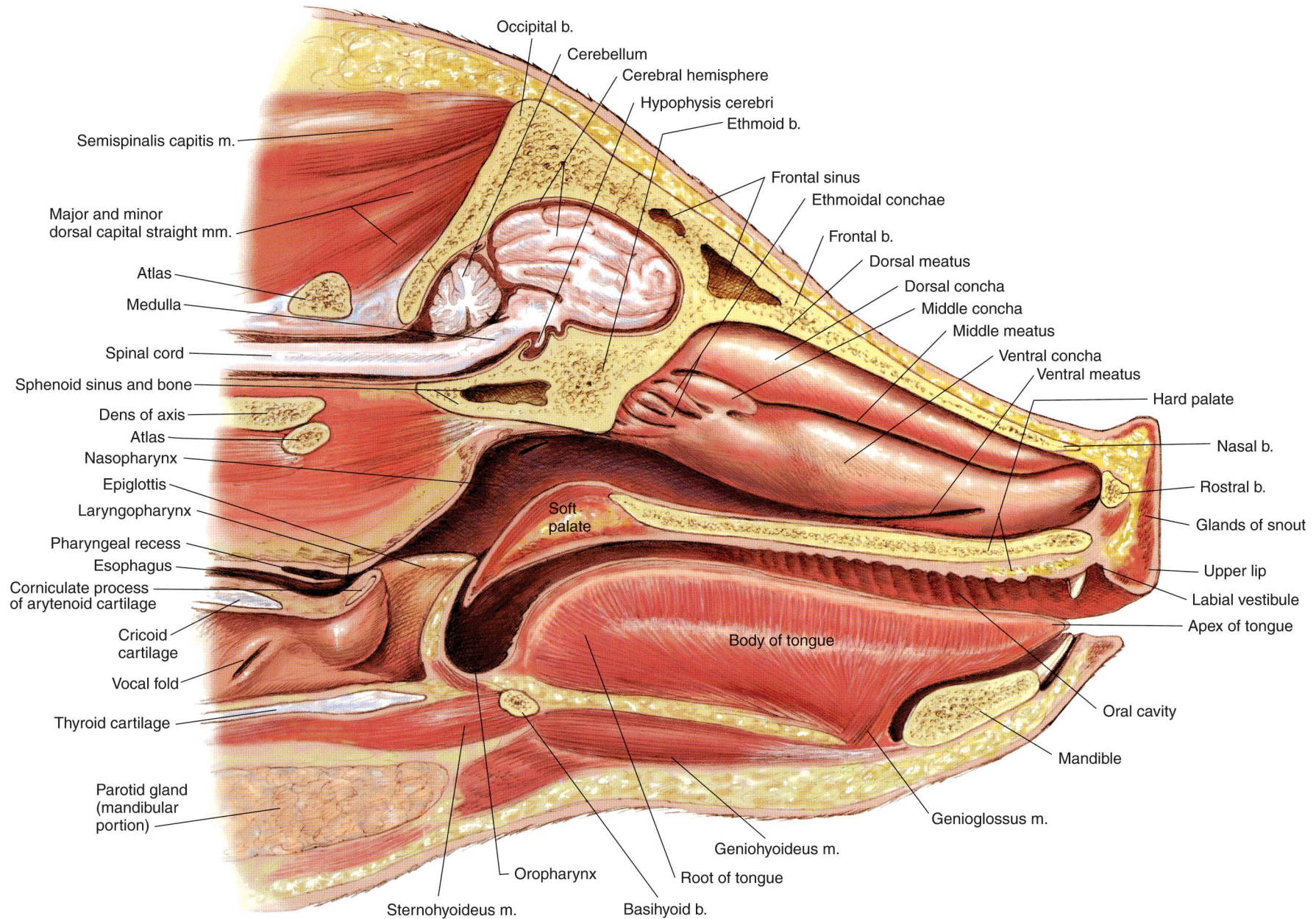
**PLATE 6.7** Deep muscles and *in situ* viscera of the boar.  
 Right lateral view. m = muscle, n = nerve





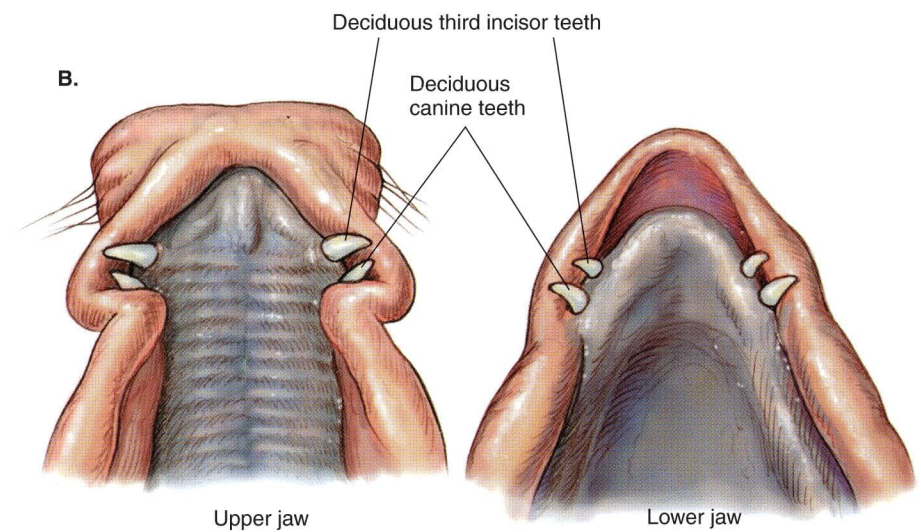
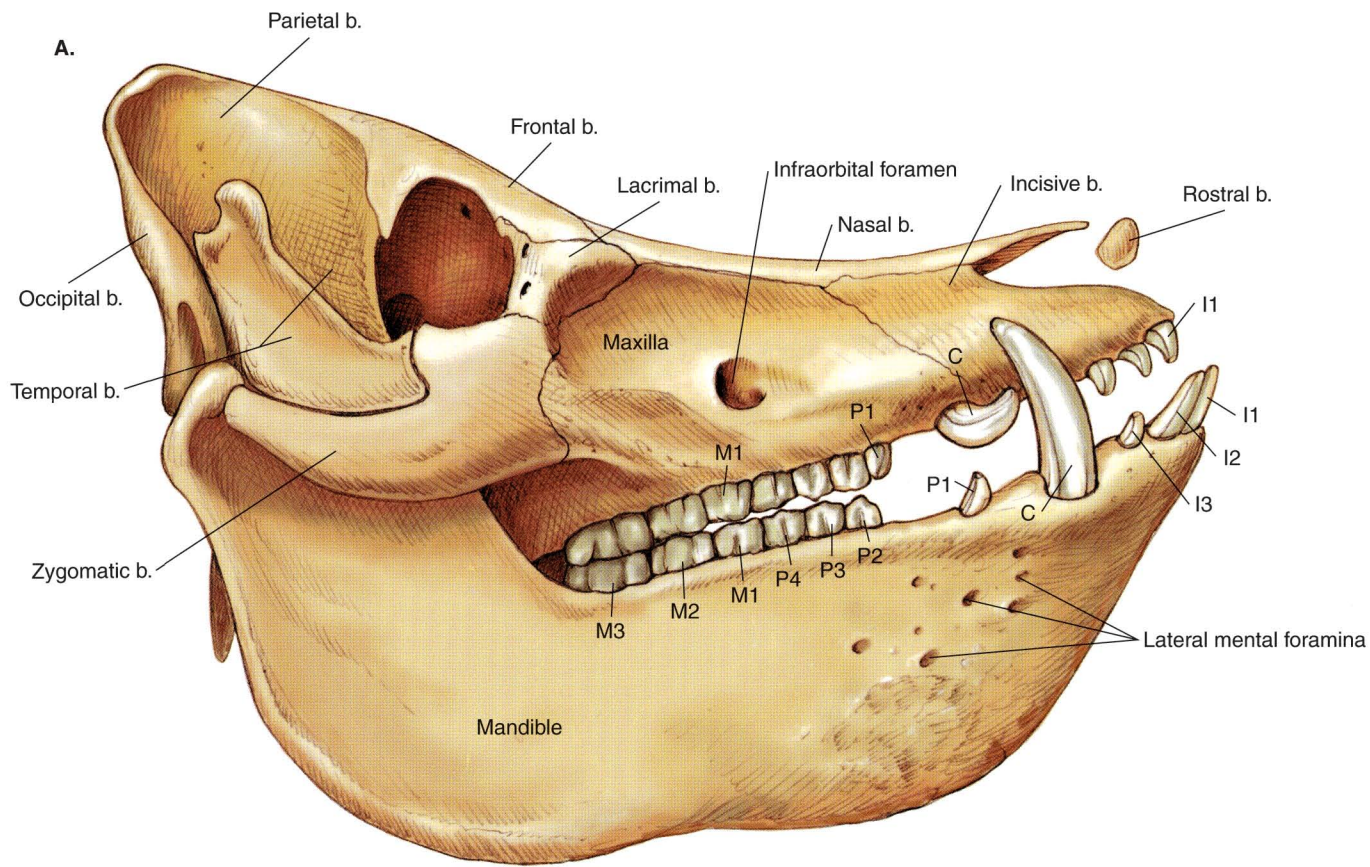
**PLATE 6.8** Deep cervical muscles, major joints, and *in situ* viscera of the sow. Left lateral view. m = muscle, j = joint





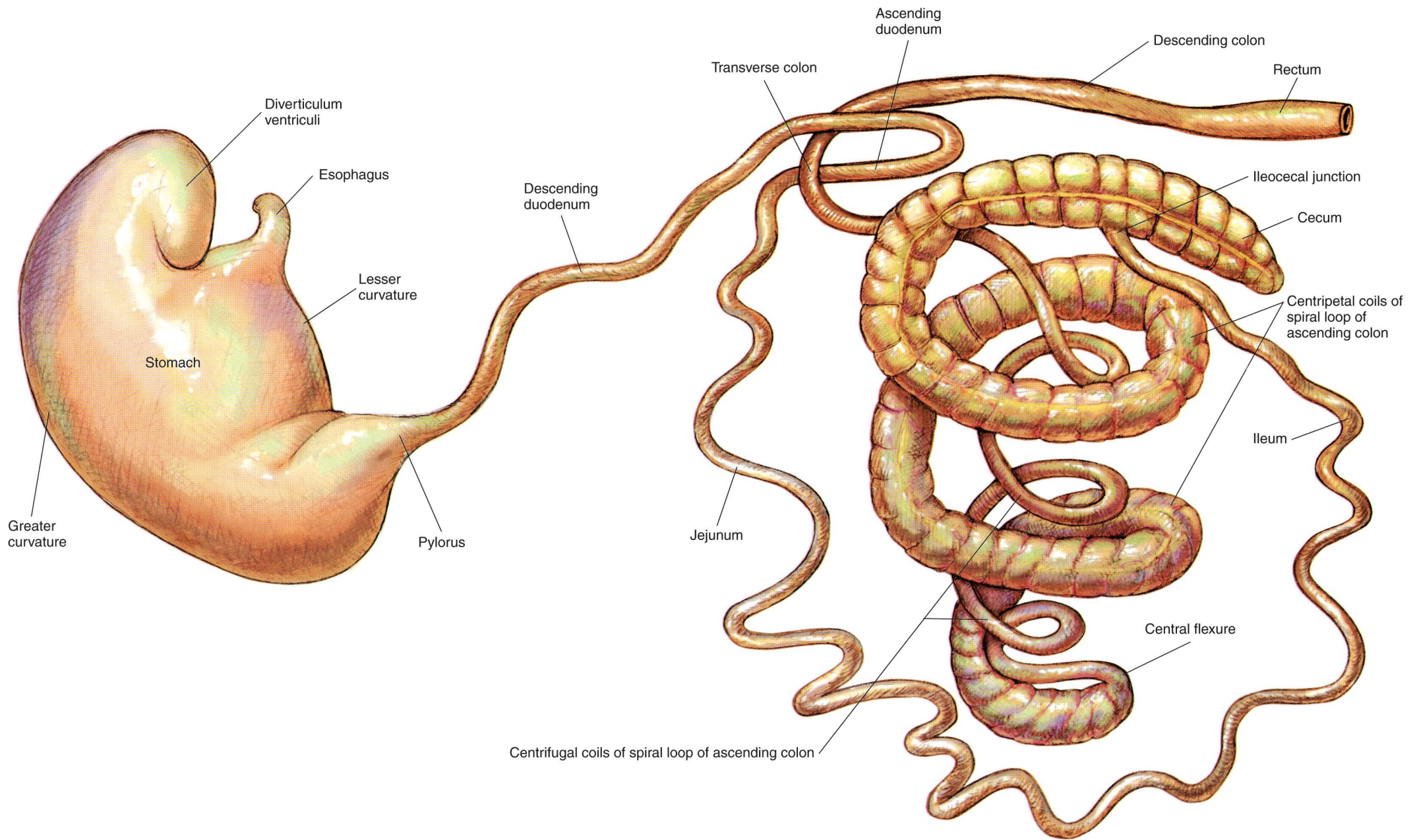
**PLATE 6.9** Median section of the porcine head. The nasal septum has been removed. Right lateral view. m = muscle, b = bone





**PLATE 6.10** **A.** Permanent dentition of the boar. b = bone, I = incisor tooth, C = canine tooth, P = premolar tooth, M = molar tooth **B.** Cutting the deciduous incisor and canine teeth of a piglet. They are routinely cut off to prevent damage to sow's teats.





**PLATE 6.11** Isolated stomach and intestines of the swine. The jejunum is shortened and uncoiled, and the loops of the ascending colon are pulled apart.



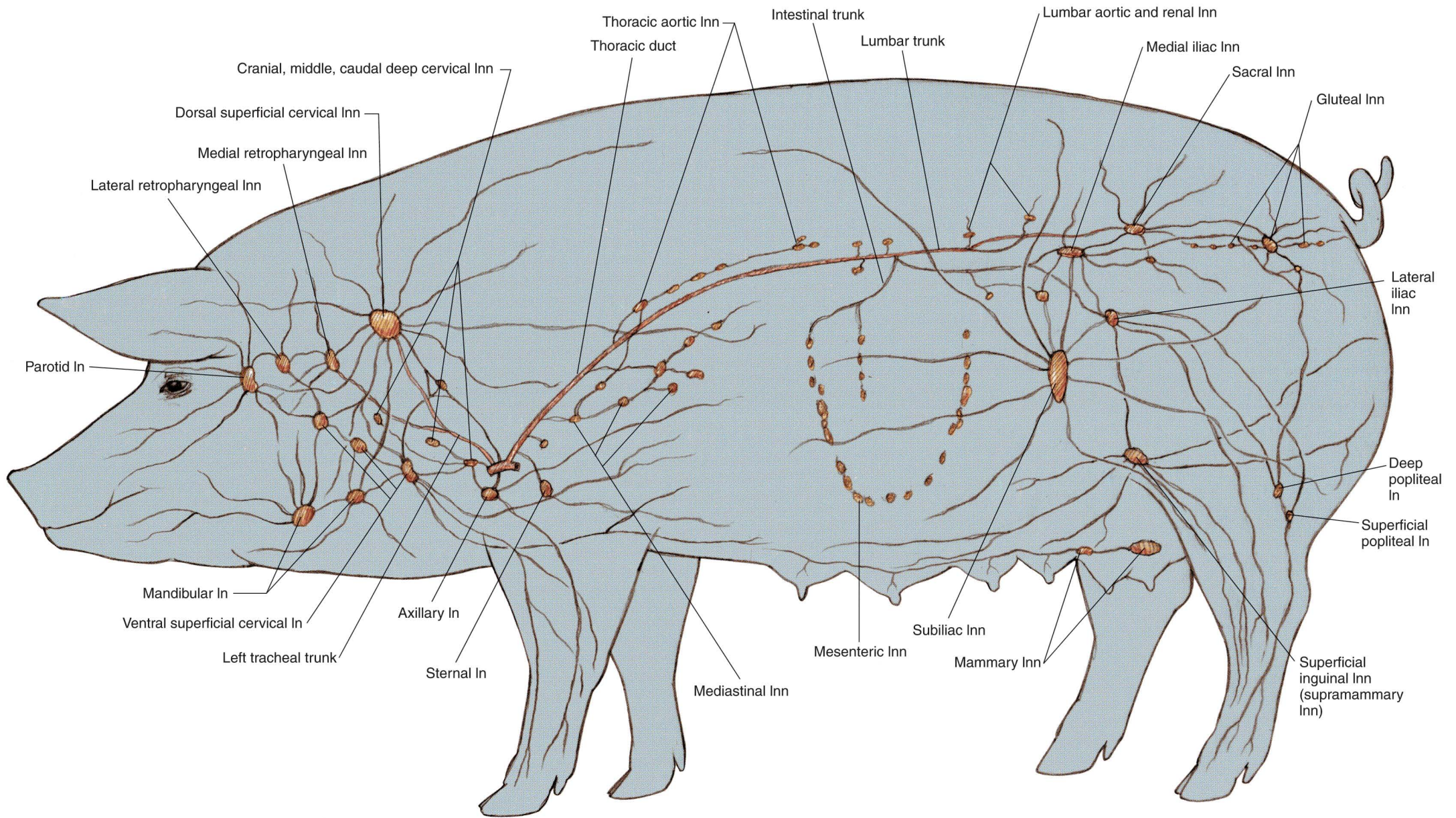
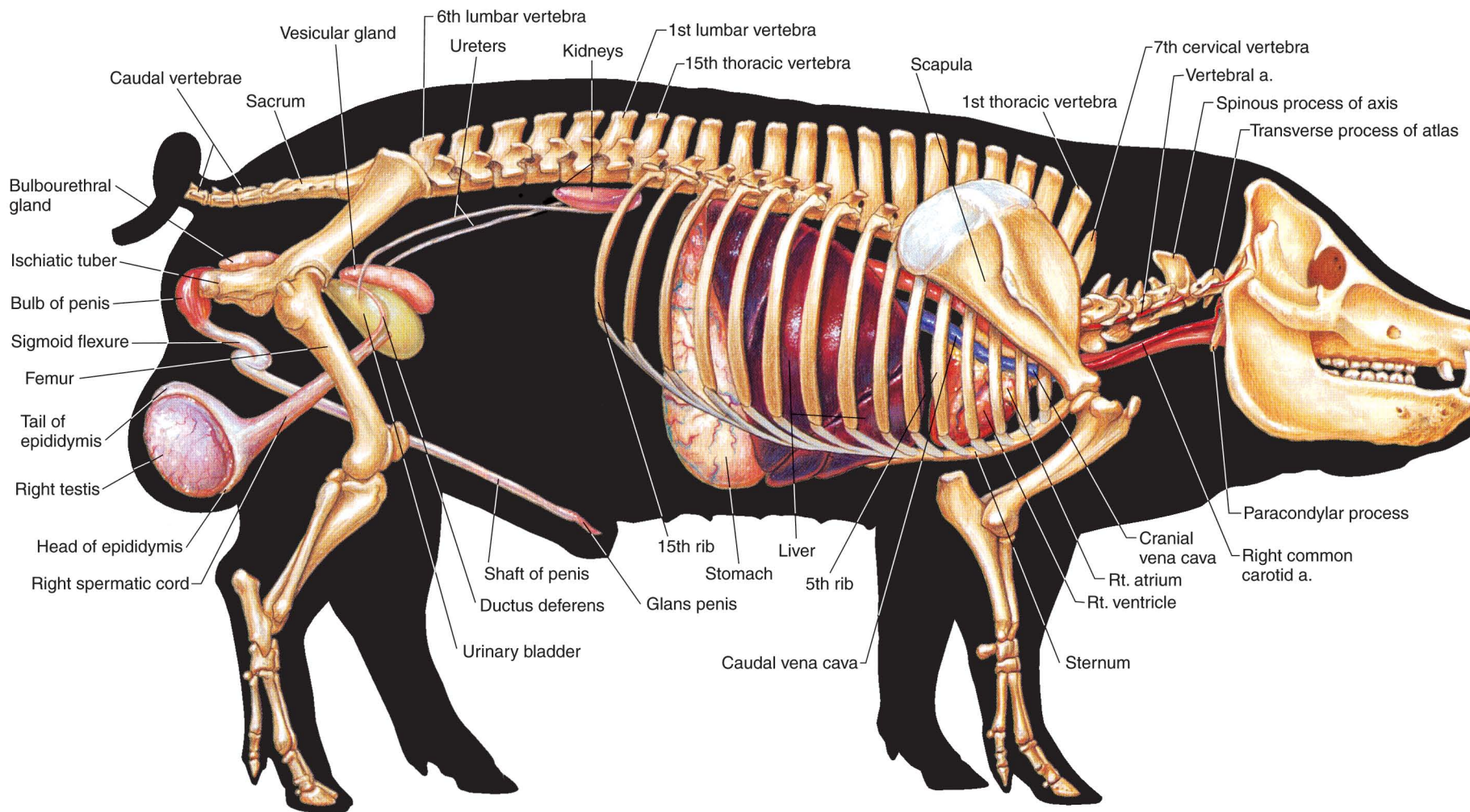


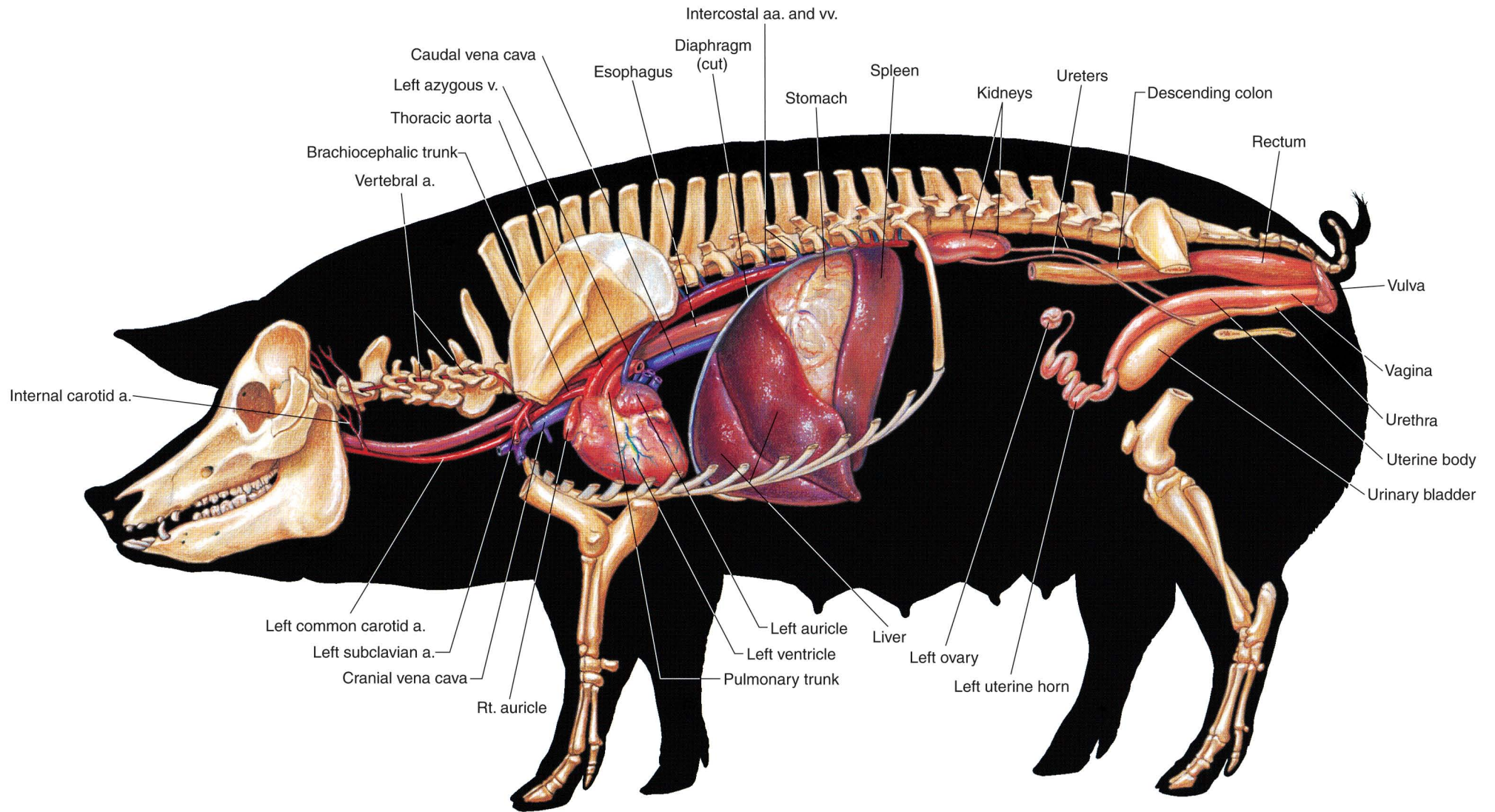
PLATE 6.12 Lymph nodes and vessels of the sow. In = lymph node





**PLATE 6.13** Reproductive and urinary organs, stomach, liver, heart, and adjacent major vessels related to the skeleton of the boar. Lungs and intestines are removed. Right lateral view. a = artery





**PLATE 6.14** Reproductive and urinary organs, abdominal viscera, spleen, heart, and adjacent major vessels of the sow. Lungs and intestines are removed.  
 Left lateral view. v = vein, a = artery

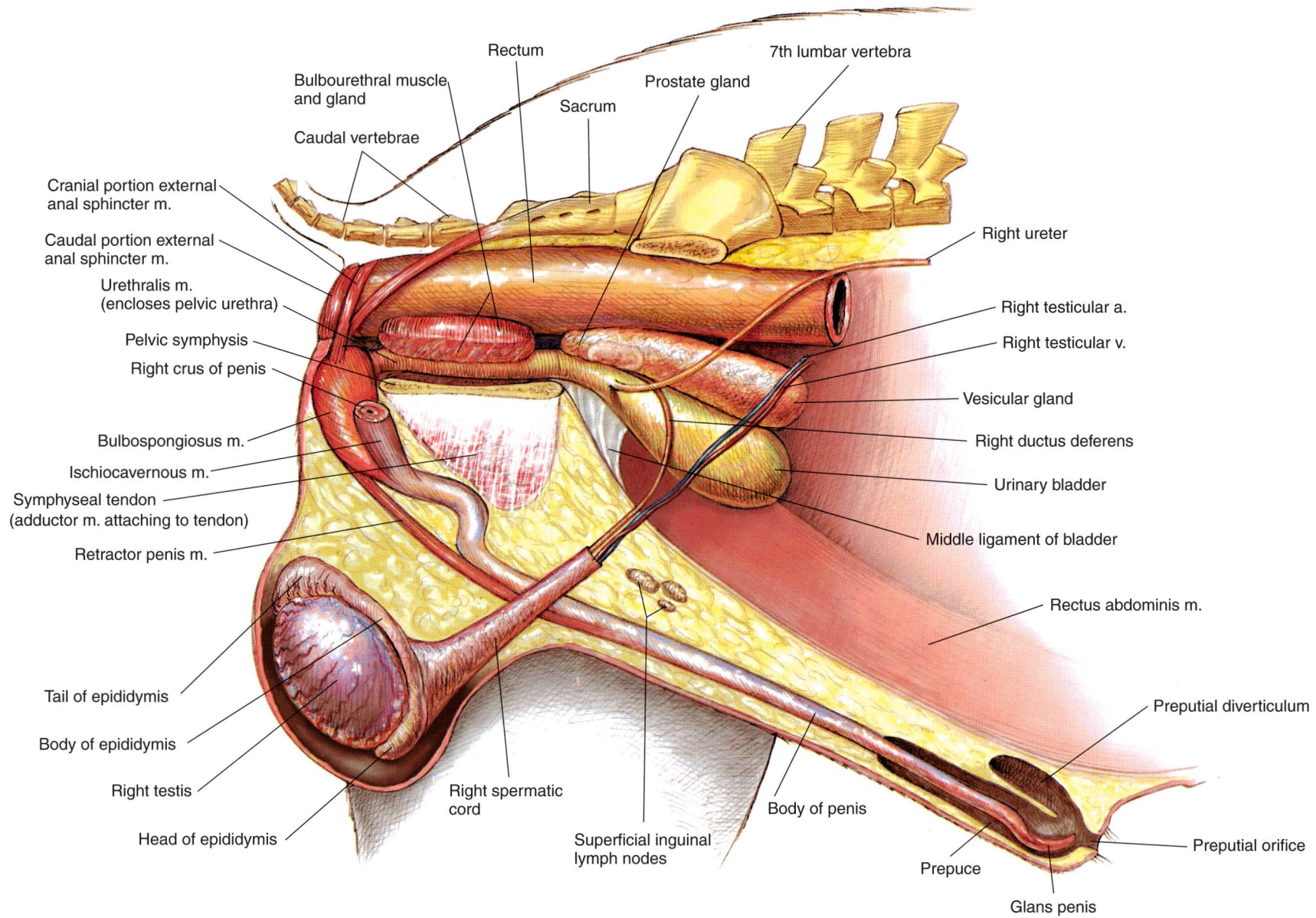


PLATE 6.15 Relations of the reproductive organs of the boar. m = muscle, v = vein, a = artery



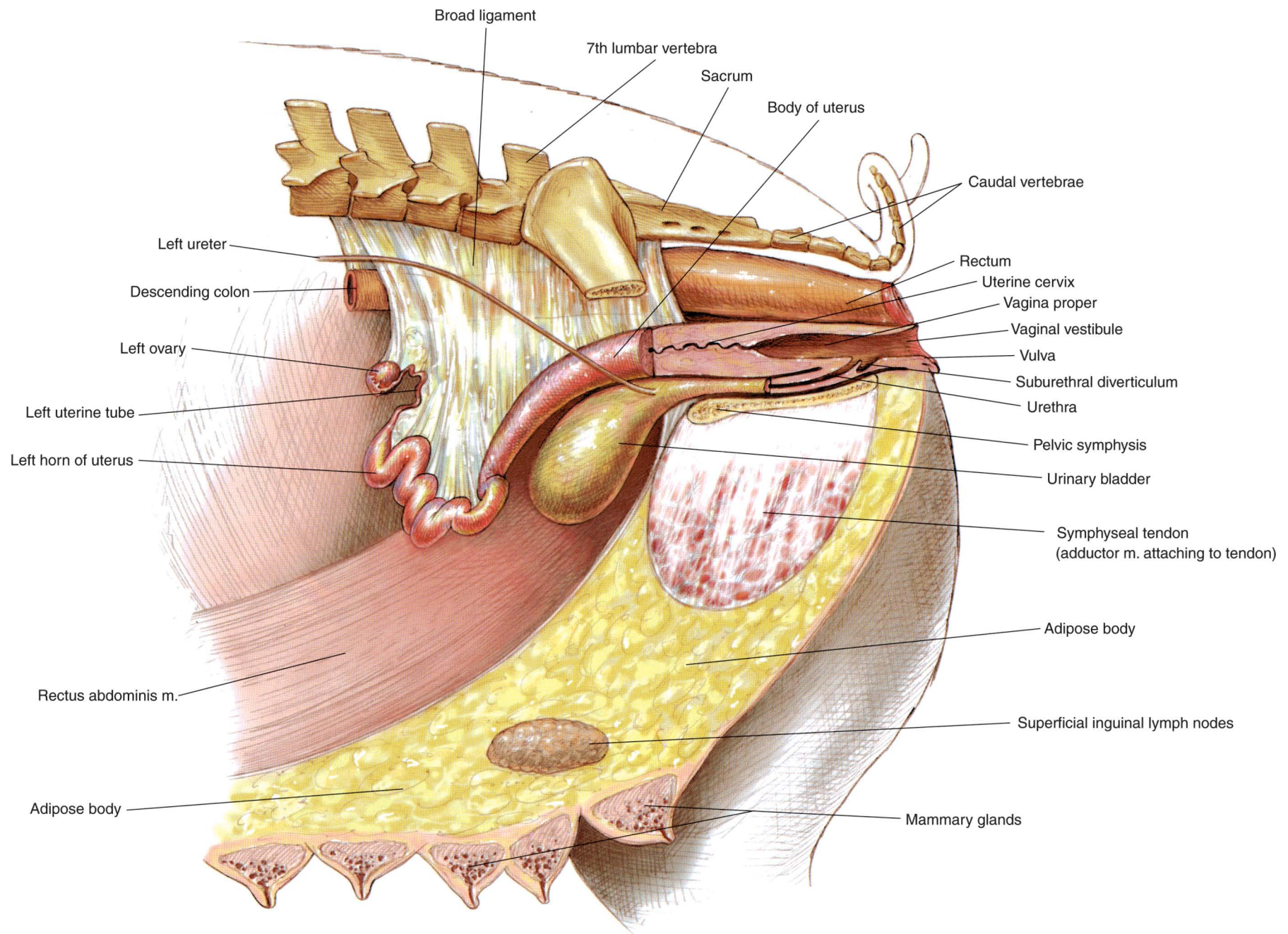



PLATE 6.16 Relations of the reproductive organs of the sow.





# SECTION 7 THE CHICKEN

(*Gallus gallus domesticus*)



## PLATES

- 7.1 Right lateral view of a rooster (cock).
- 7.2 Left lateral view of a hen.
- 7.3 Feather coat of the rooster.
- 7.4 Skeleton of the chicken.
- 7.5 Superficial muscles of the rooster.
- 7.6 Superficial muscles of the hen.
- 7.7 Relations of *in situ* viscera to the skeleton and cervical muscles of the rooster.
- 7.8 Relations of *in situ* viscera and blood vessels to the skeleton and cervical muscles of the hen.
- 7.9 Isolated gastrointestinal tract of the chicken.
- 7.10 Air sacs and lungs of the chicken.
- 7.11 *In situ* viscera, major blood vessels, and axial skeleton of the rooster.
- 7.12 *In situ* viscera, major blood vessels, and axial skeleton of the hen.
- 7.13 Reproductive and urinary organs of the rooster.
- 7.14 Reproductive organs of the hen.



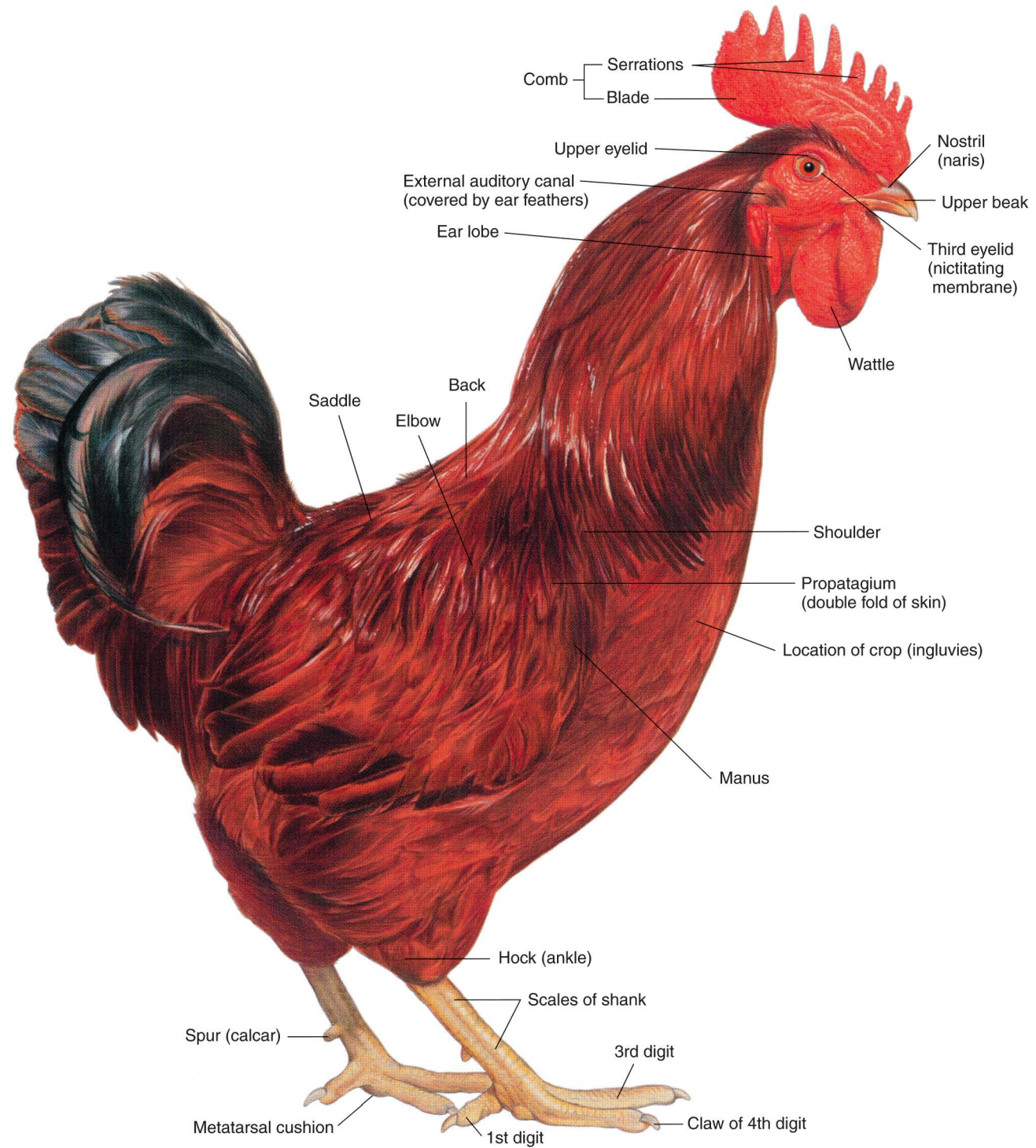
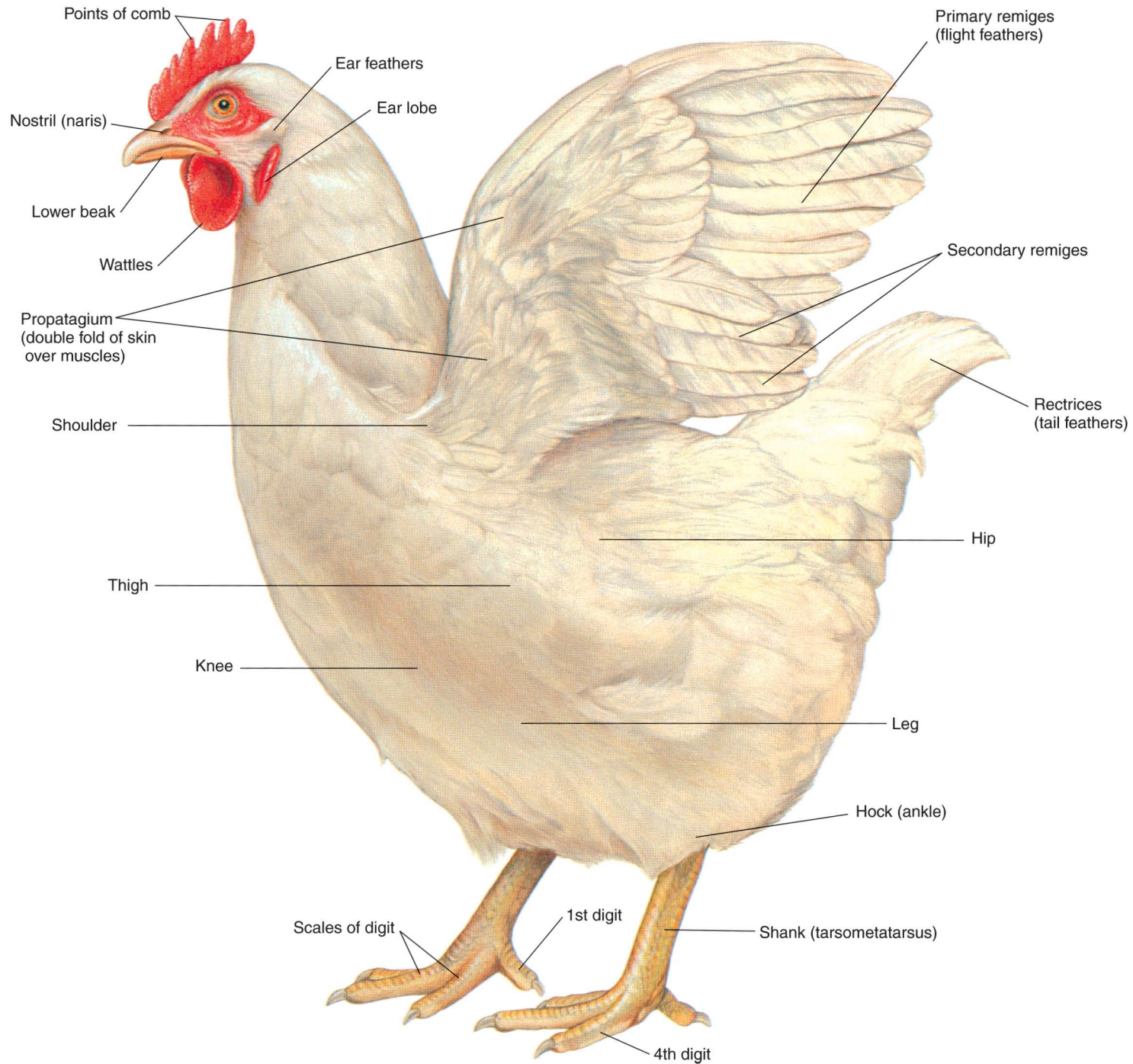


PLATE 7.1 Right lateral view of a rooster (cock).





**PLATE 7.2** Left lateral view of a hen. Patagiectomy (wing clipping), excision of part of the propatagium (wing membrane), is performed on one wing to prevent flight.

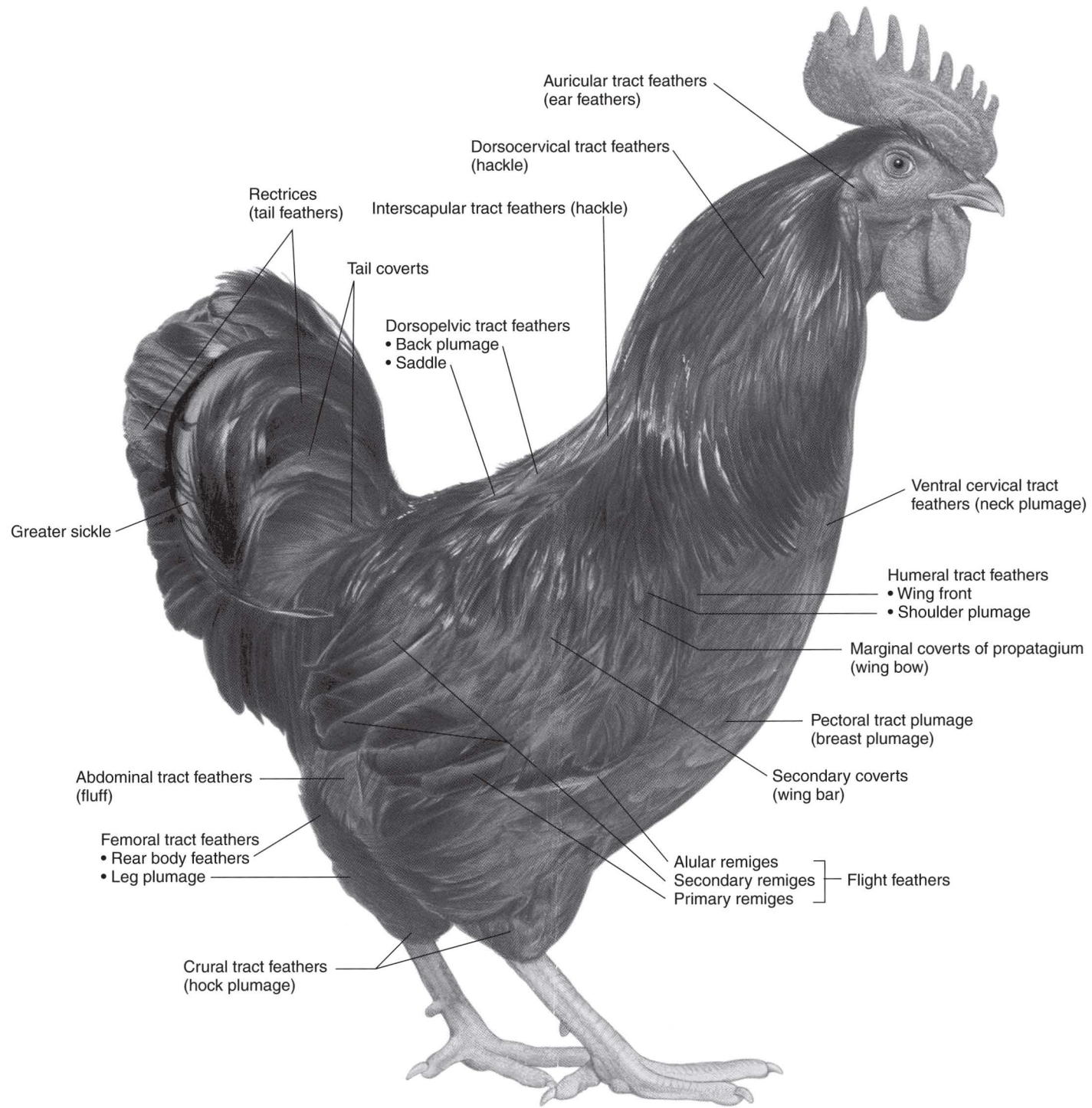
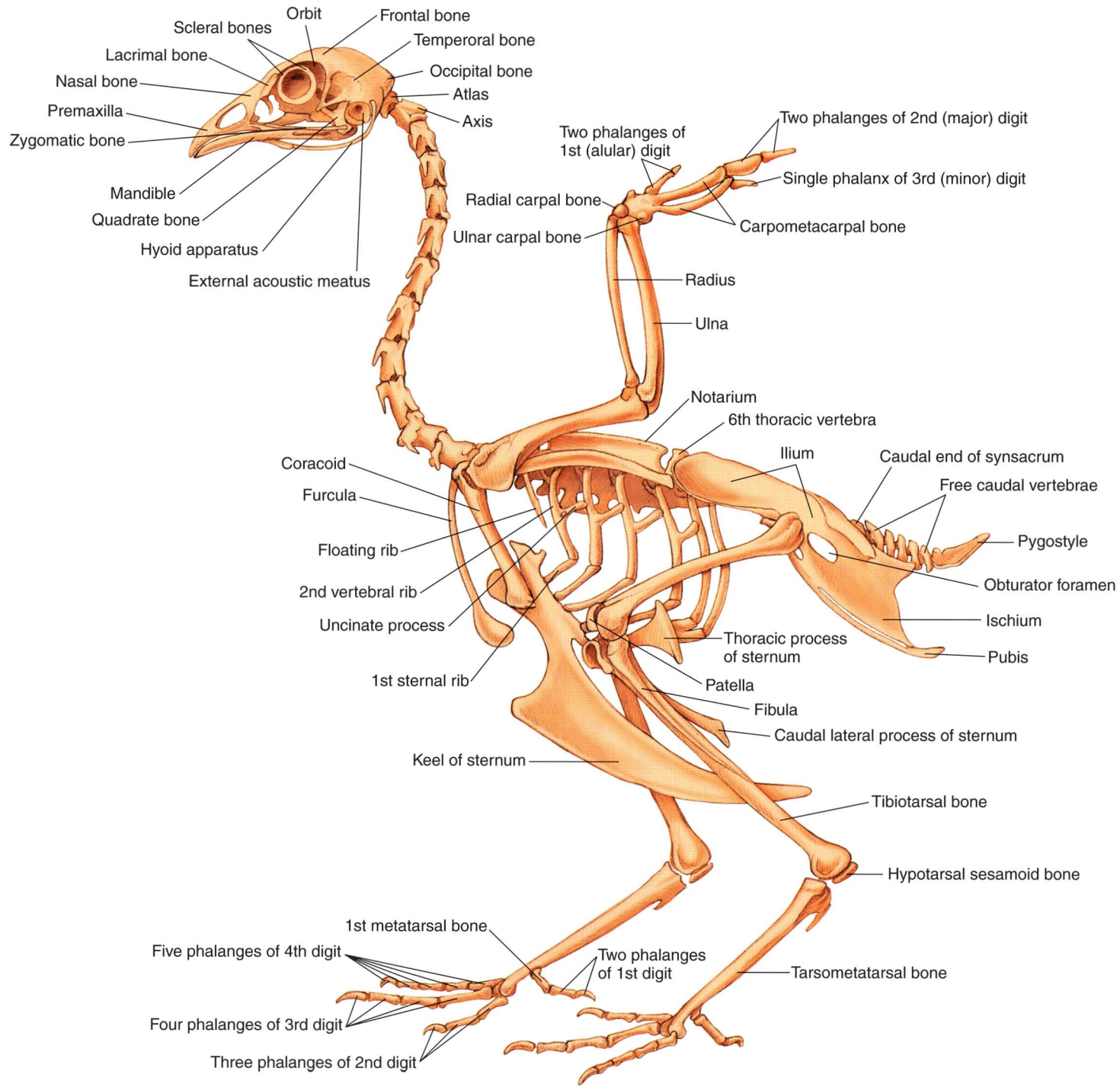


PLATE 7.3 Feather coat of the rooster.





**PLATE 7.4** Skeleton of the chicken. Left lateral view.

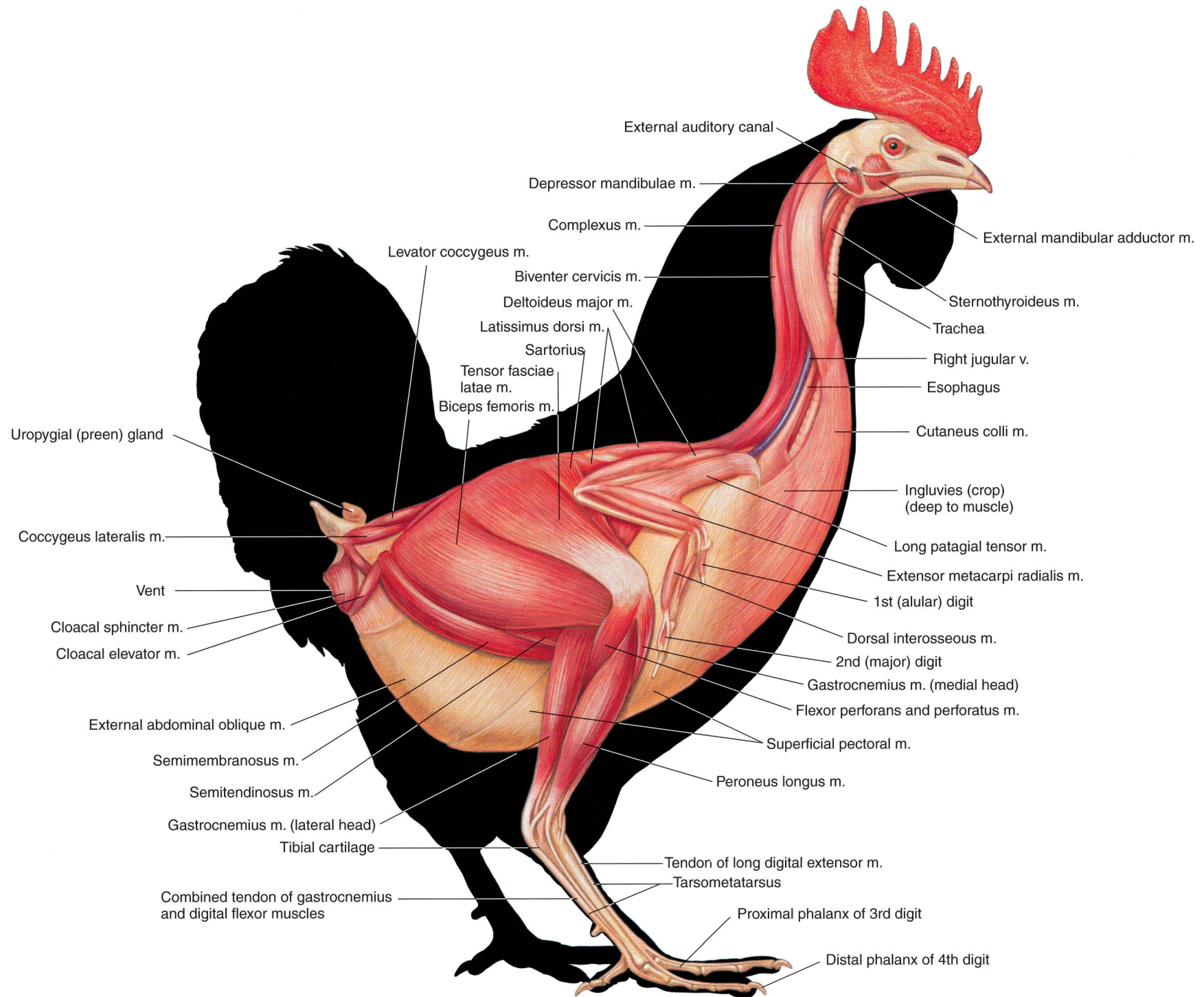


PLATE 7.5 Superficial muscles of the rooster. Right lateral view. m = muscle, v = vein




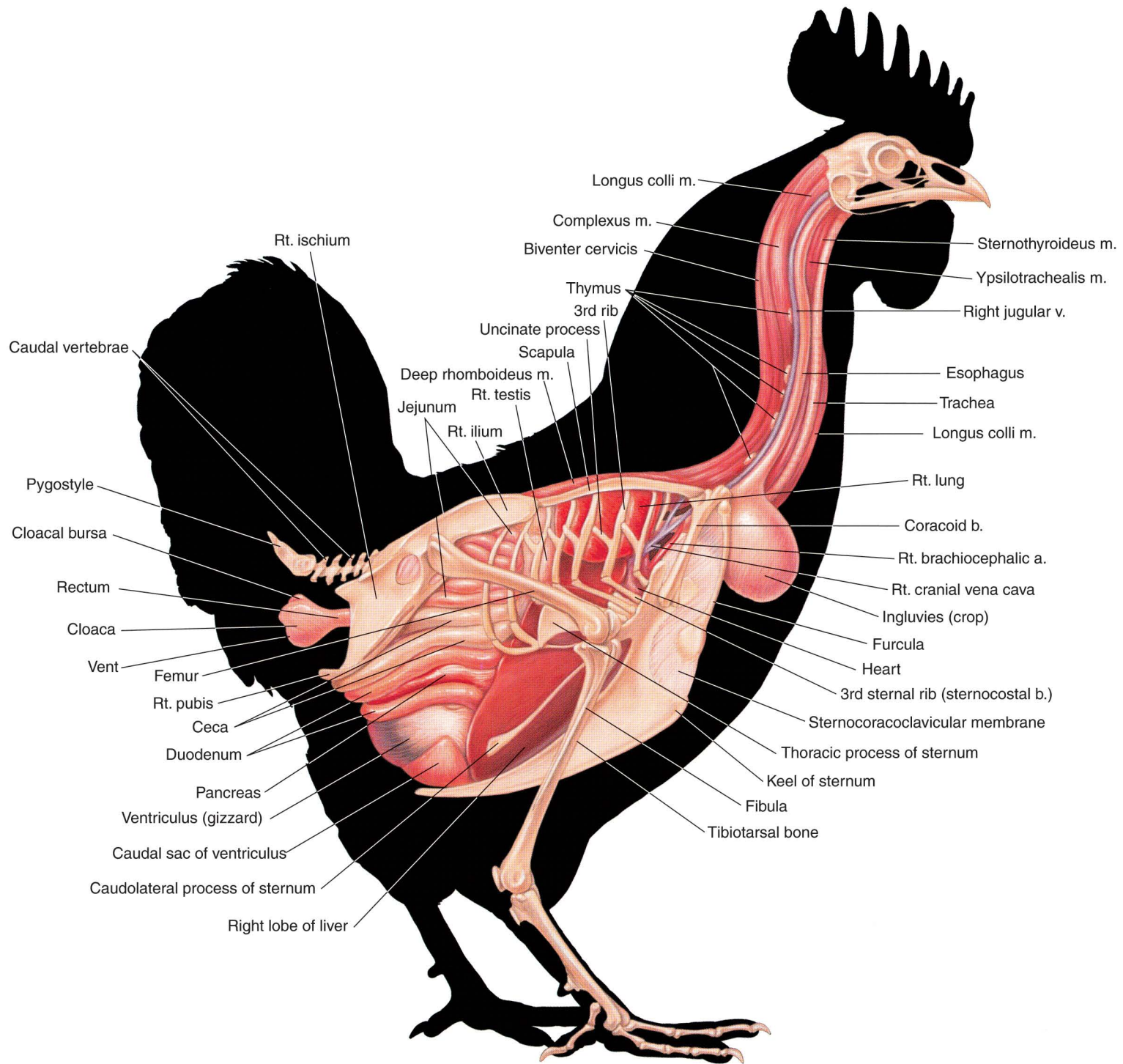
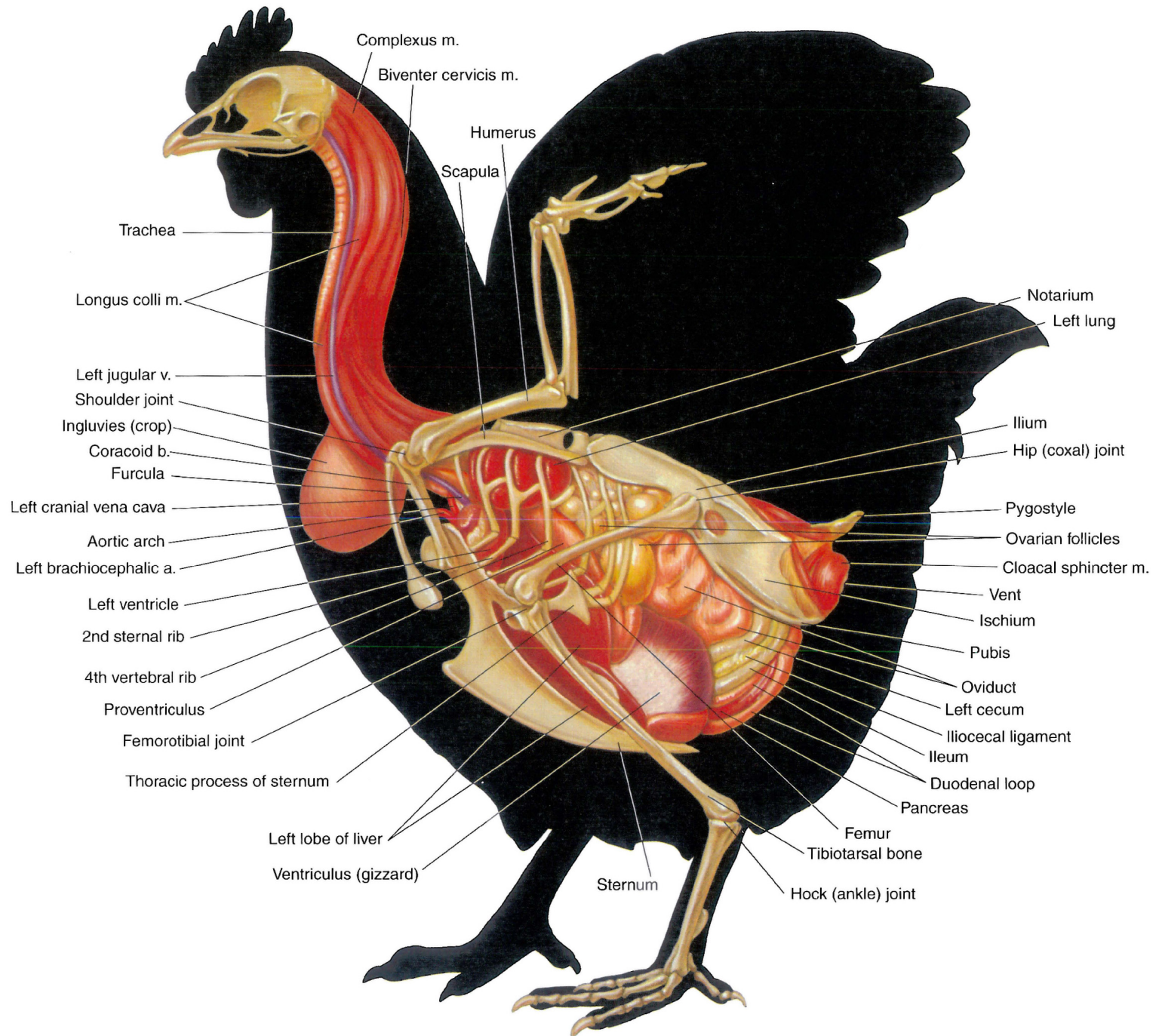


PLATE 7.6 Superficial muscles of the hen. Left lateral view. m = muscle



**PLATE 7.7** Relations of *in situ* viscera to the skeleton and cervical muscles of the rooster.  
 Right lateral view. m = muscle, b = bone, a = artery, v = vein





**PLATE 7.8** Relations of *in situ* viscera and blood vessels to the skeleton and cervical muscles of the hen. Left lateral view. m = muscle, v = vein, b = bone, a = artery

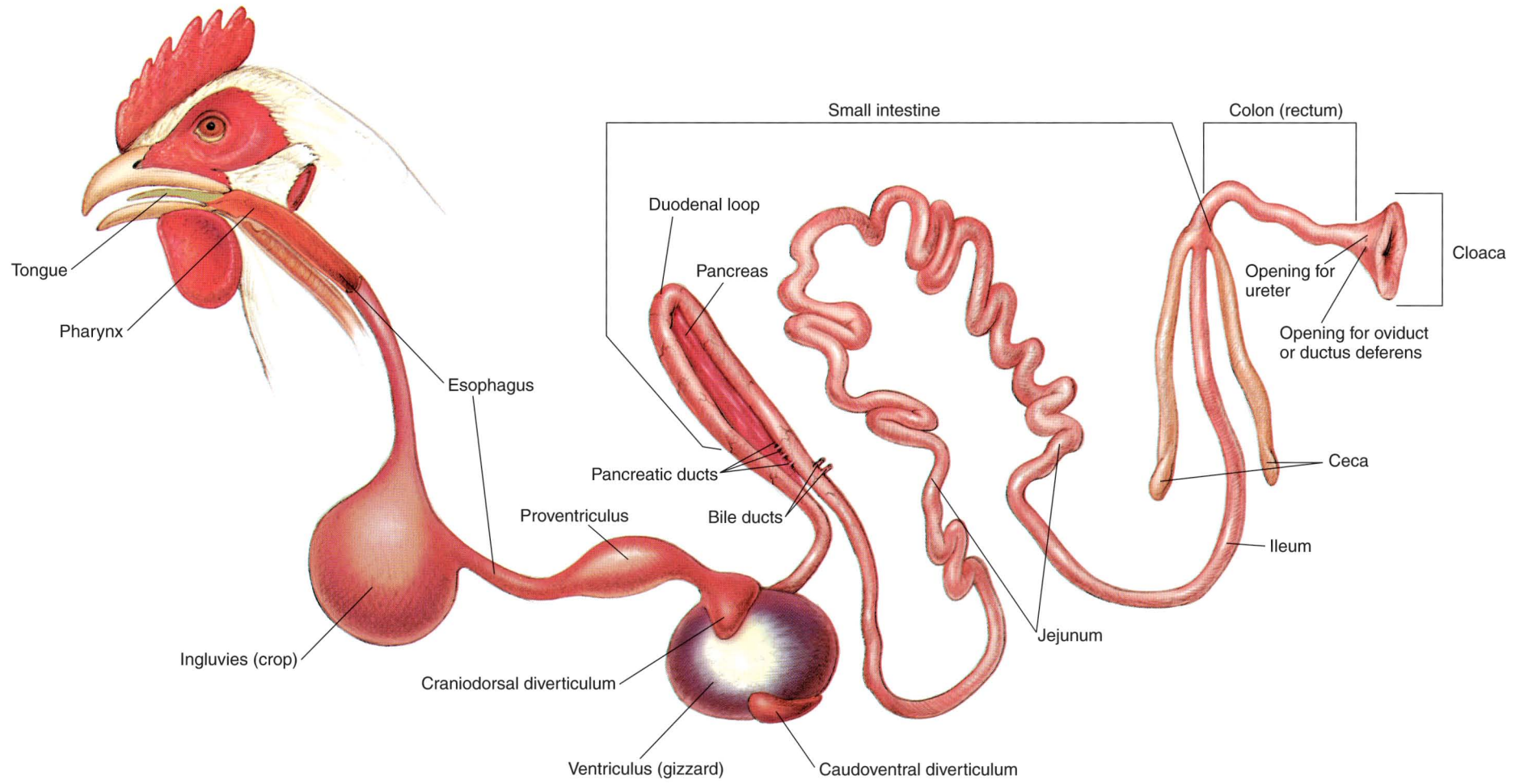

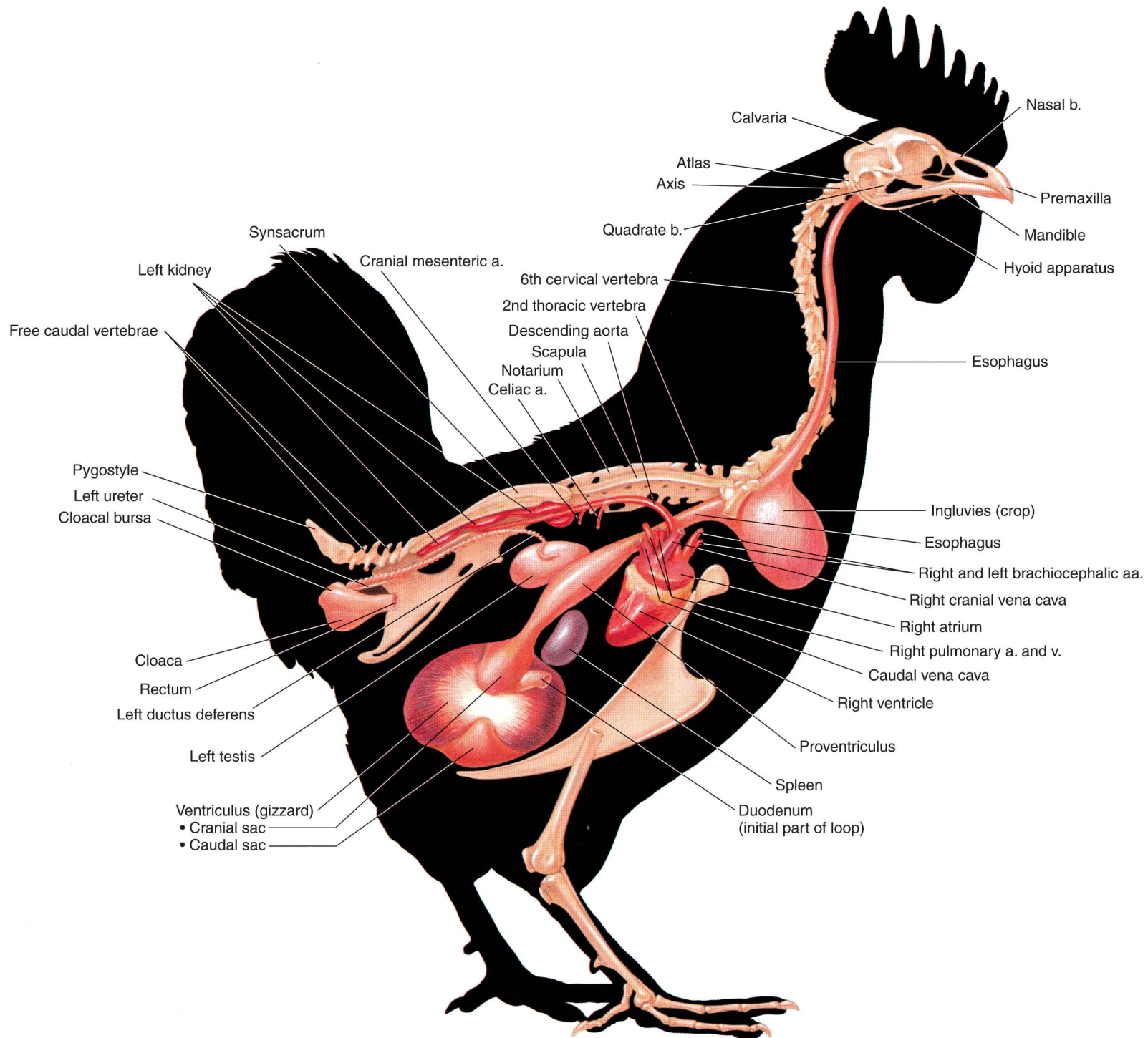


PLATE 7.9 Isolated gastrointestinal tract of the chicken.



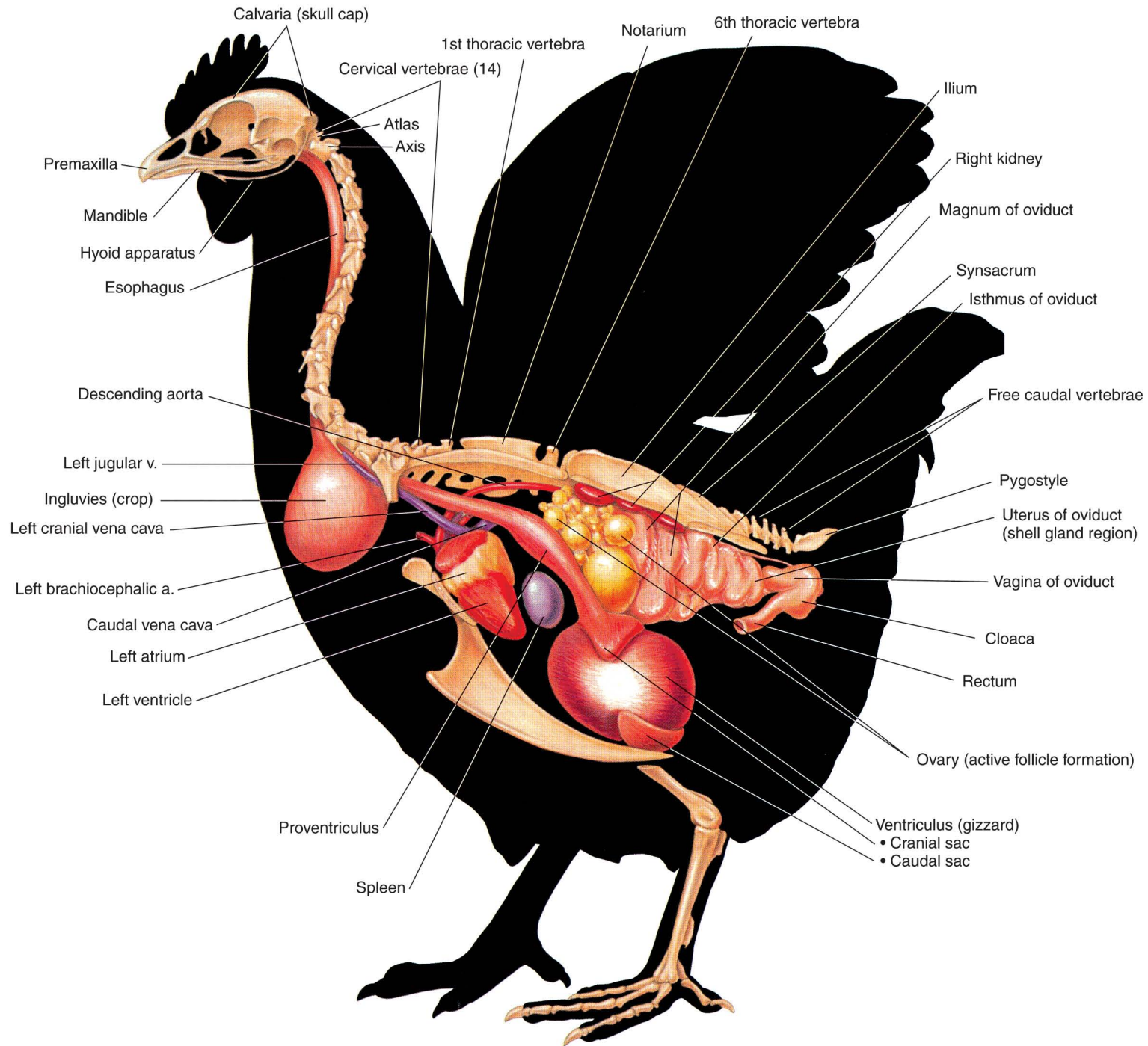


**PLATE 7.10** Air sacs and lungs of the chicken. Left lateral view. There is a total of eleven air sacs named according to location: abdominal, caudal thoracic, cranial thoracic, axillary, clavicular, and cervical. All are paired except the single clavicular sac. With the exception of the thoracic sacs, all provide communication between a bronchus and the interior of some of the pneumatic (air-containing) bones.

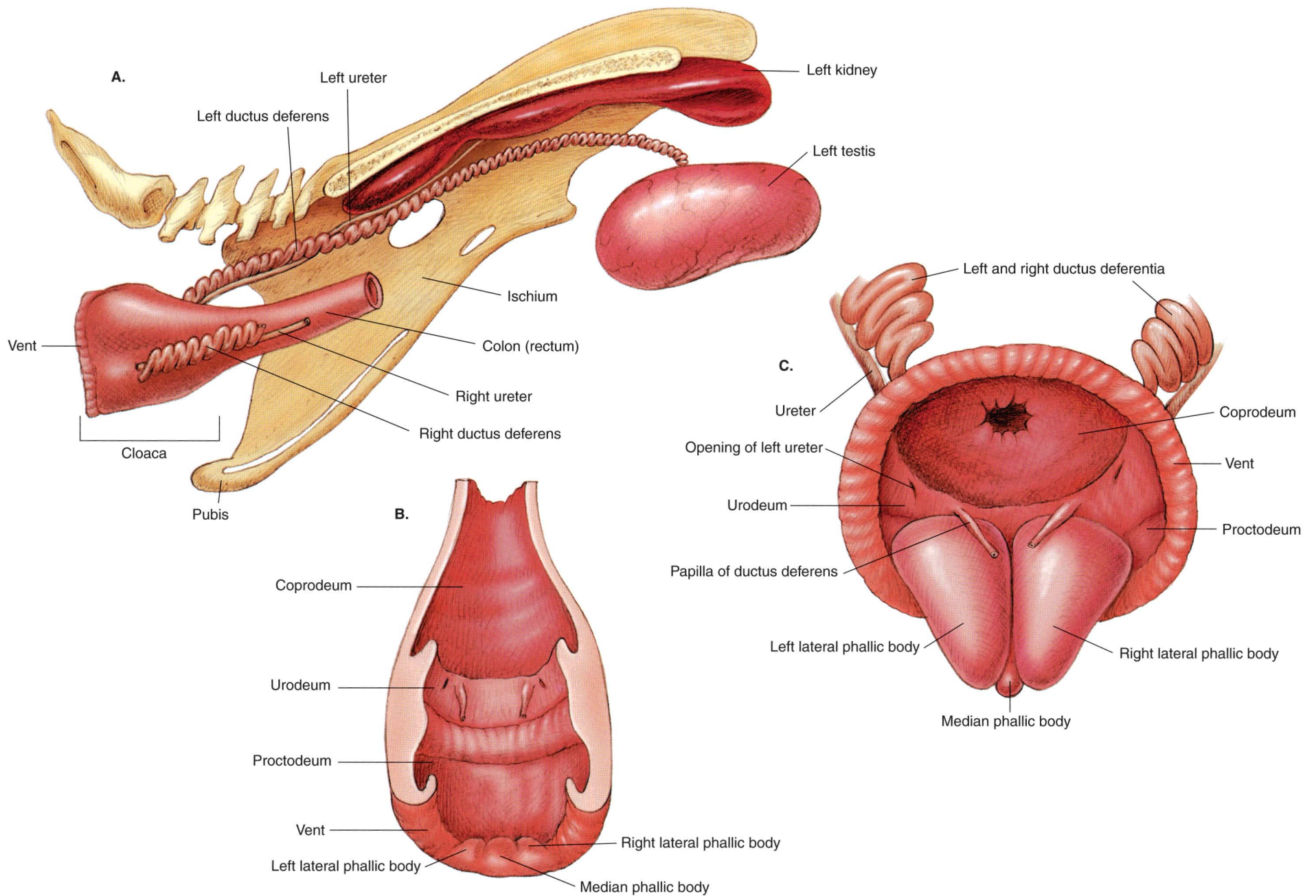


**PLATE 7.11** *In situ* viscera, major blood vessels, and axial skeleton of the rooster. Intestines, liver, and lungs are removed. Right lateral view. b = bone, a = artery, v = vein



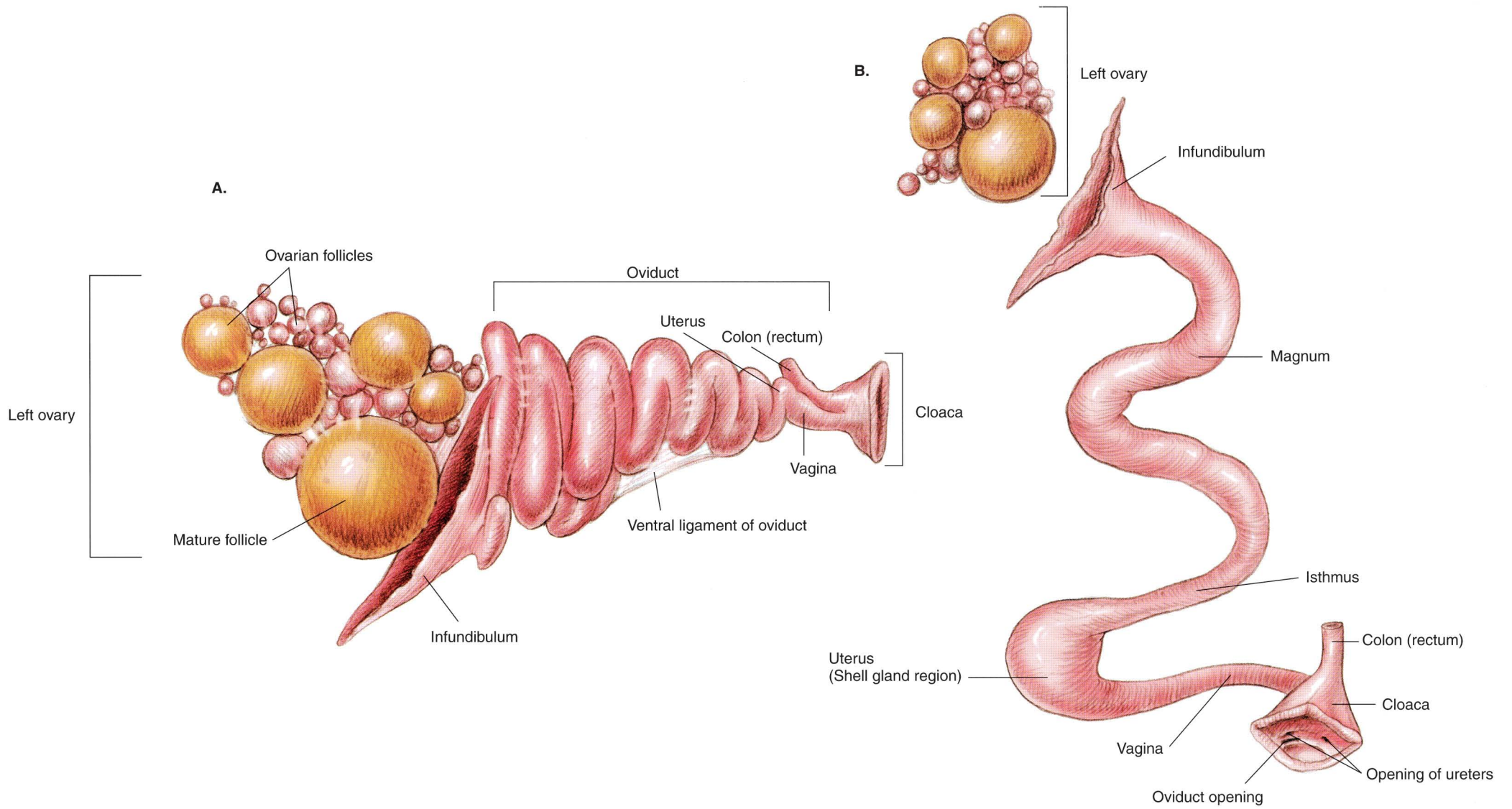


**PLATE 7.12** *In situ* viscera, major blood vessels, and axial skeleton of the hen. Intestines, liver, and lungs are removed. Left lateral view. v = vein, a = artery



**PLATE 7.13** A. Reproductive and urinary organs of the rooster. Right lateral view. B. Cloaca of the rooster. Dorsal view. C. Erect copulatory apparatus. Caudodorsal view.





**PLATE 7.14** A. Isolated reproductive organs of the hen. Left lateral view.  
 B. Diagrammatic representation of the reproductive organs of the hen.

# BIBLIOGRAPHY

- Ashdown PR, Done SH. Color Atlas of Veterinary Anatomy—The Ruminants. London: Bailliere Tindall, 1984.
- Ashdown PR, Done SH. Color Atlas of Veterinary Anatomy—The Horse. London: Bailliere Tindall, 1987.
- Budras K-D, Sack WO, Rock S. Anatomy of the Horse—An Illustrated Text. London: Mosby-Wolfe, 1994.
- Chamberlain F. Atlas of Avian Anatomy. East Lansing, Michigan: State College Press, 1943.
- Clayton HM, Flood PF. Color Atlas of Large Animal Applied Anatomy. London: Mosby-Wolfe, 1996.
- de Lahunta A, Habel RE. Applied Veterinary Anatomy. Philadelphia: WB Saunders, 1986.
- Dyce KM, Sack WO, Wensing GJG. Textbook of Veterinary Anatomy. Philadelphia: WB Saunders, 1987.
- Ellenberger W. Leisering's Atlas of Anatomy, Vol 1. Chicago: Alexander Eger, 1908.
- Ellenberger W, Dittrich H, Baum HM. An Atlas of Animal Anatomy. London: Dover, 1949.
- Ellenberger W, Baum HM. Handbuch der Vergleichenden Anatomie der Haustiere. 18th ed. Berlin: Springer, 1977.
- Fowler ME. Medicine and Surgery of South American Camelids: Llama, Alpaca, Vicuna, Guanaco. Ames, IA: Iowa State University Press, 1995.
- Garrett PD. Guide to Ruminant Anatomy Based on the Dissection of the Goat. Ames, IA: Iowa State University Press, 1988.
- Gertty R. Sisson and Grossman's The Anatomy of the Domestic Animals, 5th ed, Vols I and II. Philadelphia: WB Saunders, 1975.
- Goshal NG, Koch T, Popesko P. The Venous Drainage of the Domestic Animals. Philadelphia: WB Saunders, 1981.
- Harvey EB, Kaiser HE, Rosenberg LE. An Atlas of the Domestic Turkey. United States Atomic Energy Commission, 1948.
- Kainer RA. Functional anatomy of equine locomotor organs. In: Stashak T, ed. Adams' Lameness in Horses. 5th ed. Philadelphia: Lippincott Williams & Wilkins, 1999.
- Kainer RA, McCracken TO. Horse Anatomy—A Coloring Atlas. 2nd ed. Loveland, CO: Alpine Publications, 1998.
- McLeod WM, Trotter DM, Lumb JW. Avian Anatomy. Minneapolis: Burgess Publishing Co, 1964.
- The Meat Buyers Guide. National Association of Meat Purveyors, McLean, VA, 1992.
- Moreng RE, Avens JS. Poultry Science and Production. Prospect Heights, IL: Waveland Press, 1981.
- Nickel R, Schummer A, Seiferle E, et al. The Locomotor System of the Domestic Animals, Vol 1. Berlin-Hamburg: Paul Parey, 1986.
- Nickel R, Schummer A, Seiferle E. Nervensystem. Sinnesorgane und Endokrine Drüsen, Vol 4. Berlin-Hamburg: Paul Parey, 1992.
- Nickel R, Schummer A, Seiferle E. Anatomy of the Domestic Birds, Vol 5. Berlin-Hamburg: Paul Parey, 1977.
- Pfizer Animal Health Group. Anatomical Atlas. New York: Pfizer Corporation, 1976.
- Popesko P. Atlas of Topographic Anatomy of the Domestic Animals. Philadelphia: WB Saunders, 1979.
- Sack WO, Habel RE. Rooney's Guide to the Dissection of the Horse. Ithaca, NY: Veterinary Textbooks, 1977.
- Sack WO, Horowitz A. Essentials of Pig Anatomy & Atlas of Musculoskeletal Anatomy of the Pig. Ithaca, NY: Veterinary Textbooks, 1982.
- Schummer A, Nickel R, Sack WO. The Viscera of the Domestic Animals, Vol 2. Berlin-Hamburg: Paul Parey, 1979.
- Schummer A, Wilkins H, Vollmerhaus B, Habermehl K-H. The Circulatory System, the Skin, and the Cutaneous Organs of the Domestic Animals, Vol 3. Berlin-Hamburg: Paul Parey, 1981.
- Senger PL. Pathways to Pregnancy and Parturition. Pullman, WA: Senger, 1997.
- Shively MJ. Veterinary Anatomy—Basic, Comparative and Clinical. College Station, TX: Texas A & M University, 1984.
- Smallwood JE. A Guided Tour of Veterinary Anatomy. Philadelphia: WB Saunders, 1992.



# INDEX

References to the various animals described in this atlas are indicated by the following letters preceding page numbers: **H**, horse; **O**, ox; **S**, sheep; **G**, goat; **L**, llama and alpaca; **Sw**, swine; **C**, chicken.

## A

- Abdomen, **L** 90; **Sw** 111  
Abdominal tunic, **O** 37  
Abomasum, **O** 38, 42, 43, 45; **S** 60, 61, 64, 65; **G** 80, 81, 84  
Adipose body, **Sw** 125  
Air sacs, **C** 137  
Ankle, **H** 2 (fetlock); **C** 128, 129 (hock)  
Antebrachium, **H** 2; **O** 33; **G** 72; **L** 90  
Anus, **H** 13, 20, 22, 23; **O** 41, 45, 46, 47; **S** 67; **G** 85, 86, 87; **L** 106, 107; **Sw** 117  
Aorta. *See* Artery or Arteries  
Arm, **H** 2; **O** 32, 33; **S** 54; **G** 72; **L** 90  
Artery or Arteries  
  aorta, **H** 24, 25; **O** 44, 45, 49; **S** 64, 64; **G** 84, 85, 87; **L** 104, 105; **Sw** 123; **C** 135, 138, 139  
  artery of the lateral sinus, **G** 87  
  axillary, **H** 25, 49  
  bicarotid trunk, **S** 65; **G** 85  
  brachial, **H** 25; **O** 49  
  brachiocephalic trunk, **H** 21, 25; **O** 45, 49; **S** 65; **L** 104, 105; **Sw** 123  
  bronchoesophageal, **O** 49  
  caudal auricular, **H** 25; **O** 49; **G** 82  
  caudal epigastric, **H** 25; **O** 49; **G** 85, 87  
  caudal femoral, **H** 25; **O** 49  
  caudal gluteal, **H** 25; **O** 49; **G** 87  
  caudal interosseous, **O** 49  
  caudal mammary, **O** 49; **G** 87  
  caudal meningeal, **G** 82  
  caudal mesenteric, **H** 25; **O** 49  
  caudal superficial epigastric, **G** 87  
  caudal tibial, **H** 25; **O** 49  
  celiac, **H** 25; **O** 49; **C** 138  
  collateral ulnar, **H** 25; **O** 49  
  common carotid, **H** 25; **O** 44, 45, 49; **S** 62, 64, 65; **G** 82, 84, 85; **L** 101, 104, 105; **Sw** 122, 123  
  common interosseous, **H** 20, 21, 25; **O** 44, 45, 59; **S** 62, 64, 65; **G** 82, 84, 85  
  condylar, **G** 82  
  cornual, **G** 80, 82  
  costocervical trunk, **H** 25  
  cranial epigastric, **H** 25; **O** 49  
  cranial gluteal, **H** 25; **O** 49  
  cranial interosseous, **O** 49  
  cranial mammary, **O** 49; **G** 87  
  cranial mesenteric, **H** 25; **O** 49; **C** 138  
  cranial tibial, **H** 25; **O** 49  
  deep cervical, **H** 25; **O** 49  
  deep circumflex iliac, **H** 25; **O** 49  
  deep femoral, **H** 25; **O** 49; **G** 85, 87  
  descending genicular, **H** 25  
  digital, **H** 25; **G** 78; **L** 96  
  distal perforating branch, **H** 25  
  dorsal, **H** 25; **O** 49  
  dorsal common digital, **O** 49  
  dorsal metacarpal III, **O** 49  
  dorsal metatarsal III, **O** 49  
  dorsal nasal, **G** 82  
  dorsal pedal, **H** 25; **O** 49  
  dorsal proper digital, **O** 49  
  ethmoid, **G** 82

Artery or Arteries—*Continued*

external carotid, **H** 21, 25; **O** 49; **G** 85  
external iliac, **H** 25; **O** 49; **G** 85, 87  
external maxillary, **G** 82  
external pudendal, **H** 25; **O** 49; **G** 85, 87  
external thoracic, **H** 25; **O** 49  
facial, **H** 21, 25; **O** 37, 49  
femoral, **H** 25; **O** 49; **G** 85, 87  
iliolumbar, **H** 25; **O** 49  
inferior labial, **G** 82  
infraorbital, **H** 21; **G** 82  
intercostal, **H** 25; **O** 45, 49; **G** 85; **Sw** 123  
internal carotid, **H** 21, 21, 25; **Sw** 123  
internal iliac, **H** 25; **O** 49; **G** 85, 87  
internal pudendal, **H** 25; **G** 87  
internal thoracic, **H** 25; **O** 49  
lacrimal, **O** 49  
lateral circumflex femoral, **H** 25  
lateral dorsal metacarpal, **H** 25  
lateral palmar, **H** 25  
lateral palmar metacarpal, **H** 25  
lateral plantar, **H** 25  
lateral plantar metatarsal, **H** 25  
left brachiocephalic, **C** 135, 138, 139  
lingual, **H** 25; **O** 49; **G** 82, 85  
linguofacial trunk, **H** 25; **O** 49  
malar, **G** 82  
mammary, **H** 25  
masseteric br. of transverse facial, **G** 82  
maxillary, **O** 49  
medial circumflex femoral, **H** 25  
medial dorsal metacarpal, **H** 25  
medial palmar, **H** 25  
medial palmar metacarpal, **H** 25  
medial plantar, **H** 25; **O** 49  
medial plantar metatarsal, **H** 25  
medial tarsal, **O** 49  
median, **H** 25; **O** 49; **G** 78; **L** 98  
median sacral, **O** 49  
mental, **G** 82  
middle mammary, **G** 87

obturator, **H** 25  
occipital, **H** 25; **O** 49; **G** 82, 85  
ovarian, **H** 25; **G** 85  
palmar common digital, **O** 49; **G** 78; **L** 98  
palmar proper digital, **O** 49; **G** 78; **L** 98  
papillary, **G** 87  
plantar common digital, **O** 49  
plantar metatarsal, **O** 49  
plantar proper digital, **O** 49  
popliteal, **H** 25; **O** 49  
pudendoepigastric trunk, **H** 25; **O** 49; **G** 85, 87  
pulmonary trunk, **H** 25; **O** 45, 49; **S** 65; **Sw** 123; **C** 138  
radial, **H** 25; **O** 49  
renal, **H** 25; **O** 49  
rete mirabile, **O** 49  
right brachiocephalic, **C** 134, 138  
saphenous, **H** 25; **O** 49  
subclavian, **H** 25; **O** 49; **S** 65; **G** 85; **Sw** 123  
subscapular, **H** 25; **O** 49  
superficial cervical, **H** 25; **O** 49  
superficial temporal, **H** 25; **O** 49; **G** 80, 82  
superior labial, **G** 82  
terminal arch, **H** 25  
testicular, **H** 22; **O** 46; **S** 66; **G** 86; **L** 106; **Sw** 124  
thoracodorsal, **O** 49  
transverse cubital, **H** 25  
transverse facial, **H** 21, 25; **G** 80, 82  
umbilical, **H** 24, 25; **O** 49; **G** 87  
uterine, **H** 25; **O** 49; **G** 87  
vaginal, **O** 49; **G** 87  
vertebral, **H** 13, 20, 21, 25; **O** 44, 45, 49; **S** 64, 65; **G** 84, 85; **L** 104, 105; **Sw** 122, 123

Autonomic nervous system, **H** 28

ganglia  
parasympathetic cranial outflow  
parasympathetic nerves  
parasympathetic sacral outflow  
sympathetic nerves  
sympathetic thoracic outflow  
sympathetic trunk



## B

- Back, **H** 2; **O** 32; **S** 54; **G** 72; **L** 90; **Sw** 110, 111; **C** 128, 130
- Barrel, **H** 3; **O** 33; **L** 90
- Beak, **C** 128, 129
- Beard, **G** 72
- Body regions, **H** 4; **O** 34; **G** 74; **L** 91
- dorsal vertebral regions, **O** 38; **S** 55; **G** 73; **L** 91
  - perineal region, **O** 33
- Bone(s)
- atlas, **H** 5, 12, 14, 20; **O** 35, 39, 44, 45; **S** 57, 61, 64; **G** 75, 81, 83; **L** 93, 97, 99; **Sw** 113, 118, 122; **C** 131, 138, 139
  - axis, **H** 5, 14, 20; **O** 35, 45; **S** 57; **G** 75, 83; **L** 93, 99; **Sw** 113, 118, 122; **C** 131, 138, 139
  - basihyoid, **H** 14; **O** 40; **G** 83; **L** 99; **Sw** 118
  - calcaneus, **H** 5; **O** 35; **S** 57; **G** 75; **L** 93; **Sw** 113
    - calcaneal tuber, **H** 5; **O** 35; **S** 57; **G** 73, 75; **L** 91; **Sw** 110, 113
  - calvaria (skull cap), **C** 131, 138, 139
  - cannon, **H** 5. *See* Third metacarpal/metatarsal
  - carpal, **H** 5; **O** 35; **S** 57; **G** 75; **L** 93; **Sw** 113; **C** 131
  - carpometacarpal, **C** 131
  - coffin, **H** 5
  - coracoid, **C** 131, 134
  - ethmoid, **H** 14; **G** 83; **L** 99; **Sw** 118
  - femur, **H** 5; **O** 35, 39; **S** 57, 64; **G** 75; **L** 93, 104; **Sw** 113, 122; **C** 131, 134, 135
    - greater trochanter, **H** 5; **O** 35, 38, 39; **S** 57, 60; **G** 75, 80; **L** 93; **Sw** 113
  - fibula, **H** 5; **Sw** 113; **C** 131, 134
  - frontal, **H** 5, 14; **O** 35, 40; **S** 57, 60; **G** 75, 80, 82, 83, 84; **L** 93, 99, 102; **Sw** 113, 118, 119; **C** 131
    - cornual process, **S** 57, 60; **G** 80
  - furcula, **C** 131, 134, 135
  - humerus, **H** 5, 8; **O** 35, 39; **S** 57, 64; **G** 75; **L** 93, 104; **Sw** 113; **C** 131, 135
    - deltoid tuberosity, **H** 5
    - greater tubercle, **H** 5; **O** 32, 35; **S** 57; **G** 73, 75; **L** 93; **Sw** 111, 113
    - lateral epicondyle, **H** 5; **G** 75; **L** 93
  - hyoid apparatus, **H** 13; **C** 131
  - ilium, **H** 5; **O** 35; **S** 57, 64; **G** 75; **L** 93, 104; **Sw** 113, 117, 122; **C** 131, 134, 135, 136, 139
    - body, **H** 5; **O** 35; **S** 57; **G** 75; **L** 93
    - coxal tuber, **H** 5, 7, 13; **O** 32, 35, 37, 39; **S** 57, 58; **G** 73, 75, 76; **L** 93, 95; **Sw** 111, 113, 115, 117
    - sacral tuber, **H** 5
    - wing, **H** 5; **O** 35; **S** 57; **G** 75
  - incisive, **H** 5, 14; **O** 35; **S** 57, 60; **G** 75, 80, 82, 84; **L** 93, 102; **Sw** 113, 119
  - interparietal, **L** 102
  - ischium, **H** 5; **O** 35, 44; **S** 57; **G** 75; **L** 93; **Sw** 113, 117; **C** 131, 134, 135, 140
    - ischiatric tuber, **H** 5, 13; **O** 32, 35, 39; **S** 57, 61, 64; **G** 75, 76; **L** 93, 95; **Sw** 113, 117, 122
  - lacrimal, **H** 5; **O** 35; **S** 57; **G** 75; **L** 93, 102; **Sw** 113, 119; **C** 131
  - mandible, **H** 5, 15; **O** 35, 40; **S** 57, 60; **G** 75, 80, 82, 83, 84; **L** 93, 99, 102; **Sw** 113, 118, 119; **C** 131, 138, 139
    - coronoid process, **O** 44; **G** 84; **L** 93
    - mental foramen (foramina), **H** 5, 15; **O** 35; **S** 57; **G** 75; **L** 102; **Sw** 113, 119
  - maxilla, **H** 5, 12, 15; **O** 35; **S** 57, 60; **G** 75, 82, 84; **L** 93, 102; **Sw** 113, 119
    - facial crest, **H** 3, 5
    - facial tuber, **O** 35
    - infraorbital foramen, **H** 5; **O** 35; **S** 57; **G** 75; **L** 93, 102; **Sw** 113, 119
  - metacarpal
    - fifth, **O** 35; **S** 57; **G** 75; **Sw** 113
    - fourth, **H** 5; **O** 35; **S** 57; **G** 75; **L** 93; **Sw** 113
    - second, **H** 5; **O** 35; **Sw** 113;
    - third, **H** 5; **O** 35; **S** 57; **G** 75; **L** 93; **Sw** 113
  - metacarpal tuberosity, **H** 5, 10
  - metatarsal
    - fifth, **Sw** 113
    - fourth, **H** 5; **O** 35; **S** 57; **G** 75; **L** 93; **Sw** 113
    - second, **H** 5; **O** 35; **Sw** 113
    - third, **H** 5; **O** 35; **S** 57; **G** 75; **L** 93; **Sw** 113
  - nasal, **H** 5, 12, 14; **O** 35; **S** 57; **G** 75, 80, 82, 83; **L** 99, 102; **Sw** 113, 118, 119; **C** 131, 138
  - navicular, **H** 8

Bone(s)—Continued

notarium, **C** 131, 138, 139  
occipital, **H** 5, 14; **O** 35, 40; **S** 57, 60; **G** 75, 82, 83; **L** 93, 99, 102; **Sw** 113, 118, 119; **C** 131  
nuchal crest, **O** 35  
palatine, **H** 14; **O** 35  
paracondylar process, **L** 102; **Sw** 122  
parietal, **H** 5, 14; **O** 35; **S** 27; **G** 75; **G** 75, 83; **L** 93, 99, 102; **Sw** 119  
patella, **H** 5, 11; **O** 35; **S** 57; **G** 75; **L** 93; **Sw** 113; **C** 131  
phalanges, **H** 5, 8, 9; **O** 35; **S** 57; **G** 75, 79; **L** 93; **Sw** 113; **C** 131, 132, 133  
premaxilla, **C** 131, 138, 139  
presphenoid, **O** 40  
pubis, **H** 5; **O** 35; **S** 57; **G** 75; **L** 93; **Sw** 113, 117; **C** 131, 133, 134, 135, 140  
pygostyle, **C** 131, 133, 134, 135, 138, 139  
quadrate, **C** 131, 138  
radius, **H** 5; **O** 35; **S** 57; **G** 75; **L** 93; **Sw** 113; **C** 131  
trochlea, **O** 35  
ribs, **H** 5, 20; **O** 35, 38, 39, 44; **S** 57, 64, 64; **G** 75, 81, 84, 85; **L** 93, 104; **Sw** 113, 122; **C** 131, 134, 135  
rib margin, **G** 73; **L** 91  
uncinate process, **C** 131, 134  
rostral, **Sw** 113, 118, 119  
sacrum, **H** 5, 20, 22, 25; **O** 35, 44, 46, 47; **S** 57, 64, 66, 67; **G** 75, 84, 86; **L** 93, 106, 107; **Sw** 113, 117, 122, 124, 125  
scapula, **H** 3, 5; **O** 35; **S** 57; **G** 75; **L** 93; **Sw** 113, 122; **C** 131, 134, 135  
acromion, **O** 35, 39; **S** 57; **G** 75, 81; **L** 93  
scapular cartilage, **H** 5; **O** 35, 38; **S** 57; **G** 75; **L** 93; **Sw** 113  
scapular spine, **H** 5; **O** 35, 37, 39; **S** 57; **G** 75; **L** 93; **Sw** 113  
scleral, **C** 131  
sesamoid  
distal, **H** 5, 8; **O** 35; **S** 57; **G** 75; **Sw** 113  
hypotarsal, **C** 131  
metatarsal, **Sw** 113  
proximal, **H** 5, 8; **O** 35; **S** 57; **G** 75, 79; **L** 93; **Sw** 113

sphenoid, **H** 14; **L** 99; **Sw** 118  
splint. *See* **H** 5, second and fourth metacarpal and metatarsal bones  
sternum, **H** 5; **O** 35, 39, 45; **S** 57, 61; **G** 75, 81; **Sw** 113, 122; **C** 131, 134, 135  
caudolateral process, **C** 131, 134  
keel, **C** 131, 134  
manubrium, **H** 5; **O** 35  
thoracic process, **C** 131, 134, 135  
xiphoid process, **H** 5; **O** 35, 44; **S** 57  
talus, **H** 5; **O** 35; **S** 57; **G** 75; **Sw** 113  
tarsal, **H** 5; **O** 35; **S** 57; **G** 75; **L** 93, 97; **Sw** 113  
tarsometatarsal, **C** 131, 132  
temporal, **H** 5; **O** 35; **S** 57; **G** 75, 82; **L** 93, 102; **Sw** 119; **C** 131  
external acoustic meatus, **H** 5, 13; **O** 45; **G** 85; **C** 131  
temporal fossa, **O** 38; **G** 75  
zygomatic arch, **H** 13  
tibia, **H** 5; **O** 35; **S** 57; **G** 75; **L** 93; **Sw** 113  
lateral condyle, **O** 35; **S** 57; **G** 75; **L** 93  
lateral malleolus, **O** 35; **S** 57; **G** 75; **L** 93  
medial malleolus, **S** 57; **G** 75; **L** 93  
tibiotarsal, **C** 131, 134, 135  
ulna, **H** 5; **O** 35; **S** 57; **G** 75; **L** 93; **Sw** 113; **C** 131  
olecranon, **H** 5; **G** 75  
olecranon tuber, **H** 2, 5, 10; **O** 32, 35; **S** 57; **G** 75; **L** 93; **Sw** 113  
vertebrae, **H** 5; **O** 35; **S** 57; **G** 75; **L** 93; **Sw** 113; **C** 131  
caudal, **O** 47; **S** 57, 67; **G** 75; **L** 93; **Sw** 113, 117, 122, 125; **C** 131, 134, 136, 138, 139  
cervical, **O** 44; **S** 57, 64; **G** 75; **L** 93, 101, 104; **Sw** 113, 122; **C** 131, 138, 139  
lumbar, **O** 44, 46, 47; **S** 57, 63, 64, 66, 67; **G** 75, 86, 87; **L** 93, 104, 105, 106, 107; **Sw** 113, 117, 122, 124, 125  
spinous process, **O** 35  
transverse process, **O** 35  
sacral. *See* sacrum  
thoracic, **H** 5, 20; **O** 44; **S** 57, 63, 64; **G** 75; **L** 93, 104, 105; **Sw** 17, 122; **C** 131, 138, 139  
vomer, **O** 40



zygomatic, **H** 5; **O** 35; **S** 57; **G** 75; **L** 93, 102; **Sw** 113, 119  
zygomatic arch, **H** 5; **O** 35, 39; **G** 81; **L** 97; **C** 131  
Brachial plexus. *See* Nerve(s)  
Brain, **H** 29; **L** 99  
brainstem, **H** 14; **O** 40; **G** 83; **L** 99  
cerebellum, **H** 14, 28; **O** 40, 50; **G** 83; **L** 99; **Sw** 118  
cerebrum, **H** 14, 28; **O** 40, 50; **G** 83; **L** 99; **Sw** 118  
hypophysis cerebri, **G** 83; **L** 99; **Sw** 118  
medulla, **Sw** 118  
Breast, **S** 56  
Brisket, **O** 32; **S** 54; **G** 72; **L** 90  
Buttock, **H** 3

## C

---

Calcaneal tuber. *See* Bone(s)  
Calcar. *See* Spur  
Carcass cuts  
of the hog, **Sw** 112  
of the lamb, **S** 56  
Carpus, **H** 2; **O** 32, 33; **S** 54, 55; **G** 72, 73; **L** 90, 91; **Sw** 110, 111  
Cartilage (**S**)  
alar, **H** 14  
arytenoid, **H** 14; **O** 40; **Sw** 118  
costal, **H** 20; **O** 35, 44; **S** 57; **G** 75; **L** 93; **Sw** 113, 117  
cricoid, **H** 14; **O** 40; **G** 83; **L** 99; **Sw** 118  
epiglottic, **H** 14; **O** 40  
lateral c. of distal phalanx, **H** 12  
scapular, **H** 5; **O** 35, 38; **L** 93; **Sw** 113  
thyroid, **H** 14; **O** 40; **G** 83; **L** 99; **Sw** 118  
tibial, **C** 132  
xiphoid, **H** 5, 13  
Cecum (ceca), **H** 12, 16, 17, 18, 19; **O** 38, 42; **S** 60; **L** 103; **Sw** 120; **C** 134, 135, 136  
apex, **H** 16, 17, 18, 19; **Sw** 117  
base, **H** 12, 16, 17, 18, 19  
body, **H** 12, 16, 17  
Cerebellum. *See* Brain  
Cerebrum. *See* Brain  
Cheek, **Sw** 110

Chest, **H** 3; **Sw** 110  
Chestnut, **H** 2, 3  
Chin (mentum), **H** 3  
Chin groove, **H** 2  
Chyle cistern, **H** 27; **O** 51  
Claw, **G** 79; **C** 128  
Clinical and husbandry conditions:  
Cutting canine and upper incisor teeth in South American camelids, **L** 102  
Left displacement of abomasum in a bull, **O** 43  
Left dorsal displacement of large colon, **H** 19  
Placement of halter on the head of a South American camelid, **L** 100  
Relations of jugular vein in the lama, **L** 101  
Right dorsal displacement of large colon, **H** 18  
Right volvulus of abomasum in a cow, **O** 42  
Untrimmed and trimmed hoofs of the goat, **G** 79  
Clitoris. *See* Vulva  
Cloaca, **C** 134, 136, 138, 139, 140  
cloacal bursa, **C** 134, 136, 138  
coprodeum, **C** 140  
phallic bodies, **C** 140  
proctodeum, **C** 140  
urodeum, **C** 140  
Colliculus seminalis, **O** 46  
Colon, **C** 136, 140, 141  
ascending, **H** 16; **O** 38; **G** 80  
descending, **H** 13, 16, 17, 18, 23; **O** 38, 47; **S** 66, 67; **G** 80, 81, 87; **L** 97, 103, 107; **Sw** 120, 123, 125  
large, **H** 13, 16, 17, 18, 19  
left dorsal, **H** 13, 16, 17, 18, 19  
left ventral, **H** 13, 16, 17, 18, 19  
proximal loop of ascending, **O** 38; **G** 80; **L** 96, 97, 103  
right dorsal, **H** 12, 16, 17  
right ventral, **H** 12, 16, 17  
sigmoid, **O** 47; **S** 60  
small. *See* descending colon, **H** 13, 16, 17, 18  
spiral loop of ascending, **S** 61; **G** 81; **L** 97, 103; **Sw** 117, 120  
transverse, **H** 16, 17; **Sw** 120  
Comb, **C** 128, 129  
Concha(e), **H** 14; **G** 83; **L** 99; **Sw** 118

Coprodeum. *See* Cloaca  
Corium of foot, **H 9; G 79**  
Cornual process, **O 38**  
Coronet, **H3**  
Coxal tuber. *See* Bone(s)  
Crest, **H2**  
Crop. *See* Ingluvies  
Croup, **H 2**  
Crus, **H 2; O 36; S 55; L 90, 91**

---

## D

---

Dental pad, **O 40, 44; S 60; G 82, 83, 84; L 99**  
Dermis of foot. *See* Corium of foot  
Dewclaws, **O 32, 33; G 72, 73, 78, 79**  
Dewlap, **O 33**  
Diaphragm, **H 20, 21; O 40, 42, 43, 44, 45; G 84; L 105; Sw 123**  
Digit(s), **H 2, 8; O 33, G 78, 79; L 96; Sw 110, 113; C 128, 129, 131, 132, 133**  
    accessory, **Sw 110**  
Digital cushion, **H 8; G 79**  
Digital pad. *See* Slipper  
Digital sheath, **H 8**  
Diverticulum ventriculi. *See* Stomach  
Dock. *See* Tail head  
Ductus deferens, **H 20, 22; O 44, 46; S 64, 66; G 84, 86; L 104, 106; Sw 122, 124; C 136, 138, 140**  
    ampulla, **H 22; S 66; L 106**  
    convoluted part, **H 22**  
    papilla, **C 140**  
Duodenum, **H 12, 16; O 38, 42, 43; S 60, 64; G 80; L 96, 103; Sw 120; C 134, 135, 136, 138**  
    ampulla, **L 103, 104**

---

## E

---

Ear. *See also* Pinna  
    ear feathers. *See* Feather(s)  
    ear lobe, **C 128, 129**  
    “flop” ear, **Sw 110**  
    “prick” ear, **Sw 111**  
Elbow, **C 128**

Epididymis, **H 22; O 44, 46; G 84, 86; L 104, 106; Sw 122, 124**  
Epiglottis, **O 40; G 83; L 99; Sw 118**  
Ergot, **H 3**  
Esophagus, **H 12, 13, 14, 20, 21; O 38, 39, 40, 41, 44; S 60, 61, 62, 64, 65; G 80, 81, 83, 84, 85; L 99, 101, 103, 105; Sw 117, 120, 123; C 132, 134, 136, 138, 139**  
External acoustic meatus. *See* Temporal bone, **H 5, G 45**  
External auditory canal, **C 128, 132**  
Eyelid  
    third, **C 128**  
    upper, **H 2; Sw 110; C 128**

---

## F

---

Face, **H 2; O 32, 33; S 54; G 72, 73; L 90**  
Facial crest, **H 3**  
Fascia  
    abdominal, **O 36; S 58; G 76; L 94**  
    antebrachial, **H 6; O 36; S 58; G 76; L 94; Sw 114**  
    cervical, **H 6; L 94**  
    crural, **H 6; O 36; S 58; G 76; L 94; Sw 114**  
    fascia lata, **H 6, 7; O 36; S 58; G 76; L 94; Sw 114**  
    femoral, **H 6; O 36; S 58; G 76; Sw 114**  
    omobrachial, **G 76**  
    superficial f. of trunk, **H 6; O 36; S 58; G 76; L 94; Sw 114**  
    superficial gluteal, **H 6; O 36; S 58; G 76; L 94; Sw 114**  
    thoracolumbar, **H 7; O 37; S 59; G 77; L 95; Sw 115**  
Feather(s)  
    covert, **C 130**  
    ear, **C 128, 129, 130**  
    f. tracts, **C 130**  
    rectrices (tail f.), **C 120, 130**  
    remiges (flight f.), **C 129, 130**  
    sickle, **C 130**  
    wing bar, **C 130**  
    wing bow, **C 130**  
Fetlock, **H 2; O 32; S 54; G 72; L 90; Sw 110**  
Flank, **S 56; L 90; Sw 110. See also** Fold, flank  
Flexures  
    diaphragmatic f. of ascending colon, **H 16, 17, 19**



duodenojejunal, **H** 16  
pelvic f. of ascending colon, **H** 16, 17, 18, 19  
sternal f. of ascending colon, **H** 16, 17

#### Fold

alar, **H** 14; **O** 40; **G** 83  
basal, **H** 14; **G** 83  
cecocolic, **H** 16  
flank, **H** 22; **O** 32, 33; **S** 54; **G** 72, 73; **Sw** 110  
genital, **H** 22  
vestibular, **H** 14  
vocal, **H** 14; **G** 83; **L** 99; **Sw** 118

Foot, **H** 1, 2; **S** 54; **L** 90

#### Foramen (foramina)

infraorbital, **H** 5; **O** 35; **S** 57, **G** 75; **L** 93; **Sw** 113, 119  
mental, **H** 5; **O** 35; **S** 57; **G** 75; **L** 93; **Sw** 113, 119  
obturator, **C** 131

Forearm, **H** 2; **O** 33; **G** 72; **L** 90

Forecannon, **H** 2

Forehead, **H** 2

Forelock, **H** 3

Foresaddle, **S** 56

Foreshank, **O** 32, 33; **S** 54, 56; **G** 72; **L** 90

Frog stay, **H** 9

## G

---

Gallbladder, **O** 38, 43, 44; **S** 60; **G** 80, 84

Gambrel cord, **S** 56

Ganglia. *See* Autonomic nervous system

Gaskin, **H** 2

Girth, **H** 3; **O** 32

Gizzard. *See* Ventriculus

#### Gland(s)

bulbourethral, **H** 20, 22; **O** 46; **S** 66; **G** 84, 86; **L** 104, 106; **Sw** 122, 124

carpal, **Sw** 110

infraorbital, **S** 54, 55

inguinal, **S** 55

interdigital, **S** 54

major vestibular, **S** 69

mammary, **H** 21, 23; **O** 47; **S** 65, 67; **G** 85, 87; **Sw** 111, 125

mandibular, **S** 62

metatarsal scent gland complex, **L** 90, 91  
of snout, **Sw** 118

parotid, **H** 7; **O** 37; **S** 59, 62; **G** 77; **L** 95; **Sw** 115, 118

prostate, **H** 22; **O** 46; **L** 106; **Sw** 124

seminal vesicle, **H** 20, 22

thyroid, **H** 13; **S** 62; **G** 81; **L** 97

uropygial, **C** 132, 133

vesicular, **O** 46, **S** 66; **G** 86; **Sw** 122, 124

Glandular sacculles, **L** 96, 103, 105

Greater tubercle of humerus. *See* Bone(s)

## H

---

Heart, **H** 12, 13, 20, 21; **O** 39, 38, 44, 45; **S** 61, 65; **G** 80, 81, 84; **L** 96, 97; **Sw** 117; **C** 134

apex, **O** 44

left atrium, **C** 134

left auricle, **H** 21; **O** 45; **S** 65; **Sw** 123

left ventricle, **H** 20, 21; **S** 65; **G** 85; **L** 105; **Sw** 123; **C** 135, 139

right atrium, **O** 44, 45; **G** 84; **L** 104; **Sw** 122; **C** 138

right auricle, **H** 21; **O** 45; **S** 65; **G** 85; **L** 105; **Sw** 123

right ventricle, **H** 21, 22; **S** 64; **G** 84; **L** 104; **Sw** 122; **C** 138

Hindcannon, **H** 2

Hindsaddle, **S** 56

Hindshank, **O** 38; **S** 54, 56; **G** 72; **L** 90

Hip, **C** 129

point of, **H** 3. *See also* Hook

Hock, **H** 2, 11; **O** 32; **S** 54; **G** 72; **L** 90; **Sw** 111; **C** 128, 129

Hoof(s), **H** 3, 8, 9, 24; **O** 32; **S** 55; **G** 72, 73, 79; **Sw** 111

Hook, **O** 32; **G** 73

Horn, **O** 32; **S** 54; **G** 72

Hyoid apparatus, **H** 13. *See also* Bone(s)

Hypophysis cerebri. *See* Brain

## I

---

Ileocecal junction, **Sw** 120

Ileum, **H** 16; **L** 103; **Sw** 120; **C** 135, 136

Ingluvies, **C** 128, 132, 133, 134, 135, 136, 138, 139

Inguinal canal, **H** 22

Interdigital cleft, **G 72**  
Internal inguinal ring, **H 22; O 46; G 86; L 106**  
Intervertebral disc, **H 13**  
Intestines. *See* Cecum, Colon, Duodenum, Ileum,  
Jejunum, Rectum  
Ischiatic tuber, *See* Bone(s)

---

## J

---

Jaw, **H 3; O 33**  
Jejunum, **H 13, 16; O 38, 39, 41, 42; S 60, 61; G 80, 81; L 96, 97, 103; Sw 116, 117, 120; C 136**  
Joint(s)  
  ankle, **H 2; C 135**  
  antebrachiocondylar, **H 13; O 39; S 61; G 81; L 97; Sw 117**  
  atlantoaxial, **H 5**  
  atlanto-occipital, **H 5; S 64; G 81; L 97**  
  break joint, **S 56**  
  carpometacarpal, **H 13; O 39; S 61; G 81; L 97; Sw 117**  
  coffin, **H 8, 13; O 39; S 61; G 81**  
  costovertebral, **H 5, 13; O 39; Sw 117**  
  coxal, **H 13; O 39; G 81; L 97; Sw 117; C 135**  
  cubital, **O 39; L 97**  
  distal interphalangeal, **H 13; O 39; S 61; G 81; L 97; Sw 117**  
  elbow, **H 13; O 39; S 61; G 81; L 97; Sw 117**  
  femoropatellar, **H 13; O 39; S 61; G 81; L 97; Sw 117**  
  femorotibial, **H 11, 13; O 39; S 61, 64; G 81; L 97; Sw 117; C 135**  
  fetlock, **H 8, 13; O 39; S 61; G 81; L 97**  
  hip, **H 13; O 39; S 61; G 81; L 97; Sw 117; C 135**  
  humerocondylar, **H 13**  
  humerocondylar, **H 13**  
  intertarsal, **H 13; O 39; S 61; G 81; L 97; Sw 117**  
  metacarpophalangeal, **H 13; O 39; S 61; G 81; L 97; Sw 117**  
  metatarsophalangeal, **H 13; O 39; S 61; G 81; L 97; Sw 117**  
  middle carpal, **H 13; O 39; S 61; G 81; L 97; Sw 117**  
  pastern, **H 8, 13; O 39; S 61; G 81**  
  proximal interphalangeal, **H 8, 13; O 39; S 61; G 81; L 97; Sw 117**

sacroiliac, **H 13; S 61; G 81; L 97; Sw 117**  
scapulohumeral, **H 13**  
shoulder, **H 13; O 39; S 61; G 81; L 97; Sw 117; C 135**  
sternocostal, **H 13**  
stifle, **H 13; O 39; S 61; G 81; L 97; Sw 117**  
tarsocrural, **H 13; O 39; S 61; G 81; L 97; Sw 117**  
tarsometatarsal, **H 13; O 39; S 61; G 81; L 97; Sw 117**  
temporomandibular, **H 13; G 81; L 97; Sw 117**  
wrist (carpal), **C 133**

Joint capsule  
  coffin, **H 8**  
  fetlock, **H 8**  
  pastern, **H 8**  
Jowl, **H 3; O 33; Sw 110, 111, 112**  
Jugular groove, **H 2, 3; O 32, 33; G 73**

---

## K

---

Kidneys, **H 19, 20, 21; O 38, 44; S 60, 64, 65; G 80; L 96, 104, 105; Sw 116, 117, 122, 123; C 138, 139, 140**  
Knee, **H 2; O 32, 33; S 54, 55; G 72; L 90; Sw 110, 111; C 129**

---

## L

---

Labial vestibule, **Sw 118**  
Lacertus fibrosus, **H 10**  
Larynx, **H 13, 14; Sw 117**  
  laryngeal ventricle, **H 14**  
Lateral ala, **H 2**  
Left flank incision  
Leg, **H 2; O 32; S 54; G 72; L 90, 91; Sw 111; C 129**  
  "Leg" of lamb, **S 54, 56**  
Ligament(s)  
  accessory l. of deep digital flexor m., **H 10**  
  accessory l. of superficial digital flexor m., **H 10**  
  broad l. of uterus, **S 67, 69; L 107; Sw 125**  
  broad sacrotuberal, **H 12, 13; O 38, 39; S 61; G 81; L 97; Sw 116**  
  carpal check, **H 10**  
  collateral sesamoidean, **H 8**  
  digital annular, **G 78**  
  distal digital annular, **H 12**



distal sesamoidean, **H** 10, 11  
 distal sesamoidean impar, **H** 8  
 dorsal l. of tarsus, **O** 37; **G** 77  
 interdigital, **G** 78  
 middle l. of bladder, **H** 24; **G** 86; **Sw** 124  
 nephrosplenic, **H** 19  
 nuchal, **H** 13, 14, 21; **O** 39, 40; **S** 61; **G** 81, 83; **L** 95, 96, 97, 99, 105  
 palmar anular, **H** 8  
 radial check, **H** 10  
 supraspinous, **H** 21; **O** 38, 39; **S** 61; **G** 81; **L** 96, 97  
 suspensory (interosseus medius m.), **H** 7, 10, 11; **O** 37; **S** 59; **G** 77; **L** 95, 98  
 "T", **H** 7  
 triangular l. of liver, **H** 21  
 ventral l. of oviduct, **C** 141  
 Linea alba, **G** 86; **L** 106  
 Lingual fossa. *See* Tongue  
 Lips, **H** 14; **O** 40; **G** 73, 83; **L** 99; **Sw** 110, 118  
 Liver, **H** 12, 20, 21, 24; **O** 38, 42, 43, 44; **S** 60; **G** 80, 84; **L** 96, 104; **Sw** 116, 117, 122, 123; **C** 134, 135  
     caudate process of caudate lobe, **O** 44  
     left lobe, **H** 21; **O** 44  
     quadrate lobe, **H** 20; **O** 44  
     right lobe, **H** 20; **O** 44; **L** 104  
 Loin, **H** 2; **O** 32; **S** 54.56; **G** 72; **L** 90; **Sw** 110, 111, 112  
 Lower foreshank, **S** 54, 56  
 Lower hindshank, **S** 54, 56  
 Lumbosacral plexus. *See* Nerve(s)  
 Lung, **H** 12, 13; **O** 38, 39, 40; **S** 60, 61; **G** 80, 81; **L** 96, 97; **Sw** 116, 117; **C** 134, 135, 137  
 Lymph node(s)  
     axillary, **H** 27; **O** 51; **Sw** 121  
     caudal deep cervical, **H** 27; **O** 51; **Sw** 121  
     caudal mediastinal, **O** 45; **S** 65; **G** 84, 5  
     caudal mesenteric, **H** 27  
     cranial deep cervical, **H** 27, **O** 51; **Sw** 121  
     deep inguinal, **H** 27  
     dorsal thoracic, **H** 27  
     epigastric, **O** 51  
     gluteal, **O** 51; **Sw** 121  
     intercostal, **O** 51

lateral iliac, **O** 51; **Sw** 121  
 lateral retropharyngeal, **H** 27; **O** 38, 51, 56; **Sw** 121  
 lumbar aortic and renal, **H** 27; **O** 51; **Sw** 121  
 mandibular, **H** 27; **O** 51; **S** 62; **Sw** 121  
 medial iliac, **H** 27; **O** 51; **Sw** 121  
 medial retropharyngeal, **H** 27; **O** 51; **Sw** 121  
 mediastinal, **H** 27; **L** 104; **Sw** 121  
 mesenteric, **H** 27; **O** 51; **Sw** 121  
 middle deep cervical, **H** 27; **O** 51; **Sw** 121  
 parotid, **H** 27; **O** 51; **Sw** 121  
 popliteal, **H** 27; **O** 51; **Sw** 121  
     deep, **Sw** 121  
     superficial, **Sw** 121  
 sacral, **H** 27; **Sw** 121  
 sternal, **O** 51; **Sw** 121  
 subiliac, **H** 7, 27; **O** 36, 51; **G** 77; **L** 93; **Sw** 114, 121  
 superficial cervical, **H** 27; **O** 38, 51; **L** 101  
     dorsal, **Sw** 121  
     ventral, **Sw** 121  
 superficial inguinal, **H** 27; **O** 39, 51; **S** 66, 67; **G** 81, 84; **L** 106, 107; **Sw** 121, 124, 125  
 supramammary, **O** 39, 51; **L** 107; **Sw** 121  
 thoracic aortic, **Sw** 121  
 tracheobronchial, **H** 27; **O** 51  
 ventral thoracic, **H** 27  
 Lymph vessels, **H** 27; **O** 51  
     chyle cistern, **H** 27; **O** 51  
     intestinal trunk, **H** 27; **O** 51; **Sw** 121  
     left tracheal trunk, **O** 51; **Sw** 121  
     lumbar trunk, **H** 27; **O** 51; **Sw** 121  
     right tracheal trunk, **H** 27  
     thoracic duct, **H** 27; **O** 51; **Sw** 121

## M

---

Mammary glands. *See* Gland(s) and Udder  
 Mane, **H** 3  
 Manica flexoria, **L** 98  
 Manus (hand), **H** 3; **C** 128  
 Meatus, dorsal, middle, ventral, **H** 14; **O** 40; **G** 83; **L** 99; **Sw** 118  
 Medial canthus, **O** 32  
 Mesocolon, **G** 87

Mesometrium **H 23; O 47**  
 Mesosalpinx, **H 23; S 69**  
 Mesovarium, **H 23; O 47; S 67, 69**  
 Metacarpal tuberosity, **H 10. See Bone(s)**  
 Metacarpus, **H 2; O 32, 33; S 54; G 72; L 90; Sw 111**  
 Metatarsal cushion, **C 128**  
 Metatarsus, **H 2; O 33; S 54; G 72; L 90; Sw 111**  
 Milk well, **O 33**  
 Muscle(s)  
     accessory patagial, **C 133**  
     adductor, **O 46; S 60; G 80; L 96, 106; Sw 116, 124, 125**  
     ascending pectoral, **H 7; O 37; S 59; G 77; L 95; Sw 115**  
     biceps brachii, **H 7; O 38; S 60; G 80; L 96; Sw 116; C 133**  
     biceps femoris, **H 7; Sw 115; C 132, 133**  
     biventer. *See Semispinalis capitis*, **Sw 117; C 132–135**  
     brachialis, **H 7; O 37; S 59, 60; G 77, 80; L 95, 96; Sw 115, 116**  
     brachiocephalicus, **H 7; O 38; S 59, 62; L 95, 101; Sw 115**  
     buccinator, **H 7; O 37; S 59; G 77; L 95; Sw 115**  
     bulbospongiosus, **H 20; O 46; G 84, 86; L 106; Sw 124**  
     bulbourethral, **Sw 124**  
     caninus, **H 7; O 36; Sw 115**  
     caudal capital oblique, **H 12, 13; O 46; S 61; G 81; L 97**  
     caudal preputial, **O 36; Sw 114**  
     caudal scapulohumeral, **C 133**  
     cloacal elevator, **C 132, 133**  
     cloacal sphincter, **C 132, 133, 135**  
     coccygeus, **O 37; S 60; G 80**  
     coccygeus lateralis, **C 132, 133**  
     common digital extensor, **H 7, 10; O 37; S 59; G 77; L 95; Sw 115**  
     complexus. *See Semispinalis capitis*, **Sw 117; C 132–135**  
     cranial capital oblique, **H 13; O 39; S 61; G 81; L 96, 97; Sw 116, 117**  
     cranial preputial, **O 36; Sw 114**  
     cranial tibial, **H 7, 12; O 37; S 59; L 95; Sw 115**  
     cutaneus colli, **H 6; O 36; S 58; G 76; L 93; Sw 114; C 132**  
     cutaneus faciei, **H 6; O 36; S 58; G 76; L 93; Sw 114**  
     cutaneus nasi, **G 76**  
     cutaneus trunci, **H 6; O 36; S 58, 63; G 76; L 93; Sw 114**  
     deep digital flexor, **H 7, 10, 12; O 37, 38; S 59, 60; G 77, 80; L 95, 96; Sw 115, 116; C 133**  
     deltoideus, **H 7; O 37; S 59, 60; G 77, 80; L 95, 96; Sw 115; C 132**  
     depressor labii inferioris, **H 7; S 59; G 77; Sw 115**  
     depressor labii superioris, **H 7; Sw 115**  
     depressor mandibulae, **C 132**  
     depressor palpebrae, **G 77; Sw 115**  
     descending pectoral, **H 7; O 37; G 77; L 95**  
     digastricus, **H 12, 13**  
     dilator naris, **H 14**  
     dorsal capital straight, **H 14; O 39; S 61, G 81, 83; L 97, 99, Sw 119**  
     dorsal interosseous, **C 132**  
     extensor carpi obliquus, **H 7, 12; O 37; S 59; G 77; L 95; Sw 115**  
     extensor carpi radialis, **H 7, 10; O 37; S 59; G 77; L 95; Sw 115**  
     extensor metacarpi radialis, **C 132, 133**  
     external abdominal oblique, **H 7; O 37; S 59, 63; G 77; L 95; Sw 115; C 132, 133**  
     external anal sphincter, **H 20, 21; S 66; Sw 124**  
     external mandibular adductor, **C 132**  
     fifth digital extensor, **Sw 115**  
     flexor carpi radialis, **H 7, 10; O 37; S 59; G 77; L 95; Sw 115**  
     flexor carpi ulnaris, **H 7; S 59; G 77; C 133**  
     flexor perforans and perforatus, **C 132**  
     frontalis, **O 36, 37; S 59; G 77; L 95**  
     frontoscutularis, **H 6**  
     gastrocnemius, **H 7, 12; O 37, 38; S 59, 60; G 77, 80; L 95, 96; Sw 115, 116; C 132, 133**  
     genioglossus, **H 14; G 83; L 99; Sw 118**  
     geniohyoideus, **H 14; G 83; L 99; Sw 118**  
     gluteobiceps, **O 37; S 59; G 77; L 95**  
     gracilis, **O 46; Sw 124**  
     hyoepiglottic, **H 14**  
     iliacus, **H 12; O 38**



iliocostalis thoracis, **H 12; O 38; S 60; G 80; L 96; Sw 115, 116**

infraspinatus, **H 12; O 38; S 60; G 80; L 96**

internal abdominal oblique, **H 22; O 37, 47; S 59, 63, 66; G 77; L 95, 107**

interosseus medius, **H 10; O 36; G 78**  
*See also* Suspensory ligament, **H 7, 10, 11; O 37; S 59; G 77; L 95, 98**

interosseus secundus, **L 98**

intertransversarii, **H 12, 13; O 39; S 60, 61, 62; G 81; L 95, 96, 97; Sw 116, 117**

intertransversarius longus, **O 38; S 61; G 81; L 97**

ischiocavernosus, **O 46; S 64, 66; G 84, 86; L 104, 106; Sw 124**

lateral digital extensor, **H 7, 10, 12; O 37; S 59; G 77; L 95; Sw 115**

latissimus dorsi, **H 7; O 37; S 59; G 77; L 95; Sw 115; C 132, 133**

levator ani, **C 132, 133**

levator coccygeus, **C 132, 133**

levator labii superioris, **H 7; O 36; Sw 115**

levator nasolabialis, **H 7; O 36; S 59; G 77; L 95; Sw 115**

long digital extensor, **H 7, 12; O 37; S 59; G 77; L 95**

long patagial tensor, **C 132, 133**

longissimus atlantis, **H 12; O 38; S 60; G 80; L 95; Sw 116, 117**

longissimus capitis, **H 12; O 38; S 60; G 80; L 95, 96; Sw 116, 117**

longissimus cervicis, **H 12; O 38; S 60; G 80; L 95, 96; Sw 117**

longissimus thoracis and lumborum, **H 12; O 38; S 60; G 80; L 96; Sw 116**

longus atlantis, **L 96**

longus capitis, **H 12, 14; S 60; G 80; L 96, 99; Sw 116, 117**

longus coli, **H 12, 14; S 61, 62; G 81, 83; L 97, 99, 101; C 133, 134, 135**

major long digital flexor, **C 133**

malaris, **O 37; S 59; G 77**

masseter, **H 7; O 37; S 59, 62; G 77; L 95; Sw 115**

mentalis, **H 14; Sw 115**

middle gluteal, **H 7, 19; O 37, 38; S 59, 60; G 77, 80; L 95, 96; Sw 115, 116**

multifidus cervicis, **H 13; O 39; S 61; G 80, 81; L 97**

mylohyoideus, **O 37**

obturator internus, **H 23; O 46, 47**

occipital hyoideus, **H 12**

omohyoideus, **H 7, 14; S 62**

omotransversarius, **H 7; O 37; S 59; G 77; L 95; Sw 115**

orbicularis oris, **Sw 115**

parotidoauricularis, **H 7; S 59, 62; G 77; L 95**

peroneus longus, **O 37; S 59; G 77; L 95; Sw 115; C 132, 133**

peroneus tertius, **H 7, 11; O 37; S 59; G 77; L 95; Sw 115**

platysma, **Sw 114**

psoas major, **O 38; Sw 116**

quadratus lumborum, **Sw 116**

quadriceps femoris, **H 11, 12**

rectus abdominis, **H 22; S 66, 67; G 86, 87; L 106, 107; Sw 124, 125**

rectus femoris, **H 12; O 38; S 60; G 80; L 96; Sw 116**

retractor penis, **H 20; O 44, 46; S 64, 66; G 84, 86; L 106; Sw 124**

rhomboideus, **H 7, 12; O 38; S 60; G 80; L 96; Sw 116; C 134**

sacrocaudalis, **O 37**

sartorius, **C 132, 133**

scalenus, **H 12; O 38, 39; S 60; G 80; L 96, 101**

scutularis, **O 36**

semimembranosus, **H 7, 12; O 38; S 59, 60; G 80; L 95, 96; Sw 115, 116; C 132, 133**

semispinalis capitis, **H 12; S 60; G 80; Sw 117, 118**  
 biventer cervicis, **Sw 117; C 132, 133, 134, 135**  
 complexus, **Sw 117; C 132–135**

semitendinosus, **H 7, 12; O 37, 38; S 59, 60; G 80; L 95, 96; Sw 115; C 132, 133**

serratus dorsalis caudalis, **H 7; O 35**

serratus dorsalis cranialis, **G 77; L 95**

serratus superficialis, **C 133**

serratus ventralis, **H 7; O 37; S 59; G 77; L 95, 96; Sw 115, 116**

short digital extensor, **H 12; Sw 115**

Muscle(s)—*Continued*

soleus, **H** 7, 15; **O** 38; **S** 60; **Sw** 116  
spinalis cervicis, **H** 13  
spinalis thoracis, **H** 12  
splenius, **H** 7; **O** 38; **L** 95, 96; **Sw** 116  
sternocephalicus, **H** 7; **O** 37, 38; **S** 59; **G** 77; **L** 95,  
101, 104; **Sw** 115, 116  
sternohyoideus, **H** 14; **O** 38; **S** 60, 62; **G** 80; **L** 95; **Sw**  
115, 116, 118  
sternothyrohyoideus, **H** 10, 11, 13; **O** 38; **S** 60, 62; **G**  
77, 80; **L** 95; **Sw** 116; **C** 132, 133, 134  
sternothyroideus, **O** 38  
subclavius, **H** 7; **Sw** 115  
superficial gluteal, **H** 7; **Sw** 115  
superficial pectoral, **C** 132, 133  
superficial pronator, **C** 133  
supraspinalis, **H** 12; **O** 38; **S** 60; **G** 80; **L** 96; **Sw** 115  
temporalis, **H** 7; **O** 38  
tensor fasciae antebrachii, **Sw** 115  
tensor fasciae latae, **H** 7, 11; **O** 37; **S** 59; **G** 77; **L** 95;  
**Sw** 115; **C** 132, 133  
teres minor, **H** 12  
thoracic and cervical spinalis and semispinalis, **O**  
38, 39; **S** 60, 61; **G** 80, 81; **L** 96, 97; **Sw** 116  
transverse abdominal, **O** 47; **S** 63  
trapezius, **H** 7; **O** 37; **S** 59; **G** 77; **L** 95; **Sw** 115  
triceps brachii, **H** 7, 10; **O** 37; **S** 59; **G** 77; **L** 95;  
**Sw** 115; **C** 133  
ulnaris lateralis, **H** 7; **O** 37; **S** 59; **L** 95; **Sw** 115  
urethralis, **H** 22; **O** 46; **S** 66; **G** 84; **L** 104, 106; **Sw** 124  
vastus lateralis, **H** 12; **O** 38; **S** 60; **G** 80; **L** 96; **Sw** 116  
zygomaticoauricularis, **S** 59; **G** 77; **L** 95  
zygomaticus, **H** 7; **O** 37; **S** 59; **G** 77; **L** 95; **Sw** 115  
Muzzle, **H** 3; **O** 32; **S** 54; **G** 72; **L** 90  
nasolabial plane of, **O** 33

**N**

Nasal septum, **H** 14; **L** 99  
Navicular bursa, **H** 8  
Neck, **H** 2; **O** 32; **S** 54, 56; **G** 72; **L** 90; **Sw** 111  
Nerve(s)  
accessory, **H** 28; **O** 50

axillary, **H** 28; **O** 50  
brachial plexus, **H** 28; **O** 50  
caudal cutaneous antebrachial, **H** 28; **O** 50  
caudal cutaneous sural, **H** 28  
caudal laryngeal, **S** 62  
caudal rectal, **H** 28  
cervical, **H** 28; **O** 50; **S** 62  
common peroneal, **H** 28; **O** 36, 38, 50  
communicating branch, **H** 28  
cornual branch of lacrimal, **G** 82  
cranial gluteal, **O** 50  
deep peroneal, **H** 28; **O** 50  
dorsal br. of lateral palmar digital, **H** 28  
dorsal br. of lateral plantar digital, **H** 28  
dorsal common digital II, III, & IV, **G** 78; **L** 98  
dorsal digital, **O** 58  
dorsal proper (abaxial & axial) digital III & IV, **G** 78;  
**L** 98  
dorsal spinal, **H** 28; **O** 50  
facial, **H** 7, 28, 29; **O** 37, 50; **G** 77; **Sw** 115  
femoral, **H** 28; **O** 50  
genitofemoral, **H** 28; **O** 50  
glossopharyngeal, **H** 29  
ilioinguinal, **H** 28; **O** 50  
infraorbital, **H** 7, 28; **O** 50  
infratrochlear, cornual br. & frontal br., **G** 82  
intercostal, **H** 28; **O** 50  
lateral cutaneous antebrachial, **H** 28  
lateral cutaneous femoral, **H** 28  
lateral dorsal metatarsal, **H** 28  
lateral palmar, **H** 28  
lateral palmar digital, **H** 28  
lateral plantar, **H** 28  
lateral plantar digital, **H** 28  
lateral thoracic, **H** 28; **O** 50  
long thoracic, **H** 28; **O** 50  
lumbar plexus, **H** 28; **O** 50  
mandibular, **H** 28; **O** 50  
mandibular alveolar, **H** 28  
maxillary, **O** 50  
medial cutaneous antebrachial, **H** 28; **O** 50  
medial dorsal metatarsal, **H** 28



medial palmar, **H 28**  
medial palmar digital, **H 28**  
medial plantar, **H 28**  
medial plantar digital, **H 28**  
median, **H 28; O 50; G 78**  
musculocutaneous, **H 28; O 50**  
obturator, **H 28; O 50**  
oculomotor, **H 28, 29**  
olfactory, **H 28; O 50**  
ophthalmic, **H 28; O 50**  
optic, **H 28; O 50**  
palmar common digital II, III, & IV, **G 78; L 98**  
palmar digital, **O 50**  
palmar proper (abaxial & axial) III & IV, **G 78; L 98**  
parasympathetic, **H 29**  
plantar digital, **O 50**  
pudendal, **H 28; O 50**  
radial, **H 28; O 50; G 80**  
    superficial br., **O 50; G 78; L 98**  
saphenous, **H 28; O 50**  
sciatic, **H 28; O 38, 50; G 80, 81; L 97; Sw 116**  
subscapular, **H 28; O 50**  
suprascapular, **H 28; O 50**  
sympathetic, **H 29**  
thoracodorsal, **H 28; O 50**  
tibial, **H 28; O 38, 50; G 80**  
ulnar, **H 28; O 50**  
    dorsal br., **H 28; G 78; L 98**  
    palmar br., **O 50; G 78; L 98**  
    vagus, **H 28, 29; O 50; S 62; L 99**  
Nostril (naris), **H 2, 3, 14; O 32, 33; S 54; G 72, 73; L 90, 99, 100; C 128, 129**  
Notarium. *See* Bone(s)

---

## O

Olecranon tuber. *See* Bone(s)  
Omasum, **O 38; S 64; G 80, 84**  
Omentum  
    greater, **O 39, 43; Sw 116**  
    lesser, **O 42, 43**  
Optic chiasm, **H 14; G 83; L 99**  
Oral cavity, **H 14; O 40; Sw 118**

Orbit, **H 12; O 32, 38; S 57; G 72, 75; L 91, 102; C 131**  
Orifice  
    cecocolic, **H 16**  
    ileal, **H 16**  
Ovary, **H 22, 23; O 45, 47; S 65, 67, 69; G 85, 87; L 105, 107; Sw 123, 125; C 135**  
    ovarian follicles, **C 135, 139, 141**  
Oviduct, **C 135, 139, 141**  
    infundibulum, **C 141**  
    isthmus, **C 139, 141**  
    magnum, **C 139, 141**  
    opening of, **C 141**  
    uterus (shell gland region), **C 139, 141**  
    vagina, **C 139, 141**

---

## P

Palate  
    hard, **H 14; O 40; G 83; L 99; Sw 118**  
    soft, **H 14; O 40; G 83; L 99; Sw 118**  
Pancreas, **C 134**  
Paralumbar fossa, **H 3; O 33; S 54; G 72, 73; L 90**  
Pastern, **H 2; O 32; S 54; G 72**  
Pelvic symphysis, **H 21, 22, 23; O 46; S 66, 67; G 86, 87; L, 106, 107; Sw 124, 125**  
Penile sheath, **O 32**  
Penis  
    body, **H 20; G 86; L 104, 106; Sw 122, 124**  
    bulb, **Sw 122**  
    corpus cavernosum penis, **H 22; O 46; S 68**  
    corpus cavernosum urethrae, **S 68**  
    corpus spongiosum, **H 22; O 46; S 68**  
    free part, **S 66, 68**  
    glans penis, **H 20, 22; O 44, 46; S 64, 66, 68; G 84, 86; L 106; Sw 122, 124**  
    fossa glandis, **H 22**  
    urethral process, **H 22; O 44; S 64, 66, 68; G 84, 86**  
    urethral sinus, **H 22**  
    raphe, **S 68**  
    right crus, **S 66; Sw 124**  
    sigmoid flexure, **O 44, 46; S 64, 66; G 84, 86; L 104, 106; Sw 122**

Penis—*Continued*

- spongy tubercle, **S** 68
- Peritoneal cavity, **S** 63
- Peritoneum. *See* Serosa, **S** 63
- Pes, **H** 2
- Phallic bodies. *See* Cloaca
- Pharynx, **C** 136
  - laryngopharynx, **O** 40; **G** 83; **L** 99; **Sw** 118
  - nasopharynx, **H** 14; **O** 40; **G** 83; **L** 99; **Sw** 118
  - oropharynx, **H** 14; **O** 40; **G** 83; **L** 99; **Sw** 118
  - pharyngeal recess, **Sw** 118
  - pharyngeal septum, **O** 40; **G** 83
  - pharyngeal tonsil, **G** 83
- Pin, **O** 32
- Pinna, **H** 3; **O** 32, 33; **S** 54, 59; **G** 72, 73; **L** 90, 91
- Point
  - of elbow, **H** 2; **O** 32; **G** 73; **L** 91; **Sw** 110
  - of hip, **H** 3; **Sw** 111
  - of hock, **H** 3; **O** 33; **S** 55; **G** 73; **L** 91; **Sw** 110
  - of shoulder, **H** 2; **O** 32; **G** 73; **L** 91; **Sw** 111
- Poll, **H** 2; **O** 32, 33; **G** 72, 73; **L** 90; **Sw** 111
- Pouch(es)
  - cutaneous, **S** 54, 55
  - guttural, **H** 14
- Preen gland. *See* Gland(s), uropygial
- Prepuce, **H** 2, 22; **S** 54, 68; **G** 76, 86; **L** 106; **Sw** 110, 114, 124
  - external (sheath), **H** 22
  - internal, **H** 22; **S** 68
  - preputial diverticulum, **Sw** 114, 124
  - preputial orifice, **O** 32; **S** 124
- Proctodeum. *See* Cloaca
- Propatagium, **C** 128, 129
- Proventriculus, **C** 135, 136, 138, 139
- Pygostyle. *See* Bone(s)
- Pylorus. *See* Stomach

---

**Q**

- Quarter, **H** 2

---

**R**

- Rack, **S** 56
- Reciprocal apparatus, **H** 11
- Rectum, **H** 16, 20, 21, 23; **O** 41, 45, 46, 47; **S** 61, 65, 66, 67; **G** 80, 84, 86, 87; **L** 103, 105, 106, 107; **Sw** 117, 123, 124, 125; **C** 134, 136, 138, 139, 140, 141
  - ampulla, **H** 23
  - transverse plicae, **H** 22
- Reticulum, **O** 39, 41, 43, 45; **S** 64, 65; **G** 85
- Rib margin. *See* Bone(s)
- Round, **O** 32
- Rumen, **O** 39, 42, 43, 45; **S** 60, 61, 63, 64, 65; **G** 81, 84, 85
  - interior, **O** 41; **S** 63
- Rump, **O** 32; **S** 54; **G** 72; **L** 90; **Sw** 110

---

**S**

- Saddle, **C** 128, 130
- Scrotum, **H** 22; **O** 32, 38; **S** 54, 66; **G** 86; **L** 106; **Sw** 110, 114
  - seminal vesicle. *See* Gland(s)
  - tunica albuginea, **S** 58; **G** 76
- Serosa of rumen, **S** 63
- Shank, **C** 128, 129
- Shoulder, **H** 3; **O** 32; **S** 54, 56; **G** 72; **L** 90; **Sw** 110; **C** 128, 129
- Sinus
  - frontal, **H** 14; **O** 40; **G** 83, 84; **L** 99; **Sw** 118
  - cornual diverticulum, **O** 44; **G** 84
  - sphenoid, **H** 14; **Sw** 118
- Skin & subcutis, **S** 63; **G** 79
- Slipper, **L** 91, 98
- Snout, **Sw** 110, 111
- Spermatic cord, **H** 22; **Sw** 122, 124
- Spinal cord, **H** 14, 28, 29; **O** 50; **G** 83; **L** 99; **Sw** 118
- Spleen, **H** 13, 19, 21; **O** 39, 43, 45, 51; **S** 61; **G** 81; **L** 97; **Sw** 117, 123; **C** 138, 139
- Spur, **C** 128
- Stay apparatus
  - forelimb, **H** 10
  - hindlimb, **H** 11
- Sternocoracoclavicular membrane, **C** 134



Stifle, H 2, 11; O 32; S 61; G 81; L 97; Sw 110  
Stomach, H 16, 21; L 96, 97, 103, 104, 105;  
Sw 116, 117, 120, 122, 123  
diverticulum ventriculi, Sw 120  
gastric compartments, L 96, 97, 103, 104, 105  
proper gastric gland region, L 103, 104  
pyloric antrum, H 16  
pylorus, G 80; Sw 120  
Suburethral diverticulum. *See* Urethra  
Supraglenoid tubercle. *See* Bone(s), scapula  
Switch, O 32  
Synsacrum. *See* Bone(s)

---

## T

---

Tail head, H 2; O 32, 33; G 72; L 90; Sw 110  
Tarsometatarsus, C 129  
Tarsus, H 2; O 32; S 54; G 72; L 90; Sw 111  
Teat(s) H 3; O 33, 45, 47; S 67; G 73; L 97, 105, 107  
streak canal (papillary duct), O 45, 47; S 65, 67; G  
85, 87  
teat sinus, O 45; S 65, 67; G 85, 87  
Tendon(s)  
biceps brachii m., H 10  
common calcaneal, H 7  
common digital extensor m., H 7, 8, 10; G 78, 79; L  
95, 98  
cranial tibial m., H 7; O 37; S 59  
cunean, H 7  
deep digital flexor m., H 7, 8, 10; O 37, 38; S 59, 60;  
G 77, 78, 79, 80; L 95, 98  
extensor carpi obliquus m., H 7; O 36, 37; G 77  
gastrocnemius m., S 56  
gastrocnemius + digital flexor mm., C 132, 133  
lateral digital extensor m., H 7; G 78; L 95, 98  
long digital extensor m., H 7; O 37; S 59; G 77; L 95;  
C 132  
peroneus longus m., S 59  
peroneus tertius m., H 7, 10  
superficial digital flexor m., H 7, 8, 10, 13; O 37, 38;  
S 59, 60; G 77, 78, 79, 80; L 95, 98  
symphyseal, H 22; O 47; S 66, 67; G 86, 87; L 106,  
107; Sw 124, 125

Testis, H 20, 22; O 44, 46; S 64, 66; G 84, 86; L 104, 106;  
Sw 122, 124; C 138, 140  
tunica albuginea, Sw 116  
Thigh, H 2; S 54, 55; G 72; L 90, 91; Sw 111  
Throatlatch, H 2  
Thymus, H 24; O 51; Sw 117  
Toe Nails, L 90, 91, 98  
Tongue, H 14; O 40; G 83; L 99; Sw 118; C 136  
lingual fossa, O 40; G 83  
Tonsil  
palatine, O 40  
pharyngeal, O 40  
Tooth (teeth)  
canine, H 12, 15; G 82; L 102; Sw 119  
cement, H 15  
cheek, G 84  
crown, H 15  
cup, H 15  
dental star, H 15  
dentin, H 15  
enamel, H 15  
incisor, H 13, 14, 15, 24; O 39, 44; S 60; G 80, 82, 84;  
L 102, 105; Sw 119  
infundibulum, H 15  
molar, H 15; O 44; G 82; L 102; Sw 119  
occlusal surface, H 15  
points, H 15  
premolar, H 15; O 44; G 82; L 102; Sw 119  
pulp cavity of, H 15  
root, H 15  
wolf, H 13, 15  
Topline, O 32; S 54  
Trachea, H 13, 14; O 39, 40; S 60, 61, 62; G 80, 81, 83; L  
96, 97, 101; Sw 117, C 132, 134

---

## U

---

Udder, H 21; O 33, 39, 45; S 65, 67; G 73, 77, 81; L 107  
forequarters, O 33, 47; L 107  
gland sinus, O 45; S 65, 67; G 85, 87  
hindquarters, O 33, 47; L 107  
suspensory apparatus, O 45, 47  
Umbilicus, H 24

Umbilicus—*Continued*

umbilical cord, **H 24**  
Uncinate process. *See* Bone(s), ribs  
Urachus, **H 24**  
Ureters, **H 20, 21, 22, 24; O 44, 46; S 64, 65; G 84, 86; L 104, 105, 106; Sw 122, 123, 124, 125; C 136, 138, 140, 141**  
    openings, **C 140, 141**  
Urethra, **H 22, 23, 24; O 46; S 67, 68; G 85, 87; L 107; Sw 123, 125**  
    dorsal diverticulum, **O 46**  
    external urethral orifice, **H 22; S 67, 69**  
    pelvic, **H 22; O 46; G 86; L 106**  
    penile, **H 22; O 46**  
    suburethral diverticulum, **O 47; S 67; L 107; Sw 125**  
    urethral papilla, **O 47**  
Urinary bladder, **H 20, 21, 22, 23, 24; O 39, 45, 46, 47; S 64, 65, 66, 67; G 84, 85, 86, 87; L 104, 105, 106, 107; Sw 116, 117, 122, 124, 125**  
Urodeum. *See* Cloaca  
Uterine tube(s), **H 21, 23; S 69; G 87; L 105, 107; Sw 125**  
    infundibulum, **H 23; O 47**  
    fimbriae, **S 69**  
Uterus, **H 21, 23; O 39, 45; S 65, 69; G 85; L 105; Sw 123**  
    body, **H 21, 23; O 47; S 67, 69; G 87; L 107; Sw 123, 125**  
    uterine cervix, **H 23; O 47; S 67, 69; G 87; L 107; Sw 125**  
        cervical canal, **H 23**  
        external os, **H 23; O 47**  
    uterine horns (cornua), **H 21, 23; O 47; S 67, 69; G 85, 87; L 107; Sw 123, 125**

**V**

Vagina, **H 21, 23; O 45, 47; S 65, 67, 69; G 85, 87; L 105; Sw 117, 123, 125**  
    proper, **H 23; O 47; S 67; G 87; L 106**  
    vestibule, **H 23; O 47; S 67, 69; G 87; L 106; Sw 125**  
Veins  
    angularis oculi, **O 48; G 77**  
    axillary, **H 26; O 48**  
    azygous, **H 20, 26; O 44, 45, 48; G 84, 85; L 105; Sw 123**

brachial, **H 26; O 48**  
buccal, **H 26**  
caudal auricular, **H 26**  
caudal br. of medial saphenous, **H 26**  
caudal epigastric, **H 26; O 48**  
caudal femoral, **H 26**  
caudal gluteal, **H 26**  
caudal superficial epigastric, **H 26; O 37, 48**  
caudal tibial, **H 26**  
caudal vena cava, **H 20, 21, 26; O 44, 45, 48; S 64, 65; G 84, 85; L 104; Sw 122, 123; C 138, 139**  
cephalic, **H 7, 26; O 37, 48; S 59; G 77**  
circumflex femoral, **O 48**  
collateral ulnar, **H 26; O 48**  
costocervical trunk, **H 26; O 48**  
cranial br. of lateral saphenous, **O 48**  
cranial br. of medial saphenous, **H 26**  
cranial epigastric, **H 26; O 37, 48**  
cranial gluteal, **H 26**  
cranial superficial epigastric, **H 26; O 48**  
cranial tibial, **H 26; O 48**  
cranial vena cava, **H 21, 26; O 44, 45, 48; S 64, 65; G 84, 85; L 104, 105; Sw 122, 123**  
    left, **C 135, 139**  
    right, **C 134, 138**  
deep cervical, **H 26**  
deep circumflex iliac, **H 26; O 48**  
deep facial, **H 26**  
deep femoral, **H 26; O 48**  
digital, **H 26**  
dorsal, **H 26; O 48**  
dorsal common digital III, **H 26; O 46; L 98**  
dorsal nasal, **H 26; O 48; G 77**  
dorsal proper digital, **O 48**  
dorsal scapular, **H 26**  
external iliac, **H 46; O 48**  
external jugular, **H 7, 13, 26; O 37, 48; S 59, 65; G 77, 84, 85**  
external pudendal, **H 26; O 48**  
external thoracic, **H 26; O 48**  
facial, **H 7, 26; O 37; G 77**



hepatic, H 26; O 48  
iliolumbar, H 26  
intercostal, H 26; O 48; Sw 123  
internal iliac, H 26; O 48  
internal jugular, O 48; S 62  
internal thoracic, H 26; O 48  
interosseous, O 48  
jugular, L 95, 101, 104, 105; C 132, 133, 134, 135, 139  
lateral auricular, Sw 114  
lateral palmar, H 26  
lateral plantar, O 48  
lateral sacral, H 26  
lateral saphenous, H 7, 26; O 37, 48; S 59; G 77  
lateral thoracic, H 7; Sw 114  
linguofacial, H 26; G 77  
maxillary, H 26; O 48; S 62; G 77  
medial plantar, H 26; O 48  
medial saphenous, H 26; O 48; S 59; G 77  
median, H 26; O 37, 48  
median sacral, O 48  
milk. *See* Subcutaneous abdominal, O 33, 36, 37;  
G 73, 77  
occipital, H 26; O 48; S 62  
ovarian, H 26  
palmar common digital, O 48  
palmar proper digital, O 48  
pampiniform plexus, O 46; S 66; G 86; L 106  
plantar common digital, O 48  
plantar proper digital, O 48  
popliteal, O 48  
portal, O 48  
prostatic, H 26; O 48  
pudendal epigastric, H 26; O 48  
pulmonary, H 25; O 45; S 65; G 85; L 105; C 138

renal, H 26; O 48  
rostral auricular, H 26  
subclavian, H 26; O 48; S 65; G 85  
subcutaneous abdominal, O 33, 37; G 73, 77  
subscapular, H 26; O 48  
superficial cervical, H 26; O 48  
superficial thoracic, H 26  
testicular, H 22, 26; O 46, 48; S 66; G 86; L 106;  
Sw 124  
thoracodorsal, H 26; O 48  
transverse facial, H 26  
umbilical, H 24  
vertebral, H 26, O 48  
Vent, C 132, 134, 135, 140  
Ventriculus (gizzard), C 134, 135, 136, 138, 139  
Vulva, H 13, 21, 23; O 45, 47; S 65; G 73, 77, 85; L 105;  
Sw 117, 123, 125  
clitoris, H 23; O 47; S 67; L 107  
vulvar labia, H 23; O 47; S 67, 69; G 87; L 107

---

## W

Wattle(s), G 73; C 128, 129  
Wing bar. *See* Feather(s)  
Wing bow. *See* Feather(s)  
Withers, H 2; O 32; S 54; G 72; L 90; Sw 111  
Wrist joint. *See* Joint(s)

---

## X

Xiphoid process. *See* Bone(s), sternum

---

## Z

Zygomatic arch, H 13. *See also* Bone(s)